


# TROPHY

2012  
/  
2013

CONTEST

THE EUROPEAN CONTEST OF CLINICAL  
CASES IN PATHOLOGIES OF THE EYE



## THE CLINICAL CASES

[WWW.THEA-TROPHY.COM](http://WWW.THEA-TROPHY.COM)







**M. Jean-Frederic CHIBRET,**  
President of Laboratoires Théa

Laboratoires Théa is a European pharmaceutical company, based in France and 100% specialized in ophthalmology. Laboratoires Théa has been working closely for almost 20 years with European ophthalmologists. Education has always been a tradition for the Chibret family and for Théa for several generations.

Laboratoires Théa now supports several educational activities, among them the European Board of Ophthalmology. In 2012 Laboratoires Théa started the TROPHY, 'Théa euROpean cOntest of clinical cases in PatHologies of the eYe'. This contest is designed to encourage residents and fellows to play an active role by sharing the findings of their case studies and their day to day experience in ophthalmology.

The TROPHY is an online, yearly contest and is open to European residents. Information on this contest is given through a dedicated website: [www.thea-trophy.com](http://www.thea-trophy.com)

The contest is organized in 2 rounds (national and European). The cases are submitted to a national jury which selects the best presentation for each country. Then, a European jury designates three winners among the best cases from the first round.

The winners are invited by Laboratoires Théa to participate in the ARVO annual meeting in the United States of America and to present their clinical case at Laboratoires Théa's symposium. The subject of 2012's TROPHY was glaucoma.

We look forward to receiving candidate's case studies in English for 2013-2014 dealing with glaucoma and ocular surface.



# PREFACE

Pr CHRISTOPHE  
BAUDOIN





**Pr Christophe BAUDOIN,**  
MD, PhD  
Quinze-Vingts National Ophthalmology  
Hospital  
Vision Institute  
Paris, France

The first edition of the contest of Clinical cases in ophthalmology, called TROPHY, organized by Laboratoires Théa was undoubtedly a success. It is a welcome initiative for several reasons:

- It is a motivation for young ophthalmologists to identify interesting clinical cases and to improve their expertise on uncommon pathologies and their management
- It's a way for residents to get a European audience; more than 15 European countries can participate to this federative competition
- Participation to this contest is easily accessible. Submissions are done online (<http://Théa-trophy.com/>). The cases are appreciated according to their originality, clarity, contribution to knowledge in ophthalmology and illustrations.
- The reward for the 3 final winners is the possibility to attend a research congress in USA and to improve their scientific knowledge
- It is an educational support and an encouragement for residents to improve their communication skills.

After this first edition, TROPHY is meant to continue for several years. The topic of the contest will change every year. A national jury of ophthalmologists will select the best case of the country. These best national cases will be reported in a brochure available on line on the TROPHY website. An international jury of European Experts will have the tough duty to select the 3 winners among the best cases of the participating European countries. These 3 winners will present their cases at the Théa symposium during ARVO congress.

This year, six European countries participated in the contest and it was decided to include in the brochure not only the 6 best cases but all the 25 submitted cases.

The jury was impressed by the high level and also the diversity of the reports illustrated by the pathologies encountered in the 3 best cases; "Subclavian Steal Syndrome and Optic Nerve Damage" for the first one, "Trabectome surgery for secondary traumatic glaucoma in a child" for the second one and "Nonpenetrating deep sclerectomy in glaucoma related to familial transthyretin amyloidosis" for the third one.

I warmly invite the European residents to participate in this contest; the topic for next year is "Glaucoma and Ocular surface" and will include not only clinical cases but also investigations with several cases.  
Long life to TROPHY. Let's make it a success story!

# TROPHY

2012  
CONTEST

THÉA GIVES THE OPPORTUNITY TO THREE EUROPEAN APPLICANTS TO PRESENT AN UNPUBLISHED CLINICAL CASE TO AN INTERNATIONAL AUDIENCE DURING THÉA SYMPOSIUM AT THE ARVO ANNUAL MEETING (USA).

## THE TOPIC OF THE FIRST EDITION OF THE CONTEST WAS GLAUCOMA.



AWARDS

A chance for the three winners of the contest to present their work during Théa symposium organised at annual ARVO meeting (May 5<sup>th</sup> to 9<sup>th</sup>, 2013) with registration fees, round-trip tickets and accommodation costs covered by Laboratoires Théa\*.

The best clinical cases from each participating country will be posted on [www.thea-trophy.com](http://www.thea-trophy.com) and a dedicated brochure edited by Laboratoires Théa will also be published.

## THE TROPHY CONTEST TAKES PLACE IN 2 ROUNDS.



**NATIONAL SELECTION**

A national jury of experts in ophthalmology selects the best clinical case among those submitted by contestants of their country. The jury grades the clinical cases according to the following criteria:

- clarity,
- originality,
- quality of illustrations,
- contribution to ophthalmological knowledge.



**EUROPEAN FINAL**

The best case of each country is submitted to a European jury of experts who designates the three best clinical cases of the contest.

\*Subject to acceptance by regulatory authorities they depend on.

## THE TOPIC OF THE 2<sup>ND</sup> EDITION OF THE CONTEST IS GLAUCOMA AND OCULAR SURFACE.



NOVEMBER 2013  
**NATIONAL  
SELECTION**



DECEMBER 2013  
**EUROPEAN  
FINAL**

### WHO CAN PARTICIPATE?

The contest is open to all residents or fellows in ophthalmology from the following countries:

AUSTRIA, BELGIUM, DENMARK, FINLAND, FRANCE, GERMANY, GREECE, IRELAND, ITALY, LUXEMBURG, THE NETHERLANDS, NORWAY, POLAND, PORTUGAL, SPAIN, SWEDEN, SWITZERLAND, TURKEY, UNITED KINGDOM.

### HOW TO PARTICIPATE?

Submissions can be done on [www.thea-trophy.com](http://www.thea-trophy.com) before October 15<sup>th</sup>, 2013. All submitted clinical cases should be in English and follow the structured format below:

- TITLE
- CASE PRESENTATION WITH ILLUSTRATIONS AND FIGURES
- DISCUSSION
- CONCLUSION

To highlight the interest of the case, the candidate is also invited to provide a short cover letter.

FULL REGISTRATION PROCESS AND RULES ARE AVAILABLE ON  
[www.thea-trophy.com](http://www.thea-trophy.com)

### CONFIDENTIALITY

To ensure an independent and fair vote, contestants will remain anonymous until the end of the contest. A contestant number will be given upon submission of the case. This number will be used through the entire process.

Laboratoires Théa commits itself not to release any information that might help identify the contestants.

The name of the members of the juries will also be kept confidential to the contestants.

### MILESTONES

June 1<sup>st</sup>, 2013 – Submission opening

October 15<sup>th</sup>, 2013 – deadline for cases submission on [www.thea-trophy.com](http://www.thea-trophy.com)

November 2013 – **ROUND 1**: selection of the best national cases

December 2013 – **ROUND 2**: designation of the three best European cases





★  
**TOP 3  
CLINICAL CASES  
TROPHY**  
★  
EDITION 2012



**“SUBCLAVIAN STEAL SYNDROME  
AND OPTIC NERVE DAMAGE”**

P.14

Ricardo AMORIM  
Hospital. Santa Maria, LISBOA – **PORTUGAL**



**“TRABECTOME SURGERY FOR SECONDARY  
TRAUMATIC GLAUCOMA IN A CHILD”**

P.26

Alexandra ANTON  
University Eye Hospital, FRIBOURG – **GERMANY**



**“NONPENETRATING DEEP SCLERECTOMY AS  
AN EFFECTIVE TREATMENT OF GLAUCOMA  
RELATED TO FAMILIAL TRANSTHYRETIN  
AMYLOIDOSIS”**

P.32

Marta LATASIEWICZ  
Hospital. Clinic de Barcelona, Institut Clinic d’Oftalmologia, BARCELONA – **SPAIN**

TROPHY WINNERS AT THÉA ARVO SYMPOSIUM IN SEATTLE ON MAY 7<sup>TH</sup>, 2013.

.....



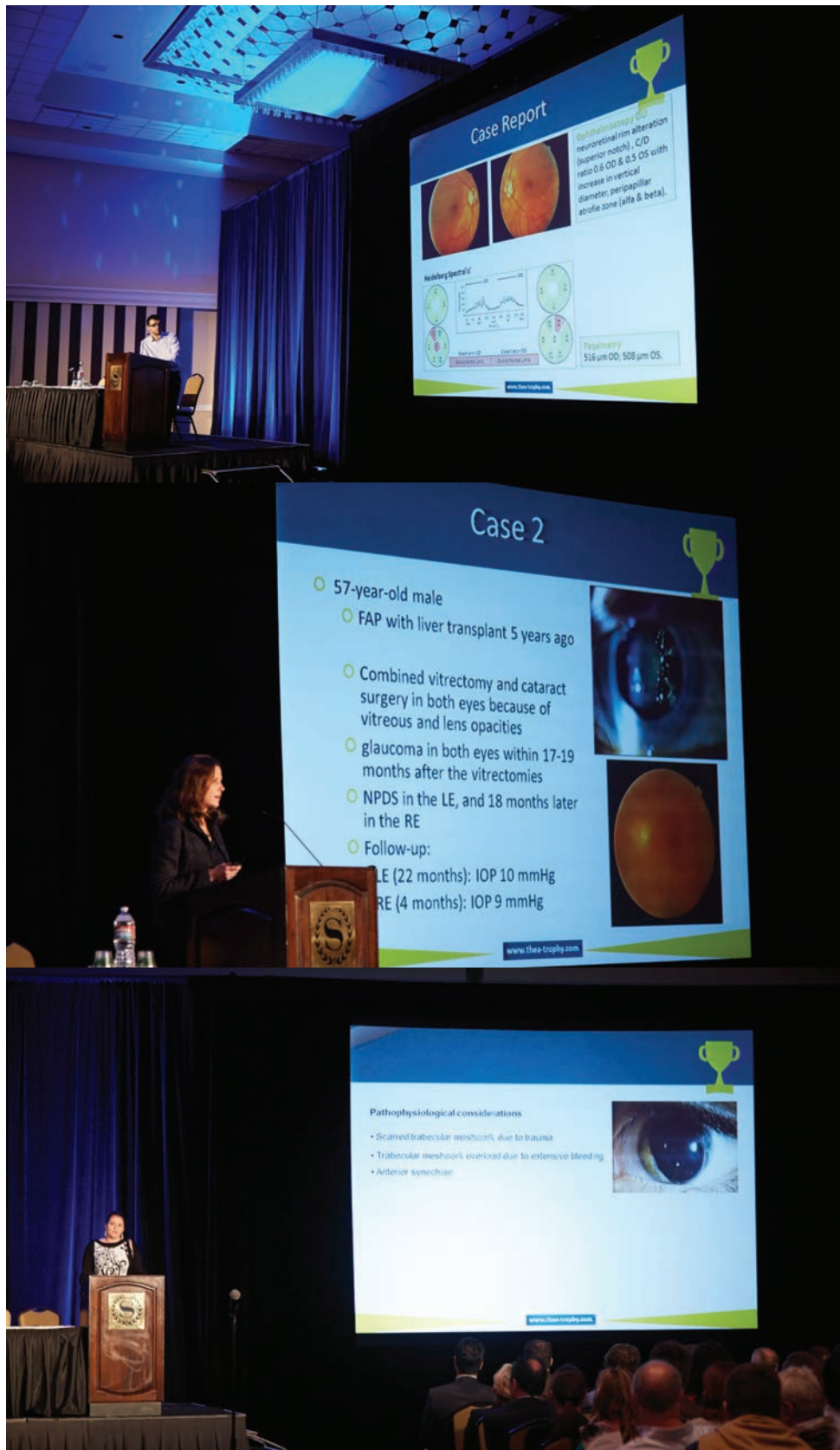
Award Ceremony during Théa ARVO Symposium on May 7<sup>th</sup>, 2013.

From left to right on the photo: Pr Antonio Figueiredo, Mr Jean-Frederic Chibret, Dr Alexandra Anton, Dr Ricardo Amorim, Dr Marta Latasiewicz, and Pr Hans Lemij



TROPHY Winners :

From left to right on the photo: Dr Alexandra Anton, Dr Ricardo Amorim and Dr Marta Latasiewicz



TROPHY winners presenting their clinical case in front of an audience of 300 ophthalmologists coming from all over the world.



.....  
**Ricardo AMORIM**

Hospital Santa Maria, LISBOA – **PORTUGAL**  
.....

### ★ RESUME ★

Ricardo Bastos Amorim, MD was born August 16<sup>th</sup>, 1983 in Santa Maria da Feira, Portugal. He was licensed in medicine from the University of Porto. He is currently a third year resident in Hospital Santa Maria, Lisbon. Participated in thirty-six courses and twenty-seven national and international scientific conferences.

Author and co-author of twenty-nine scientific works, with a national and an international award. He is also a committee member of the Portuguese Society Young Ophthalmologists.



.....

# SUBCLAVIAN STEAL SYNDROME AND OPTIC NERVE DAMAGE

.....

## ★ INTRODUCTION ★

Although Intra Ocular Pressure (IOP) remains a significant factor in glaucoma disease, many cases of glaucoma occur in the absence of high pressure readings during exams. In some cases, vascular factors appear to be particularly important and there is building evidence that systemic vascular dysregulation plays a major role in Normal Tension Glaucoma (NTG)<sup>1-4</sup>. Subclavian steal syndrome is a vascular entity that can potentially decrease perfusion to the optic nerve head, making it more susceptible to damage from intra-ocular pressure, in presence of normal intraocular pressures<sup>5,7,12</sup>. The following case report describes a patient who developed subclavian steal syndrome and optic nerve head hypoperfusion.

## ★ CASE REPORT ★

A 74-years-old white female presented herself for a routine visual evaluation. She has had medical history of hypertension, increased cholesterol, type 2 diabetes mellitus for 5 years and peripheral arterial occlusive disease diagnosed 3 years ago (intermittent claudication of low members). She denied any symptoms of headache, pain or diplopia. There was no history of amaurosis fugax or transient ischemic attacks. She complained about occasional dizziness during mild exertion. She was medicated with simvastatin 20mg id, metformine 1000mg bid, clopidogrel id, enalapril 10mg id and lansoprazol 30mg id.

Her past ocular history revealed a left eye traumatic injury occurred during in her childhood (2-years-old), which resulted in an amblyopic eye. We had no prior registries in our clinic from this patient.

At our exam, the best corrected visual acuities (VA) were 80/100 in the right eye (OD) and 10/100 in the left eye (OS). Pupils were equal, round and reactive to light, without any relative afferent defect. Motility examination showed no limitation, with full ductions and versions presented, without diplopia.

Slit lamp microscopy revealed a clear cornea OD and a 5 mm diameter central corneal opacification OS, there was no evidence of iris neovascularization and the anterior chamber was clear on both eyes (OU). Examination upon pharmacological dilation revealed a bilateral mild nuclear lens sclerosis OU, macula and peripheral retina were healthy in both eyes without evidences of diabetic retinopathy. The optic nerves had a cup-to-disc ratio of 0.60 OD and 0.50 OS, a vertical elongation was detected OU and a superior notch was identified in the right optic nerve (Fig. 1 & 2).

Intra Ocular Pressures by Goldmann applanation tonometry measured 16mm Hg OU. Central corneal thickness was 522  $\mu$ m OD and 506  $\mu$ m OS, measured by ultrasonic pachymetry.

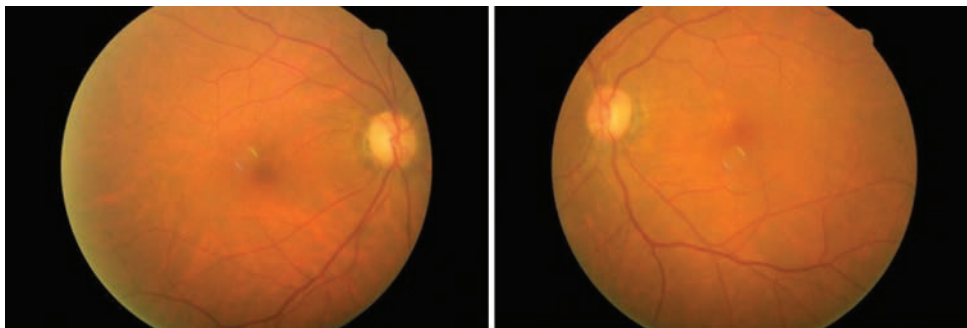


Fig. 1 – Right optic nerve head

Fig. 2 – Left optic nerve head

At this point, we had a patient with a suspected optic discs and a history with vascular risk factors presented.

The patient was instructed to relay her symptoms of dizziness to her primary care physician and to return for an Optical Coherence Tomography – Heidelberg Spectralis® (OCT) and a threshold visual field – 101 OCTOPUS® (both performed 2 weeks later).

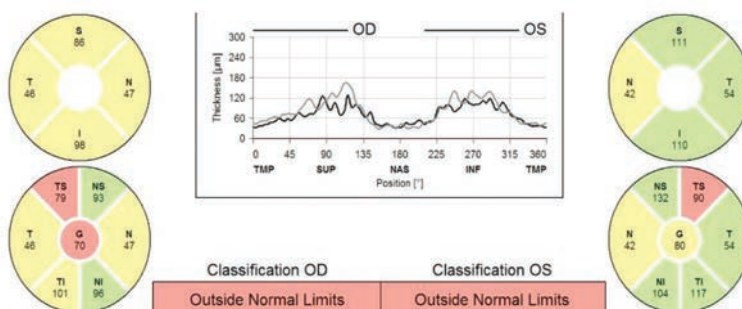


Fig 3 – Optical Coherence Tomography of both eyes.

The OCT revealed a generalized nerve fiber layer loss in OD with a supero-temporal nerve fiber layer thinner than normal and, in OS, a slight decrease on the average nerve fiber layer thickness was noticed (Fig. 3).

The visual field in the left eye was not reliable, because of its amblyopic feature. There were no substantial visual field alterations in the right eye (MD 3.2 / LV 6.7) (Fig. 4a).

She was sent for a carotid and vertebral artery color Doppler ultrasound, which she performed 4 months later. She came back 6 months after her first appointment bearing the prescribed tests. She complained about increased dizziness “when carrying bags from the supermarket”, she also mentioned that she didn’t contact previously her primary care physician, because she related it with her intermittent claudication and as result, didn’t give importance to that. She claimed that she had occasional left arm numbness on exertion.

Doppler evaluation revealed normal flow velocities in the common carotid and internal carotid artery with no evidence of stenosis. However, a retrograde blood flow with high resistance patterns was shown in the left vertebral artery, suggesting left subclavian steal syndrome. The flow in the contralateral vertebral artery was higher (VS = 1.80 m/s; VD = 0.30 m/s).

Another ophthalmologic observation was made and she maintained the VA of 80/100 OD and 10/100 OS. Gonioscopy revealed a moderately open angle (grade III of Shaffer). The optic nerve maintained the same characteristic that was previously observed, with an IOP OD 14mmHg OS 15mmHg. The remaining ophthalmic examination was similar. Blood pressure was 157/90 (right arm) and 131/81 (left arm).

We requested a new visual field exam (Fig 4b) and an Ophthalmic Doppler to evaluate ocular hemodynamics (performed 1 month later). The visual field (good reliability), showed a possible loss of peripheral vision demonstrating delineation of a supero- inferior arcuate scotoma (MD 4.6 / LV 20.5).



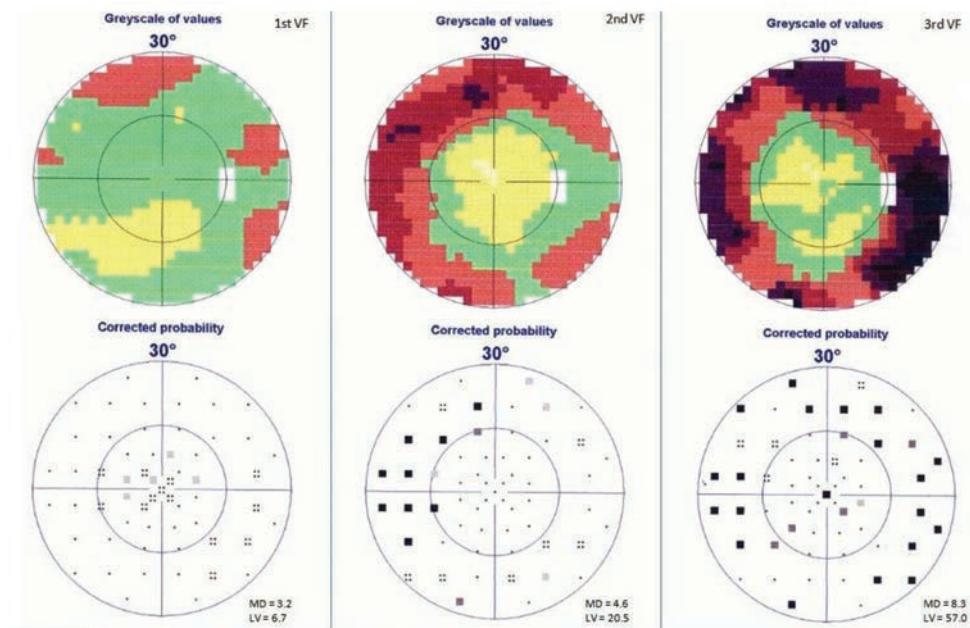


Fig. 4 – a) 1st visual field. b) 2nd visual field performed 6 months later. c) Visual field performed before stent intervention (11 months later).

The Ophthalmic Doppler (Fig. 5), showed an elevated Resistance Index (RI) in both orbits, especially at the microcirculation level, the Peak Systolic velocity (PS) of the right ophthalmic artery was 39.3 cm/s, End Diastolic velocity (ED) 6.8 cm/s, on the left side PS 42.3cm/s and ED 7.6cm/s.

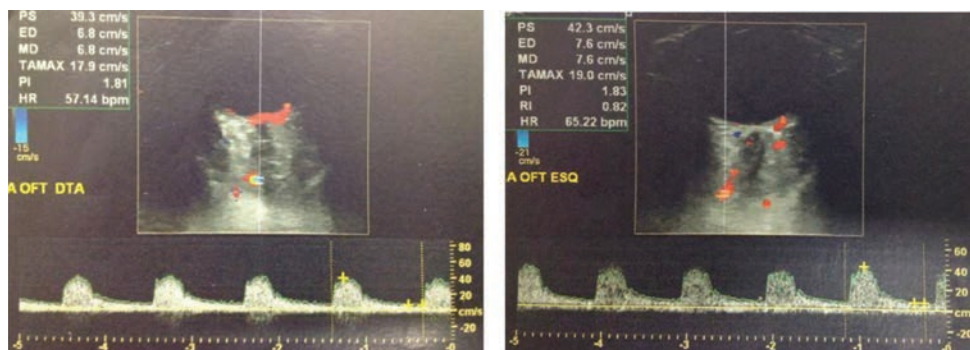


Fig. 5 – Ophthalmic Doppler of the right and left ophthalmic artery (before stent intervention).

We referred this patient to vascular specialist and a CT-Angiography (Fig. 6) was performed, confirming the diagnosis of subclavian steal syndrome and revealing the left subclavian proximal stenosis. She was monitored regularly with regard to neurological signs and symptoms. Vascular Clinics proposed her for endovascular treatment (primary stenting of the subclavian artery). We did a third visual field before surgery (Fig 4c), that confirmed progression in the visual field defects, with a superior and inferior arcuate scotoma with visual fields defects detected closer to fixation (MD 8.3 / LV 57).

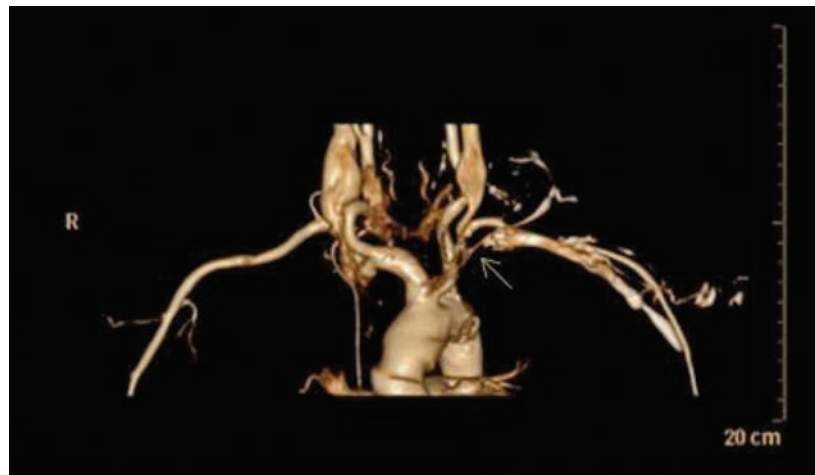

Fig. 6 – CT-Angiography showing the left subclavian proximal stenosis (arrow).

After vascular intervention, the patient did a new Carotid Doppler and Ophthalmic Doppler (Fig. 7) that showed restoration of the blood flood. On the right side the ophthalmic artery showed a PS 54.6cm/s and ED 6.1cm/s. On the left side, was detected PS 69.6cm/s and ED 10.3cm/s.

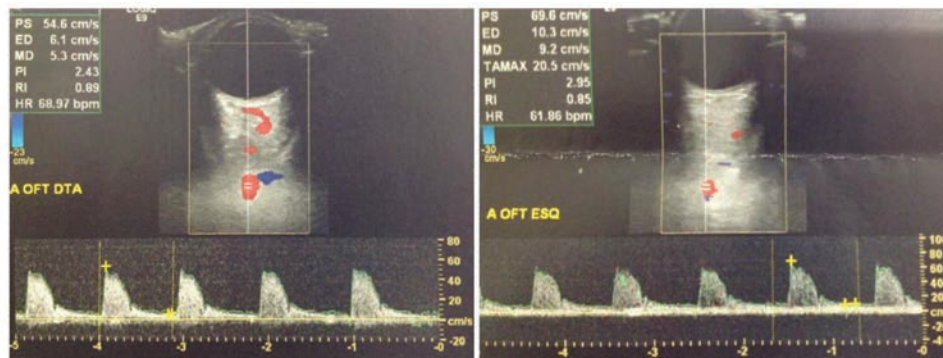


Fig. 7 – Ophthalmic Doppler of the right and left ophthalmic artery (after stent intervention).

A Visual Field exam was performed 3 months after the surgery (Fig. 8) that showed a relative improvement in the visual fields (MD 4.7 / LV 47.0) with a partial recuperation of the scotoma.

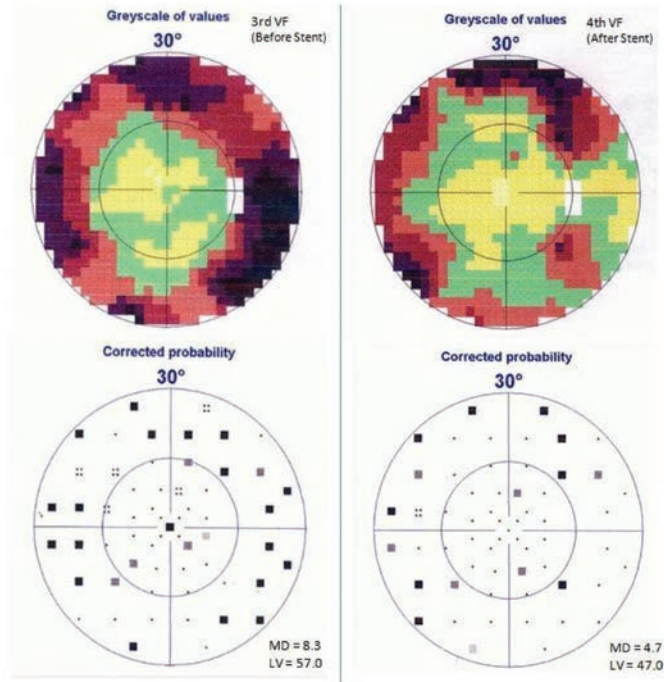


Fig. 8 – Visual fields a) before stent intervention. b) 3 months after stent intervention.

This patient had left subclavian steal syndrome which appears to have caused enough shunting of blood from the right carotid system to the left vertebro-basilar system (and subsequently the left subclavian artery) to decrease ocular perfusion on the right optic nerve head, making it more susceptible to glaucomatous damage, even at a lower IOP. IOPs after surgery were 15mmHg OU and the optic nerves maintained similar characteristics as previously described.

## ★ DISCUSSION ★

### Systemic

Subclavian Steal Phenomenon (SSP) refers to subclavian artery steno-occlusive disease proximal to the origin of the vertebral artery and is associated with reversal flow in the vertebral artery<sup>13</sup>. Anatomically, there is an occlusion of the subclavian artery just before the origin of the vertebral artery.

This clinical entity is associated with neurological symptoms of vertebro-basilar insufficiency that occur during or following exercise of the ipsilateral arm<sup>15, 17</sup>. Symptoms of dizziness or vertigo occur in more than half of the patients, and syncope and dysarthria have been noticed in 18% and 12.5%, respectively. Since most patients do not seek medical advice unless symptoms manifest, the prevalence of subclavian artery occlusive disease and subclavian steal syndrome is unknown<sup>18</sup>.

The most common cause of proximal subclavian artery occlusive lesions is arteriosclerosis. Some of the risk factors are cigarette smoking, hypercholesterolemia, type 2 Diabetes Mellitus, hypertension, and hyperhomocysteinemia. SSP occurs more often on the left side. When the arm is exercised, the blood vessels dilate to enhance perfusion to the ischemic muscle, thus lowering the resistance in the outflow vessels. The increased demand for blood by the left arm, results in the shunting of blood into the left subclavian artery. Blood crosses the basilar artery from the contralateral intracranial vertebral artery and flows retrograde down the ipsilateral vertebral artery towards the left arm (Fig. 9). This bypasses the stenosis in the left subclavian artery. When arm exercise ceases, the resistance in the outflow vessels of the arm increases, thereby reducing retrograde blood flow in the vertebral artery<sup>7, 13, 16, 18</sup>.

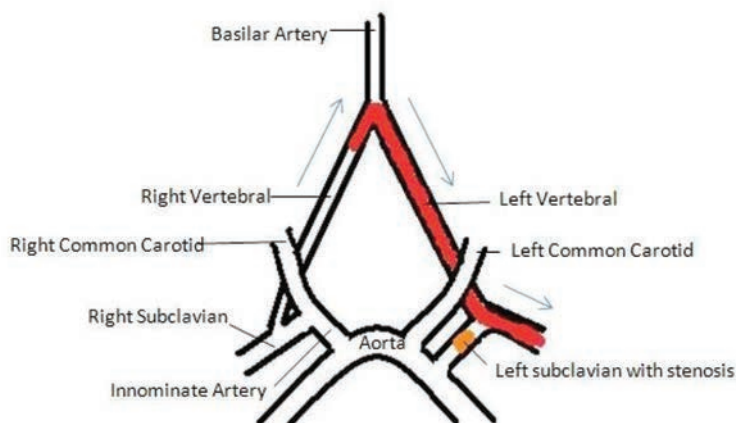


Fig. 9 – Schematic of the path of the blood as it flows to supply the left subclavian artery distal to its occlusion.

If the blood flow demand in the arm increases, more arterial flow is siphoned from the cerebral circulation, satisfying increased oxygen demand through the exercising muscles of the upper extremity. This causes partial ischemia of

the brain stem and posterior cerebral cortex and symptoms could be manifested<sup>14,15</sup>. Indirectly, because of anastomoses between the carotid system and vertebrobasilar system at the circle of Willis, the remainder of the cerebral cortex may be affected during times of heightened activity (Fig. 9 and 10). Numerous symptoms are associated with posterior circulation cerebral ischemia. Visual symptoms secondary to vestibular dysfunction and/or nystagmus include a sensation of objects moving or the inability to focus as well as monocular or binocular visual loss. Diplopia occurs in 19% of the cases. The most frequent neurologic symptom is dizziness or vertigo, usually described as a sensation of lightheadedness, rocking, swaying, or tilting<sup>15,18</sup>. On our examination, there was a blood pressure difference between the arms, usually this difference is at least 20mmHg lower on the involved side in SSP. The pulse is usually weak and the arms and feet may feel cool. Diagnosis is possible through non-invasive testing. SSP most commonly is diagnosed incidentally during carotid and vertebral artery color Doppler US, discovering abnormalities of blood flow direction in the vertebral artery. Angiography remains the definitive diagnostic test for confirming this condition<sup>19</sup>.

Although transient ischemic attacks are common, brain stem infarcts are rare. In general, most vascular surgeons do not perform surgical treatment, unless symptoms related to either cerebral or ipsilateral ischemia are present. No medical therapy is known to effectively treat subclavian steal syndrome. However, if the cause of subclavian steal syndrome is atherosclerotic stenosis or occlusion of the proximal subclavian artery, patients should be treated with lifelong antiplatelet therapy to reduce the risk of associated myocardial infarction, stroke, and other vascular causes of death.

## ► Ocular

Although glaucoma is a progressive degenerative disease, the etiology of this disease is not completely understood, it is quite probable that a combination of factors – mechanical, vascular, and possibly spontaneous nerve fiber atrophy – are involved. Vascular disease could be an underlying factor in determining patients with normal tension glaucoma<sup>1,3,6</sup>.

In this case there was an identified vascular factor disease causing lack of blood supply in the optic nerve, causing suffering of the ganglion nerve cells (probably worst after left arm exercise).

An animal study consisting in clamping the left subclavian artery was performed by Reivich et al 20. They found that there was 41% decrease of total cerebral blood flow. When flow was reversed in the left vertebral artery, there was an increase in flow through both carotid and right vertebral arteries that tried to partly compensate the loss of blood flow down the left vertebral artery. The increase in carotid artery flow occurring when the flow in the vertebrobasilar system is reduced, suggested that the carotid arteries probably contribute to the posterior cerebral circulation through the circle of Willis<sup>7,14,15</sup>(Fig. 10). This shunts blood away from the anterior cerebral and possibly the ocular circulations. It has been demonstrated that when the vertebral arteries were occluded, blood derived from the carotid arteries flowed into the posterior cerebral and basilar arteries<sup>7,15,17</sup>. This may serve to decrease flow toward the ophthalmic artery, establishing hypoperfusion to the optic nerve

head. Many studies suggested that abnormalities in nerve head circulation can contribute to the onset of low tension glaucoma<sup>1,5</sup>. Hypoperfusion, will lead to a more susceptibility optic disc damages in normal values of IOP. The ciliary body will also decrease aqueous production, decreasing even more the IOP.

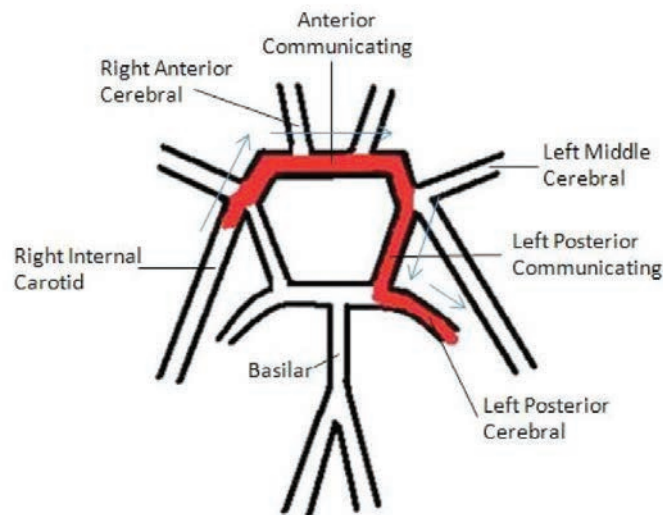


Fig. 10 – Schematic of the circle of Willis. Anastomoses between the carotids and vertebrabasilar systems allow blood to flow from the right internal carotid artery to supply the left posterior cerebral circulation in a case of left subclavian steal syndrome.

In 1997, C. Haskes reported a patient with subclavian steal syndrome (caused by an arteriosclerotic plaque in the left subclavian artery) and contralateral normal tension glaucoma; the patient was treated with warfarin and dorzolamide 2% ophthalmic solution. Several visual fields were performed, before and after the therapy, and revealed defect stabilization after the latter<sup>7</sup>. In our case, the insertion of the subclavian stent restored the vascular flood back near physiologic condition, and as result we had a significant improvement in the visual fields.

The patient had visual fields with good reliability that showed a glaucomatous progression (Fig. 4). It appears that over time, enough blood was shunted away to compensate left subclavian / vertebrabasilar insufficiency, causing hypoperfusion of the optic nerve head. With the institution of the subclavian stent, restoring the normal arterial flow to the optic nerve, an improvement was noticed. In the last visual field performed (after stent intervention), we can notice that some areas recovered visual function (Fig. 8). So, one hypothesis is that the nerve fiber layers of those areas were less time exposed to ischemia, and consequently had time to recover and did not suffer cellular death after vascular intervention<sup>21,22</sup>.

So far, IOP and visual fields remain stable. The patient recovered from his neurological symptoms (dizziness). She is being monitored regularly taking into account neurological signs.

The precise role of vascular factors in normal tension glaucoma is not entirely clear<sup>1-3</sup>, but many believe it represents at least a partial explanation of

the problem in some patients. Currently, more trials in this area are needed to study the effect of ocular blood flow on glaucoma prognosis. Although IOP control is the principal goal in glaucoma therapy, if such studies show a protective effect against Glaucoma, they will open a new era in glaucoma management.

## ★ CONCLUSION ★

The Subclavian Steal Syndrome is a vascular disorder that redirects cerebral blood flow to the subclavian artery affected by obstruction, causing a general reduction in blood flow to territories supplied by the carotid and vertebrbasilar systems. Hypoperfusion to the optic nerve and ciliary body can potentially create normal tension glaucoma. Increasing evidences are showing that vascular factors leading to ischemia, may have a fundamental role in the disease initiation or progression. It is important to recognize the Subclavian Steal Syndrome and its effects on ocular and systemic level, in order to make an early intervention, referral and an adequate follow-up of the disease.

## ★ REFERENCES ★

1. Harris A, The role of optic nerve blood flow in the pathogenesis of glaucoma. *Ophthalmol Clin North Am.* 2005 Sep;18(3):345-53.
2. Plange N, Kaup M, Remkuy A, Arend KO. Prolonged retinal arteriovenous passage time is correlated to ocular perfusion pressure in normal tension glaucoma. *Graefes Arch Clin Exp Ophthalmol.* Aug 2008 ; 246(8) : 1147-52.
3. Chung HS, Harris A, Evans DW, et al. Vascular aspects in the pathophysiology of glaucomatous optic neuropathy. *Surv Ophthalmol* 1999;43:s43-50.
4. Kerr J, Nelson P, O'Brien C. A comparison of ocular blood flow in untreated primary open-angle glaucoma and ocular hypertension. *Am J Ophthalmol* 1998;126:42-51.
5. Harris A, Siesky B, Zarfati D, et al. Relationship of cerebral blood flow and central visual function in primary open-angle glaucoma. *J Glaucoma.* Jan 2007 ; 16(1) : 159-63.
6. Pache M, A Sick Eye in a Sick Body? Systemic Findings in Patients with Primary Open-angle Glaucoma, *Survey of Ophthalmology*, 2006 May ; 51 (3) : 179-212;
7. Haskes C, Glaucoma in a patient with subclavian steal syndrome, *Clinical Eye and Vision Care* 1997 Sep ; 9 (3) : 157-163;
8. Perkins ES. The ocular pulse and intraocular pressure as a screening test for carotid artery, *Br J Ophthalmol.* 1985 Sep ; 69(9) : 676-80.
9. Butt Z, O'Brien C, McKillop G, Aspinall P, Allan P. Color Doppler imaging in untreated high- and normal-pressure glaucoma. *Invest Ophthalmol Vis Sci* 1997;38:690-696.
10. Drance S, Risk Factors for progression of visual field abnormalities in normal-tension glaucoma, *AM J Ophthalmology*, 2001 Jun ; 131 (6) : 699-708.
11. Flammer J. The impact of ocular blood flow in glaucoma, *Prog Retin Eye Res.* 2002 Jul ; 21 (4) : 359-93.
12. Emre M, Ocular Blood flow alteration in glaucoma is related to systemic vascular dysregulation, *Br J Ophthalmol.* 2004 May ; 88 (5) : 662-666.
13. Blakemore WS, Hardesty WH, Bevilacqua JE, Tristan TA. Reversal of blood flow in right vertebral artery accompanying occlusion of the innominate artery. *Ann Surg* 1965 ; 161 : 353-356.
14. Sharma VK, Chuah B, Teoh HL, Chan BP, Sinha AK, Robless PA. Chronic brainstem ischemia in subclavian steal syndrome. *J Clin Neurosci.* Oct 2010;17(10):1339-41.
15. Reivich M, Holling E, Roberts B et al. Reversal of blood flow through the vertebral artery and its effect on cerebral circulation. *N Engl J Med.* Nov 2 1961;265:878-85.
16. Parrot JD. The subclavian steal syndrome. *Arch Surg.* 1969;88:661-5.
17. Webster, M. The effect of arm exercise on regional cerebral blood flow in the subclavian steal syndrome, *AM J Surgery*, 1994 Aug; 168 (2) : 91-3.
18. Labropoulos N, Nandivada P, Bekelis K. Prevalence and impact of the subclavian steal syndrome. *Ann Surg.* Jul 2010 ; 252 (1) : 166-70.
19. Berguer R, Higgins R, Nelson R. Noninvasive diagnosis of reversal of vertebral- artery blood flow. *N Engl J Med.* Jun 12 1980; 302 (24) : 1349-51.
20. Reivich M, Reversal of blood flow through the vertebral artery and its effects on cerebral circulation, *NEJM*, 1961, 265:878
21. Francesca Cordeiro, M. Regeneration evolving steps, *Ophthalmology Times Europe*, March 2011., Vol 7, Issue 2.
22. Francesca Cordeiro, M. Assessment of neuroprotection in the retina with DARC, *Prog Brain Res.* 2008;173:437-50.





.....  
**Alexandra ANTON**

University Eye Hospital, FRIBOURG – **GERMANY**  
.....

★ **RESUME** ★

**2007:** State examination for human medicine,  
University of Freiburg, Germany

**2008:** Doctorate for human medicine, University of Freiburg, Germany

**2007–2012:** Resident, University Eye Hospital Freiburg, Germany

**2012:** Fellow of European Board of Ophthalmology  
Certification as specialist for Ophthalmology,

**Since 2012:** Fellow at the University Eye Hospital Freiburg, Germany



.....

# TRABECTOME SURGERY FOR SECONDARY TRAUMATIC GLAUCOMA IN A CHILD

.....

## ★ INTRODUCTION ★

Traumatic secondary glaucoma due to blunt trauma may occur either as an acute or chronic condition. Two main intraocular mechanisms can lead to this condition. The first is an acute overload of the trabecular meshwork outflow capacity due to intraocular bleeding<sup>(1)</sup>, and the second is posttraumatic scarring within the trabecular meshwork<sup>(2)</sup> leading to functional loss of the physiologic outflow pathway. Certainly, the downstream intrascleral and episcleral outflow structures can also be damaged, but these structures are not yet accessible to therapy.

To prevent posttraumatic changes leading to secondary glaucoma, topical steroids are given to suppress intraocular inflammation<sup>(3)</sup>. In addition, topical or even systemic medical therapy might be necessary to lower intraocular pressure and prevent irreversible optic nerve damage.

If these therapies are not sufficient, surgical options need to be evaluated in the medium term. Filtration surgery (either fistulation or even drainage implants) or cyclodestructive laser surgery are usually the treatments of choice. The former is an invasive incisional surgery with a broad spectrum of possibly serious side effects and increased risk of scarring<sup>(4,5)</sup>, and the latter can lead to a vicious cycle of repeated laser surgeries to control intraocular pressure over the long-term, often with little success<sup>(6,7)</sup>.

## ★ CASE PRESENTATION WITH ILLUSTRATIONS AND FIGURES ★

A 9-year-old Caucasian boy presented with moderately increased intraocular pressure (IOP) after a blunt eyeball trauma with a stone the day before. IOP was 24 mmHg, and he showed a small hyphema. Two days later, his visual acuity was decreased to light perception, and the IOP had increased to 70 mmHg. Because the IOP could not be controlled conservatively, an anterior chamber rinse was performed twice. In the further course of treatment, angle scarring and anterior synechia occurred. The pupil remained mydriatic due to the trauma. IOP fluctuated up to 40 mmHg despite systemic and topical antiglaucomatous therapy. An IOP-lowering surgical procedure was therefore indicated. The pressure profile is shown in Fig. 1. We decided to perform a trabeculotomy with the Trabectome. The scarred trabecular meshwork was removed using an electro-surgical pulse. Postoperatively, pilocarpine was applied to keep the angle clear. However, anterior synechia developed again, and aqueous outflow through the removed trabecular meshwork to Schlemm's canal was blocked (Fig. 2). We therefore performed an iridectomy directly in front of the opened trabecular meshwork to restore aqueous outflow (Figs. 3 and 4). In optical coherence tomography (OCT) of the anterior segment, the opened trabecular meshwork was observed (Figs. 5 and 6). After one year of follow-up, the patient shows normotensive IOP values without the use topical or systemic antiglaucoma therapy.

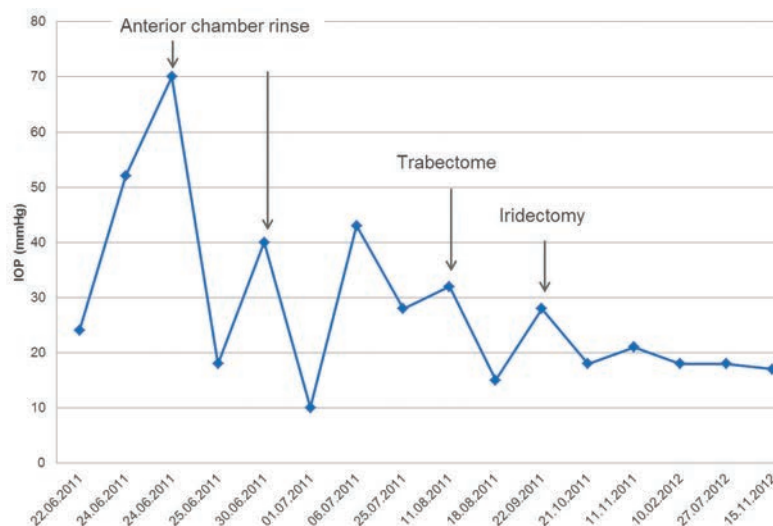


Fig. 1: Pressure Profile of IOP over time, before Trabectome surgery, IOP was only controlled under maximum topical and systemic IOP-lowering medication. Since 10.02.2012 no IOP-lowering medication is used.

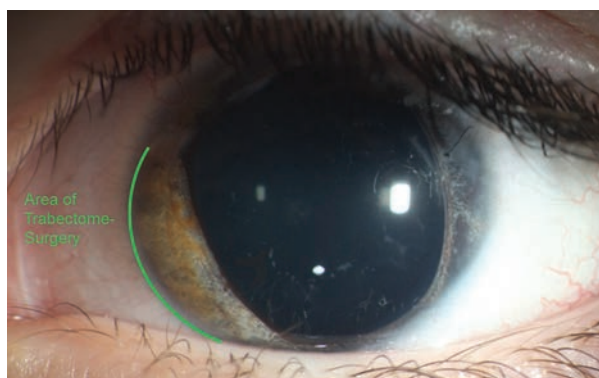


Fig. 2: Slit-Lamp examination of the traumatic mydriasis and anterior synechia in front of the Trabectome gap

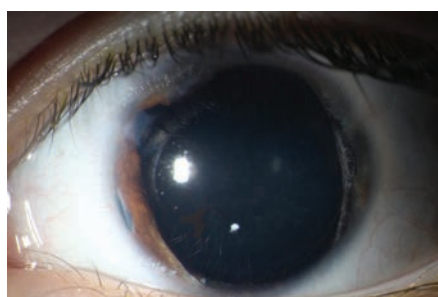


Fig. 3: Slit-Lamp examination of the iridectomy at 8:00 in front of the opened trabecular meshwork

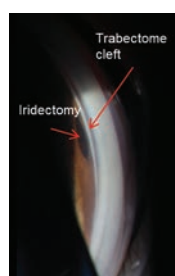

Fig. 4: Gonioscopy examination of the iridectomy in front of the opened trabecular meshwork

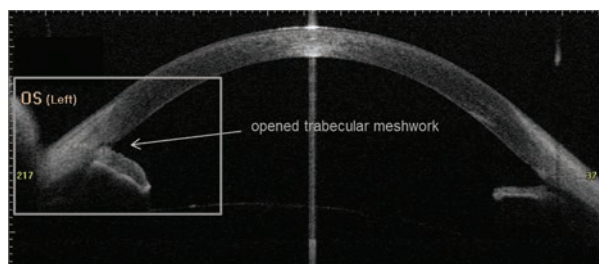


Fig. 5: OCT of the anterior segment of the opened trabecular meshwork

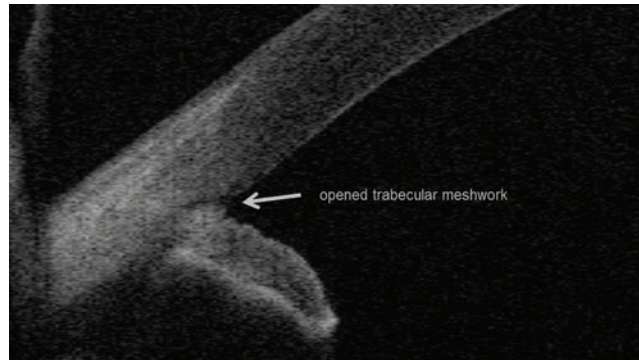


Fig. 6: Enlarged view of the OCT of the anterior segment with the opened trabecular meshwork

## ★ DISCUSSION ★

Traumatic secondary glaucoma is rare in comparison with other forms of glaucoma. Only 1-7% of all eye injuries are contusion injuries<sup>(4)</sup>. Although pathologic alterations and injuries in the anterior chamber occur in 50-80% of all eye injuries<sup>(8)</sup> the prevalence of traumatic glaucoma after blunt trauma is only between 0.5% and 9%<sup>(9)</sup>. However, the patients are often comparatively young. Therefore, effective management of the glaucoma is even more important to prevent late damage in the form of visual field loss or blindness.

We report the case of a young, phakic boy. Trabeculectomy in patients suffering from secondary glaucoma has been described with an increasing failure rate in the literature<sup>(10)</sup>. The young age of the patients, previous surgery and lasting changes in the composition of the aqueous humor are risk factors for severe bleb scarring<sup>(4,11,12)</sup>. The application of additional mitomycin C increases the risk of bleb-related infections<sup>(13)</sup>.

The implantation of a drainage implant in traumatic secondary glaucoma has shown long-term success rates up to 75%<sup>(14)</sup>. However, 97% of the patients in that study became aphakic or pseudophakic from their trauma before or at the time of the Molteno implant insertion. The boy we report on was phakic, so positioning the tube of a drainage implant without touching the lens or corneal endothelium would have been problematic. If we had used combined phakoemulsification and implantation of a drainage system, he would have lost accommodation. Furthermore, young patients have an increased risk of scarring<sup>(5)</sup> after implantation of a drainage device.

Alternatively cyclodestructive methods are possible. However, cyclophotocoagulation has a decreased success rate in traumatic secondary glaucoma compared with other forms of glaucoma<sup>(6,7)</sup>. Moreover, the intervention must be repeated several times to result in successful pressure lowering. However, repeated cyclodestructive interventions increase the risk of postoperative hypotonia after successful implantation of a drainage device.

After blunt eyeball trauma, the secondary glaucoma usually results in scarring of the trabecular meshwork. Therefore, we decided to perform a trabeculectomy using the Trabectome with the idea of removing the scarred trabecular meshwork and thereby restoring the natural outflow pathways.

It was our intention to perform Trabectome surgery early after the trauma, because of our previous experience with limited success in cases where Trabectome surgery was delayed. We postulate that the trauma leads not

only to scarring in the trabecular meshwork itself, but also induces secondary changes in the outflow system behind the trabecular meshwork.

## ★ CONCLUSION ★

Especially in children, surgical options for traumatic secondary glaucoma need special evaluation. Cataract, one of the major complications after incisional surgery, requires an operation to prevent amblyopia and inevitably leads to the loss of accommodation.

Therefore, improving outflow using a minimally invasive surgical approach appears to be the ideal option with a minimized risk profile for the patient. From a pathophysiological understanding of trabecular meshwork scarring, the Trabectome offers a minimally invasive approach to remove the pathologically altered trabecular meshwork. Cataract formation is minimal, and surgical access to the cornea is clear, so if trabeculectomy is insufficient, then fistulation surgery would be possible without prognostic limitations.

## ★ REFERENCES ★

- Walton W, Von Hagen S, Grigorian R, Zarbin M. Management of traumatic hyphema. *Surv Ophthalmol.* August 2002;47(4):297-334.
- WOLFF SM, ZIMMERMAN LE. Chronic secondary glaucoma. Associated with retrolentation of iris root and deepening of the anterior chamber angle secondary to contusion. *Am. J. Ophthalmol.* Oktober 1962;54:547-63.
- Campbell D. Traumatic glaucoma. In: MacCumber MW (Hrsg) Management of ocular injuries and emergencies. Lippincott-Raven Publisher; 1988.
- Mermoud A, Salmon JF, Straker C, Murray AD. Post-traumatic angle recession glaucoma: a risk factor for bleb failure after trabeculectomy. *Br J Ophthalmol.* Oktober 1993;77(10):631-4.
- Mills RP, Reynolds A, Emond MJ, Barlow WE, Leen MM. Long-term survival of Molteno glaucoma drainage devices. *Ophthalmology.* Februar 1996;103(2):299-305.
- Bloom PA, Tsai JC, Sharma K, Miller MH, Rice NS, Hitchings RA, u. a. „Cyclodiode“. Trans-scleral diode laser cyclophotocoagulation in the treatment of advanced refractory glaucoma. *Ophthalmology.* September 1997;104(9):1508-1519; discussion 1519-1520.
- Schlote T, Derse M, Rassmann K, Nicaeus T, Dietz K, Thiel HJ. Efficacy and safety of contact transscleral diode laser cyclophotocoagulation for advanced glaucoma. *J. Glaucoma.* August 2001;10(4):294-301.
- Canavan YM, Archer DB. Anterior segment consequences of blunt ocular injury. *Br J Ophthalmol.* September 1982;66(9):549-55.
- Thiel HJ, Aden G, Pülhorn G. [Changes in the chamber angle following ocular contusions (author's transl)]. *Klin Monbl Augenheilkd.* 1980;177(2):165-73.
- Schlote T, Rohrbach M. [Traumatic glaucoma--a survey]. *Klin Monbl Augenheilkd.* Oktober 2005;222(10):772-82.
- Beauchamp GR, Parks MM. Filtering surgery in children: barriers to success. *Ophthalmology.* Januar 1979;86(1):170-80.
- Landers J, Martin K, Sarkies N, Bourne R, Watson P. A twenty-year follow-up study of trabeculectomy: risk factors and outcomes. *Ophthalmology.* April 2012;119(4):694-702.
- Sidoti PA, Belmonte SJ, Liebmann JM, Ritch R. Trabeculectomy with mitomycin-C in the treatment of pediatric glaucomas. *Ophthalmology.* März 2000;107(3):422-9.
- Fuller JR, Bevin TH, Molteno AC. Long-term follow-up of traumatic glaucoma treated with Molteno implants. *Ophthalmology.* Oktober 2001;108(10):1796-800.



.....  
**Marta LATASIEWICZ**

Hospital Clinic de Barcelona, Institut Clinic  
d'Oftalmologia, Barcelona – **SPAIN**  
.....

**EDUCATION**

Degree in Medicine at the Jagiellonian University College of Medicine,  
Cracow, Poland in 2007

**PROFESSIONAL OPHTHALMOLOGY EXPERIENCE**

Resident in ophthalmology. Hospital Clinic Barcelona, Spain : 2010 - present

**FIELDS OF INTEREST**

Retina, glaucoma, genetics



.....

## NONPENETRATING DEEP SCLERECTOMY AS AN EFFECTIVE TREATMENT OF GLAUCOMA RELATED TO FAMILIAL TRANSTHYRETIN AMYLOIDOSIS

.....

### ★ INTRODUCTION ★

Transthyretin-related familial amyloid polyneuropathy (FAP) is a systemic disease characterized by abnormal production and extracellular deposition of transthyretin (TTR). TTR is a carrier protein of thyroxine in plasma and, in association with the retinol-binding protein, transports vitamin A in the retina. More than 90% of TTR is produced in the liver, but there is evidence of TTR synthesis in the retinal pigment epithelium and the ciliary pigment epithelium<sup>[1]</sup>.

A mutation of the TTR gene located on the 18th chromosome (18q12.1) is responsible for the development of the disease, and is inherited in an autosomal dominant pattern<sup>[2]</sup>. The mutation results in a structural alteration causing misfolding or aggregation of the TTR and its precipitation in tissues. There are over one hundred different types of mutations of the TTR gene described. The most common is the Val30Met substitution, frequently observed in patients of Portuguese and Swedish origins, and the Val122Ile typical for West African and African-American populations<sup>[2]</sup>. The onset, clinical features, and severity of symptoms may vary depending on the mutation.

FAP usually initiates with a sensorimotor peripheral polyneuropathy, and subsequently affects the autonomic nervous system (gastrointestinal dysfunction), cardiovascular system (cardiomyopathy, arrhythmia), central nervous system (seizures, psychosis, dementia), kidneys and eye tissues.

The disease untreated is fatal, and the clinical manifestations are most severe in patients with early onset. The treatment involves liver transplantation (LT), which replaces the main source of the faulty protein, thus preventing further systemic deterioration. The surgery however, does not cease the production of TTR in the ocular tissues and does not eliminate the risk of severe visual impairment of patients with FAP.



Ocular involvement is a common feature of FAP. The risk increases with the duration of the disease and time after liver transplantation<sup>[1,3]</sup>. The increased life expectancy of the transplanted patients allows the amyloid protein to deposit in the ocular tissues with all its consequences, which were not as frequently observed as in the pre-transplant era. Sandgren et al. state that probably all patients will develop a severe ocular disease within 20 years of the onset of the neuropathy<sup>[1]</sup>.

The most common ocular feature observed are vitreous opacities (reported in 12.5% to 80% of patients<sup>[1,3]</sup>) which often decrease visual acuity sufficiently to require a vitrectomy. Pathology exam of the extracted vitreous usually confirms the presence of the amyloid protein. TTR precipitates can be detected by slit-lamp biomicroscopy on the surface of the lens (33% of patients<sup>[1]</sup>), and on the border of the pupillary margin which may be scalloped or irregular (21%<sup>[1]</sup>). The amyloid may precipitate in the trabecular meshwork (TM<sup>[4]</sup>, seen as pigmented deposits. Secondary glaucoma is relatively common and the prevalence which varies between 8% and 50%<sup>[1,3,5,6]</sup> increases with the duration of the disease and time after LT. The pathogenesis of glaucoma in FAP remains unclear, but most authors suggest the trabecular mechanism in which the trabecular meshwork is infiltrated and clogged by amyloid fibrils, similar as in pseudoexfoliative glaucoma in which the pseudoexfoliative material

deposits obstruct the trabeculum<sup>[1,7,8]</sup>. The course of glaucoma in FAP patients is usually accelerated and often requires surgical treatment, of which the trabeculectomy is performed most frequently<sup>[5,9]</sup>. There is only one report published (Kimura et al<sup>[5]</sup>) of a nonpenetrating filtration surgery in FAP-related glaucoma. The patient had an unsatisfactory outcome and poor control of intraocular pressure (IOP), but we have no details on the surgery and other possible risk factors.

Other less frequent ocular features possibly related to FAP include dry eye symptoms and vascular retinopathies (central retinal vein occlusion), but no direct association has been indicated<sup>[1]</sup>.

## ★ CASE REPORT ★

### Case 1

The first patient is a 41-year-old male diagnosed with FAP with peripheral sensorimotor polyneuropathy and renal involvement. He underwent LT 14 years ago. Almost 13 years later his left eye was vitrectomized because of vitreous opacities. Pathology exam confirmed the presence of amyloid (positive Congo red staining) in the extracted vitreous humor. Other ocular findings included iris amyloid deposits with scalloped pupils, and a highly pigmented TM in both eyes. Eleven months after vitrectomy he developed open-angle glaucoma with very high IOP of up to 62mmHg, which did not respond to maximum topical and oral medical treatment. NPDS with Esnoper<sup>®</sup> implant and local mitomycin was performed with a good result. Three months later the patient had a rhegmatogenous retinal detachment in the affected eye, which was treated with vitrectomy, endophotocoagulation and 20% sulfur hexafluoride gas, and presented posteriorly transient IOP elevation. At 6 months after the glaucoma surgery, the patient maintains a good filtering bleb and a normal IOP, currently at 20 mmHg, and does not require additional medical treatment.

The fellow eye contains typical for FAP mild vitreous opacities, but the patient still maintains satisfactory vision and currently does not require antihypertensive therapy.

### Case 2

The second patient is a 57-year-old male with FAP with predominantly neurological manifestations (sensorimotor polyneuropathy, sensorineural hearing loss), autonomic dysfunction (gastrointestinal symptoms), infiltrative cardiomyopathy, and arrhythmia. He had a LT five years ago. Just 1 year after LT the left eye required a combined vitrectomy and cataract surgery because of lens and vitreous opacities. Histological staining of the vitreous was positive for amyloid. Within 19 months the patient developed open-angle glaucoma resistant to medical treatment. NPDS with T-Flux<sup>®</sup> implant and local mitomycin C was successfully performed.

The fellow eye followed a similar clinical course. Three years after LT the patient had a combined vitrectomy and cataract surgery in the right eye, and after 17 months debuted with glaucoma. We opted for a similar treatment as in the left eye and performed a NPDS with Esnoper<sup>®</sup> implant and local mitomycin C.

Currently, 4 months after NPDS in the right eye and 22 months after surgery in the left eye, the patient has functioning filtering blebs in both eyes, maintains low IOP of 7 and 11 mmHg respectively, without signs of progression of the glaucomatous visual field defects.

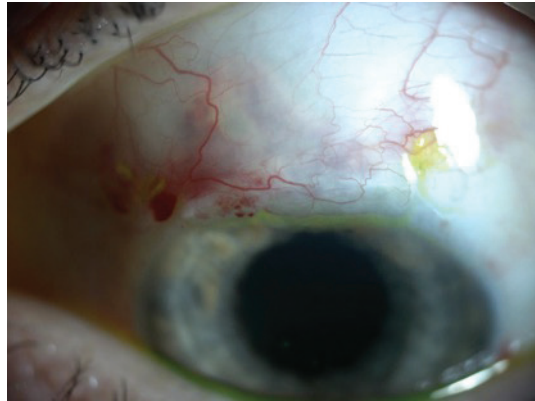

Fig. 1. Patient 1. Filtering bleb (1st postoperative week)

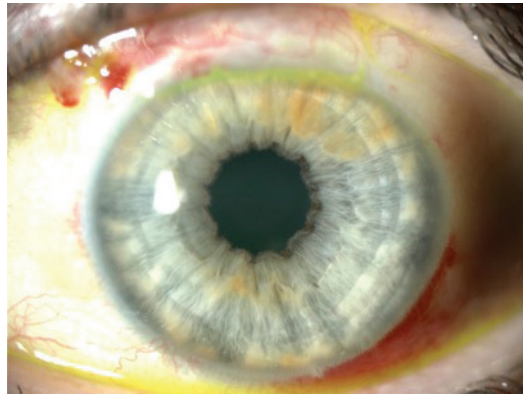


Fig. 2. Patient 1. Scalloped pupil

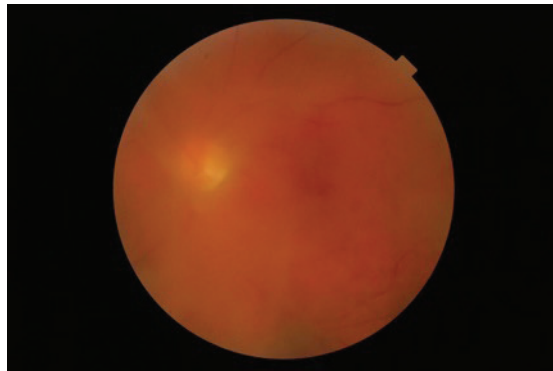


Fig. 3. Patient 2. Vitreous opacities in the left eye.

## ★ DISCUSSION ★

Patients with FAP are at a high risk of developing sight-threatening glaucoma, which increases with the duration of the disease<sup>[1,3,9]</sup>.

We observed a certain pattern in the evolution of ocular disease in our patients: the three operated eyes were primarily affected with significant vitreous opacities and were subsequently vitrectomized. High IOP was detected within 11 to 19 months of the surgery. The untreated eye of the first patient has only mild vitreous opacities, it has not been vitrectomized, and still maintains normal IOP. It seems reasonable to suggest that there is an apparent relation between the severity of the primary FAP ocular feature (vitreous opacities) and the development of glaucoma. Beirao et al<sup>[9]</sup> postulates in a recent report that glaucoma is more common in vitrectomized eyes, with statistical significance, however the mechanism of the relation of the vitrectomy itself with the debut of glaucoma seems unclear, and certainly requires more studies.

There are only a few reports in literature on the types of glaucoma procedures in FAP patients. The most frequently mentioned is the trabeculectomy. Kimura et al reported 15 eyes which required surgery : 11 eyes underwent trabeculectomy, 2 sinusotomy, 1 a cyclodestructive procedure and only 1 a nonpenetrating trabeculectomy. The IOP in the patient with the nonpenetrating trabeculectomy was poorly controlled. However we do not have details on the course of the surgery such as the intraoperative use of antimetabolites and placement of an implant, which could influence the result of the operation.

The progression of glaucoma in our patients was highly accelerated, thus the need of selecting a proper filtration procedure to prevent severe glaucomatous damage. NPDS with implant is a filtration technique successfully performed for more than 20 years. The main advantage of the procedure is that it prevents the sudden hypotony which occurs in the classically performed trabeculectomy, by allowing progressive filtration of the aqueous humour through the trabeculo-Descemet membrane without perforating the eye. Its disadvantage is a longer learning curve, although when performed by an experienced surgeon, it is considered to be just as effective as trabeculectomy in managing primary open-angle glaucoma as well as some forms of secondary glaucoma of trabecular etiology, such as pseudoexfoliative glaucoma. The suggested trabecular mechanism of glaucoma in FAP made our patients good candidates for the procedure, and judging by the results, NPDS was an excellent choice in these cases.

## ★ CONCLUSION ★

As observed in our patients, FAP-related glaucoma is a rapidly progressive disease, which requires prompt and aggressive treatment. The surgical procedure we elected, NPDS, proved to be effective in controlling IOP in all three cases, and seems to be a good option in this type of secondary glaucoma. Therefore it is the first known report of effectiveness of NPDS in amyloidosis-related glaucoma. We are aware that a study on a larger group of patients would be more conclusive. However the results of the three surgeries, considering the advantages of NPDS, are encouraging in controlling the sight-threatening glaucoma and improving quality of life of FAP patients, and may serve as an inspiration of larger and comparative studies.

## ★ REFERENCES ★

1. Sandgren O, Kjellgren D, Suhr OB. Ocular manifestations in Liver transplant recipients with familial amyloid polyneuropathy. *Acta Ophthalmol.* 2008 Aug;86(5):520-4. Epub 2008 Apr 24.
2. McKusick VA, Kniffin CL, editors. 2012 Oct. OMIM, Online Mendelian Inheritance in Man Database [Internet]. John Hopkins University and National Center for Biotechnology information. [cited 2012 Nov 25]. Available from: <http://omim.org/entry/105210>.
3. Hara R, Kawaji T, Ando E, Ohya Y, Ando Y, Tanihara H. Impact of liver transplantation on transthyretin-related ocular amyloidosis in Japanese patients. *Arch Ophthalmol.* 2010 Feb;128(2):206-10.
4. Haraoka K, Ando Y, Ando E, Sandgren O, Hirata A, Nakamura M, Terazaki H, Tajiri T, Tanoue Y, Sun X, Okabe H, Tanihara H. Amyloid deposition in ocular tissues of patients with familial amyloidotic polyneuropathy (FAP). *Amyloid.* 2002 Sep;9(3):183-9.
5. Shi YN, Yang L, Li J, Hu J, Shi R, Sun Y, Zhang CT. Clinical and hereditary features of familial vitreous amyloidosis in chinese. *Yan Ke Xue Bao.* 2011 Mar;26(1):52-5.
6. Kimura A, Ando E, Fukushima M, Koga T, Hirata A, Arimura K, Ando Y, Negi A, Tanihara H. Secondary glaucoma in patients with familial amyloidotic polyneuropathy. *Arch Ophthalmol.* 2003 Mar;121(3):351-6.
7. Nelson GA, Edward DP, Wilensky JT. Ocular amyloidosis and secondary glaucoma. *Ophthalmology.* 1999 Jul;106(7):1363-6.
8. Tsukahara S, Matsuo T. Secondary glaucoma accompanied with primary familial amyloidosis. *Ophthalmologica.* 1977;175(5):250-62.
9. Beirão NM, Matos ME, Meneres MJ, Beirão IM, Costa PP, Torres PA. Vitreous surgery impact in glaucoma development in liver transplanted familial amyloidosis ATTR V30M Portuguese patients. *Amyloid.* 2012 Sep;19(3): 146-51..

# THE OTHER SUBMITTED CLINICAL CASES



## “BILATERAL SPONTANEOUS CORNEAL PERFORATIONS ASSOCIATED WITH OCULAR SURFACE DISEASE AND PRESERVATIVE CONTAINING TOPICAL THERAPY”

P.42

Elizabeth DOLATSHANY HAWKES  
Maidstone Hospital, KENT- UNITED KINGDOM



## “JUVENILE IDIOPATHIC ARTHRITIS : 36 YEAR FOLLOW-UP”

P.48

Florence CHAPUT  
Universitary Hospital Saint-Pierre, BRUSSELS – BELGIUM



## “DIFFICULTIES IN THE TREATMENT OF GLAUCOMA PATIENTS WITH ALLERGIC REACTION FOR ANTIGLAUCOMA EYE DROPS”

P.58

Agnieszka ROMANIAK  
Medical University of Lublin – POLAND



## “OBSTRUCTIVE SLEEP APNEA SYNDROME AND GLAUCOMA : HOW STRONGLY ARE THEY ASSOCIATED ?”

P.64

Mário CANASTRO  
Hospital Santa Maria, LISBOA – PORTUGAL



## “ACUTE TRANSIENT MYOPIA WITH SHALLOWING OF THE ANTERIOR CHAMBER INDUCED BY SULPHAMETHOXAZOLE IN PATIENT WITH PSEUDOXANTHOMA ELASTICUM ?”

P.72

Joana ARAÚJO  
S. João Hospital, PORTO – PORTUGAL



## “ACUTE ANGLE CLOSURE CRISIS AFTER ALBUTAMOL ADMINISTRATION ?”

P.78

Filipe FERREIRA  
Centro Hospitalar e Universitário de Coimbra – PORTUGAL



## “CYP1B1 GENE MUTATIONS IN THREE MEMBERS WITH PRIMARY CONGENITAL GLAUCOMA OF A SPANISH FAMILY : PHENOTYPIC AND FUNCTIONAL VARIABILITY”

P.84

Javier GARCIA BELLA  
Hospital Clínico San Carlos  
(C/ Profesor Martín Lagos S/N, 28040, MADRID) – SPAIN



## “EYES AND DEVICES - A BILATERAL REFRACTORY GLAUCOMA CASE REPORT”

P.90

Claudia BACALHAU  
Centro Hospitalar de Setúbal – PORTUGAL



## “TENON´S CYST TREATMENT BY NEEDLE BLEB REVISION WITH BEVACIZUMAB. EVALUATION OF THE BLEB BY OPTICAL COHERENCE TOMOGRAPHY”

P.94

Raquel LAPUENTE MONJAS  
Hospital Universitario Fuenlabrada,  
Camino del Molino S/N. Fuenlabrada , MADRID – SPAIN



## “AN UNEXPECTED HYPOTONY MACULOPATHY AFTER TRABECULECTOMY”

P.100

Martin VANTOMME  
Cliniques Universitaires St-Luc, UCL, BRUSSELS – BELGIUM



**“TREATMENT DILEMMA IN A PATIENT WITH GLAUCOMA AND RECURRENT SCLERITIS : ENDOSCOPIC CYCLOPHOTOCOAGULATION AS ULTIMATE THERAPY”**

P.108

Marlies WEYNS

Antwerp University Hospital, Wilrijkstraat 10, 2650 EDEGEM – BELGIUM



**“OPTIC NERVE DRUSEN AND GLAUCOMA”**

P.114

Elena JURADO GONZÁLEZ

Hospital de L'Esperança (Parc Salut Mar), Sant Josep de La Muntanya, 12, BARCELONA 08024 – SPAIN



**“CHRONIC IMMUNOLOGICAL DYSREGULATION OF THE OCULAR SURFACE AND ITS CONSEQUENCES IN A PATIENT TREATED FOR PRIMARY OPEN ANGLE GLAUCOMA FOR A LONG TIME”**

P.120

Bielecka ANNA

SPKSO Warsaw Sieczakowskiego 13 – POLAND



**“THERAPEUTIC AND DIAGNOSTIC DIFFICULTIES IN ANGLE-CLOSURE GLAUCOMA, ACCOMPANYING THE CONGENITAL OCULAR MALFORMATIONS”**

P.128

Anna KARASIŃSKA

Department Of Ophthalmology Medical University In Wrocław Borowska Street 213 – POLAND



**“LATE HYPOTONY SECONDARY TO OVERFILTRATING DYSFUNCTIONAL BLEB : CLINICAL FEATURES AND RESULTS OF SURGICAL REPAIR”**

P.136

Agnieszka Anna DYRDA

Parc de Salut Mar, Hospital de La Esperanza, Av. Santuari de Sant Josep de La Muntanya, 12, 08024, BARCELONA – SPAIN



**“NEOVASCULAR GLAUCOMA SECONDARY TO BRANCH RETINAL VEIN OCCLUSION”**

P.144

María Dolores HERNANDEZ MORGADO

Hospital Universitario 12 De Octubre, Avenida De Córdoba S/N, MADRID, C.p. 28041 – SPAIN



**“MALIGNANT GLAUCOMA AFTER DIAGNOSTIC MYDRIASIS IN A PATIENT WITH PSEUDOEXFOLIATION SYNDROME AND CENTRAL RETINAL VEIN OCCLUSION”**

P.150

Alicia MUÑOZ-GALLEGO

"12 de Octubre" Hospital, Avenida de Córdoba s/n 28041 MADRID – SPAIN



**“THE INFLUENCE OF MEIBOMIAN GLAND DYSFUNCTION AND OCULAR SURFACE DISEASE ON INTRAOCULAR PRESSURE CONTROL IN A 83-YEAR PATIENT WITH PRIMARY OPEN ANGLE GLAUCOMA : A CASE REPORT”**

P.156

Piotr KRAWCZYK

Department Of Ophthalmology, Medical University Of Warsaw – POLAND



**“VITAMIN B12 DEFICIENCY OPTIC NEUROPATHY IN A PATIENT WITH PRIMARY OPEN ANGLE GLAUCOMA”**

P.164

Mercedes RIVERA ZORI

Hospital Universitario de Fuenlabrada – SPAIN



**“WHAT CAN THE GLAUCOMA DO !”**

P.172

António MENDES DE CARVALHO

Centro Hospitalar de Coimbra, CHC, Quinta dos Vales, S. Martinho do Bispo, 3041-853 COIMBRA – PORTUGAL



**“NORMAL TENSION GLAUCOMA”**

P.176

Andrea OLEŃIK

Fundación Jiménez Díaz, Avenida Reyes Católicos 2, 28040, MADRID – SPAIN





## BILATERAL SPONTANEOUS CORNEAL PERFORATIONS ASSOCIATED WITH OCULAR SURFACE DISEASE AND PRESERVATIVE CONTAINING TOPICAL THERAPY

### ★ INTRODUCTION ★

Ocular surface disease (OSD) is a common problem in those with glaucoma on topical therapy.<sup>1</sup> Symptoms of OSD are burning and stinging, foreign body sensation, dry eye, tearing and eyelid itching. Signs of OSD include superficial punctate keratitis (SPK), conjunctival hyperaemia, conjunctival follicles and reduced tear film break up time. The ocular surface disease index (OSDI) questionnaire is useful to provide a rapid subjective assessment of OSD severity.<sup>2</sup>

It is estimated that 48% of glaucoma patients on topical medications containing preservatives suffer a degree of ocular surface damage, but this may be an underestimate.<sup>3</sup>

A large proportion of these symptoms could be ascribed to preservatives.<sup>4</sup> We present a unique case of bilateral corneal perforations in a patient on long-term ocular hypotensive medication for open angle glaucoma (OAG). The aim of this report is to raise awareness of severe sight-threatening complications associated with OSD and long term use of glaucoma drops that contain preservative.

## ★ CASE REPORT ★

A 91 year old gentleman with advanced primary OAG presented to the clinic with sudden painless deterioration of vision in both eyes. Up to this time he had been taking g. Lumigan 0.03%/Timolol 0.5% od (OU), g. Dorzolamide 2% bd (OU) and g. Brimonidine 0.2% (OD) with good intra-ocular pressure (IOP) control and vision of 6/9 OD and 6/12 OS. Topical treatment had been started in 1990. Past ocular history included trabeculectomy in both eyes, bilateral pseudophakia and mild age related macular degeneration. There was a history of chronic dry eye, however he did not take treatment for this regularly. Humphrey visual field testing had shown minimal field loss in the right and gradual progression of a superior arcuate defect in the left eye (Figure 1). He was generally well apart from stable systemic hypertension and hypercholesterolaemia for which he took Ramipril and Simvastatin. There was no history of trauma, autoimmune disease or use of immunosuppressant medication.




FIGURE 1: Humphrey 24-2 visual field test - most recent field prior to episode.

On examination, visual acuity was 6/60 OD and hand movements OS. There were bilateral large central corneal perforations with iris plugging (Figure 2) extensive punctate epithelial erosions (PEEs) and superficial punctate keratopathy. Tear film break up time (TBUT) was 4 seconds and Seidel testing was negative. OSD index score was 66/100, indicating severe OSD. Both anterior chambers were formed but shallow and there was no hypopyon. There was no conjunctival xerosis. Corneal sensation was reduced in both eyes. Both blebs were flat and vascularised with no evidence of blebitis. Adnexal examination showed moderate meibomianitis and no lagophthalmos. Posterior segment examination revealed bilateral choroidal effusions (Figure 3). A diagnosis of bilateral corneal perforation with hypotony was made.

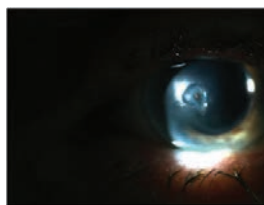


FIGURE 2: Anterior segment photograph of right eye illustrating central corneal perforation with iris plugging.

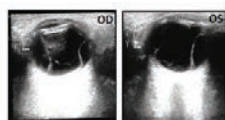


FIGURE 3: B-Scan illustrating bilateral choroidal effusion right and left eye, respectively.

Microbiological swabs returned no growth, inflammatory markers were unremarkable (C-reactive protein 4, ESR 35) and auto-immune screen for rheumatoid arthritis and ANA were negative. All topical medication was discontinued, bandage contact lenses were inserted and he was commenced on a course of preservative free 0.1% Dexamethasone drops four times daily and g. Trehalose 3% (Théaloz) four times daily for his ocular surface.

One month later the corneal perforations had sealed and visual acuities had improved to 6/36 OU. The ocular surface remained poor with extensive punctate staining and central corneal thinning. Plugs were inserted in both upper and lower puncta and preservative free g. Tafluprost (Saflutan) once daily was added to the treatment. Lid hygiene with lid care wipes, Blephaclean, was performed daily and the choroidal effusions resolved. At 1 year follow-up, vision was 6/9 OD and 6/12 OS with a stable, improved corneal surface and intraocular pressures well controlled at 12mmHg right and 11mmHg left (Figure 4). He remained on a regime of Saflutan at night and ThéaloZ drops four times daily with Blephaclean wipes to both eyes. IOP control remained good and the ocular surface became healthier. The OSDI score had improved to 22/100, which reflects mild OSD.

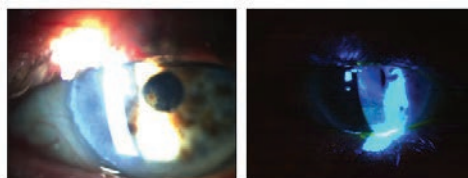


FIGURE 4: Anterior segment photograph of corneas 13 months post-perforation. Left picture: ocular surface using fluorescein dye. Right: Sealed perforation with improved ocular surface (arrow).

## ★ DISCUSSION ★

We believe that this is the first reported case of spontaneous bilateral corneal perforation secondary to chronic preservative exposure on a background of existing ocular surface disease. Remarkably, the patient's condition improved back to baseline after the treatment was changed to include preservative-free drops and dry eye therapy.

The differential diagnosis for corneal perforation includes corneal melt secondary to autoimmune connective tissue disorders, exposure keratopathy, microbial keratitis and prior ocular trauma, although a number of these factors frequently overlap. We excluded all these causes and postulate that the reason for perforation was chronic preservative exposure - from benzalkonium chloride (BAK) containing preparations. Our patient was using the following; (BAK concentration in brackets); Ganfort (0.005%), Dorzolamide(0.0075%), Brimonidine (0.05%). Previously he had applied Latanaprost (0.02%). All this would result in a high cumulative exposure of BAK over 20 years of repeated usage.

The prevalence of both glaucoma and ocular surface disease (OSD) is increasing as the population ages, and when they co-exist, as in our patient, treatment of one can have undesirable effects on the other.<sup>5</sup> Chronic topical IOP-lowering therapy has been associated with OSD. In a study of 630 patients with OAG and ocular hypertension (OHT) an association was demonstrated between increasing mean ocular surface disease index (OSDI) score and the number of IOP-lowering medications used.<sup>3</sup> (Figure 5) There is a large body of evidence to suggest that these effects may be attributable to the preservative BAK.<sup>6</sup>

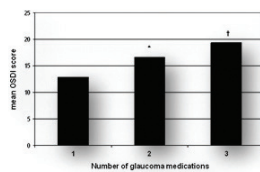


FIGURE 5: Number of topical glaucoma drops compared to OSDI score. \*P = 0.007 versus patients taking 1 medication; †P = 0.0001 versus patients taking 1 medication. (Fechtner RD et al, 2010)<sup>3</sup>

BAK is the most frequently incorporated preservative in commercially available eyedrops, contained in more 70% of existing multidose bottles.<sup>9</sup> It is a quaternary ammonium compound which is employed for its anti-microbial ability and to prevent drug decomposition. The harmful effects of BAK on ocular tissue were first described by Swan et al (1944) when concentrations of 0.04% BAK in contact lens solutions were shown to denature corneal proteins, resulting in punctate erosions and irreversible corneal damage.<sup>10</sup>

Several strands of evidence suggest that BAK is harmful to the cornea. A) Human conjunctival cells show arrested growth at BAK concentrations of 0.0001%, apoptosis at 0.01% and necrosis at 0.05%.<sup>11</sup> B) Liang et al (2012) showed that BAK retarded corneal wound healing, when treated with varying concentrations of latanoprost in human and rat corneal epithelial cells.<sup>12</sup> C) Rabbit corneal epithelium when examined with scanning electron microscopy shows loss of peripheral microvilli and wrinkling of surface cells with visible holes following exposure to BAK.<sup>13</sup> D) BAK induces disruption of epithelial tight barrier function independently of tear production, when stained with Rose-Bengal in the rabbit model.<sup>14</sup> E) BAK may be toxic to corneal neurones. Thus, mouse eyes treated with BAK displayed reduced stromal nerve fibre length in proportion to the applied dose.<sup>15</sup> F) Endothelial tight junctions in rabbit models are disrupted secondary to BAK.<sup>16</sup> Available evidence suggests that BAK has numerous adverse effects on the cornea, although this work is based on non-primate models. Clinically these signs mimic and may exacerbate those of dry eye disease.

Although animal work is suggestive of undesirable effects on the cornea, this does not necessarily translate to human tissue. BAK is very effective at preventing microbial contamination of eye solutions, it is classified as a detergent preservative and acts by destabilising the cell membranes of organisms.<sup>17</sup> Specifically, it helps to enhance penetration of a medication, thus with

the addition of BAK a lower concentration of the drug is needed. A study carried out by Lewis et al (2007) on 700 patients with OAG and OHT comparing the mean IOP in patients treated with Travatan and Travatan without BAK showed no statistically significant difference in IOP.<sup>18</sup> This implies that BAK is not necessary for drug penetration. A similar study showed that preservative free timolol drops are less toxic for the ocular surface.<sup>19</sup>

However, Guenoun et al (2005) found that prostaglandin based glaucoma drops were protective against BAK-induced toxicity in corneal and conjunctival cells, and suggested that this may have related to their antioxidant properties.<sup>20</sup> Importantly, it has been demonstrated that the early ocular effects of preservatives can be reversed after withdrawal.<sup>21</sup>

Overall the evidence from human, animal and in vitro research provides strong evidence in favour of preservative free eye drops and confirms that they are less damaging to the ocular surface.

## ★ CONCLUSION ★

We report a potentially devastating complication that we suspect was connected to longstanding BAK-preservative use in a patient with OSD. We wish to emphasise the importance of early recognition and treatment of OSD in people receiving topical glaucoma medications, especially those containing BAK. It is recognized that glaucoma and ocular surface disease often co-exist, particularly in the elderly. Both conditions should be treated simultaneously. We advocate the use of preservative free topical glaucoma treatment for those patients with co-existing OSD.

## ★ REFERENCES ★

1. Tsai JH, Derby E, Holland EJ, Khatana AK. Incidence and prevalence of glaucoma in severe ocular surface disease. *Cornea*. 2006 Jun;25(5):530-2.
2. Walt JG, Rowe MM, Stern KL. Evaluating the functional impact of dry eye: the ocular surface disease index. *Drug Inf J*. 1997;31:1436.
3. Fechtner RD, Godfrey DG, Budenz D, Stewart JA, Stewart WC, Jasek MC. Prevalence of ocular surface complaints in patients with glaucoma using topical intraocular pressure-lowering medications. *Cornea*. 2010 Jun;29(6):618-21.
4. Pisella PJ, Pouliquen P, Baudouin C. Prevalence of ocular symptoms and signs with preserved and preservative free glaucoma medication. *Br J Ophthalmol*. 2002;86:418-423.
5. Friedman DS, Wolfs RC, O'Colmain BJ, et al. Prevalence of open-angle glaucoma among adults in the United States. *Arch Ophthalmol*. 2004;122: 532-538.
6. Baudouin C. Side effects of antiglaucomatous drugs on the ocular surface. *Curr Opin Ophthalmol*. 1996;7:80-86.
7. Leung EW, Medeiros FA, Weinreb RN. Prevalence of ocular surface disease in glaucoma patients. *J Glaucoma*. 2008;17:350-355.
8. Furrer P, Mayer JM, Gurny R. Ocular tolerance of preservatives and alternatives. *Eur J Pharm Biopharm*. 2002;53:263-280.
9. Freeman PD, Kahook MY. Preservatives in topical ophthalmic medications: historical and clinical perspectives. *Expert Rev Ophthalmol*. 2009;4:59-64.
10. Swan KC. Reactivity of the Ocular Tissues to Wetting Agents. *Am. J. Ophthalmol*. 1944:27-118.
11. De Saint Jean M, Brignole F, Bringuier AF, Bauchet A, Feltmann G, Baudouin C. Effects of BAK on growth and survival of Chang conjunctival cells. *Invest Ophthalmol Vis Sci* 1999; 40:619-30.
12. Liang H, Baudouin C, Dault P, Garrigue JS, Buggage R, Brignole-Baudouin F. In Vitro and In Vivo Evaluation of a Preservative-Free Cationic Emulsion of Latanoprost in Corneal Wound Healing Models. *Cornea*. 2012 Nov;31(11):1319-1329.
13. Cha SH, Lee JS, Oum BS, Kim CD. Corneal epithelial cellular dysfunction from benzalkonium chloride (BAC) in vitro. *Clin Experiment Ophthalmol* 2004;32:180-4.
14. Chen W, Hu J, Zhang Z, Chen L, Xie H, Dong N, Chen Y, Liu Z. Localization and expression of zonula occludens-1 in the rabbit corneal epithelium following exposure to benzalkonium chloride. *PLoS One*. 2012;7(7):e40893. Epub 2012 Jul 18.
15. Sarkar et al. Corneal neurotoxicity due to topical benzalkonium chloride. *Invest Ophthalmol Vis Sci*. 2012 Apr 6;53(4):1792-802.
16. Chen et al. Corneal alterations induced by topical application of benzalkonium chloride in rabbit. *PLoS One*. 2011;6(10):e26103. Epub 2011 Oct 12.
17. Noecker R. Effects of common ophthalmic preservatives on ocular health. *Adv Ther*. 2001 Sep-Oct;18(5):205-15.
18. Lewis RA, Katz GJ, Weiss MJ, Landry TA, Dickerson JE, James JE, Hua SY, Sullivan EK, Montgomery DB, Wells DT, Bergamini MV. Travoprost 0.004% with and without benzalkonium chloride: a comparison of safety and efficacy. *J Glaucoma*. 2007 Jan;16(1):98-103.
19. De Jong C, Solwijk T, Kuppens E, et al. Topical timolol with and without benzalkonium chloride; epithelial permeability and autofluorescence of the cornea in glaucoma. *Arch Clin Exp Ophthalmol* 1994;232:221-4.
20. Guenoun JM, Baudouin C, Rat P, Pauly A, Waznet JM, Brignole-Baudouin F. In vitro comparison of cytoprotective and antioxidative effects of latanoprost, travoprost, and bimatoprost on conjunctiva-derived epithelial cells. *Invest Ophthalmol Vis Sci*. 2005 Dec;46(12):4594-9.
21. Gordon J, Johnson PJ. Fibronectin Study Group-discontinuation of topical ophthalmic medications promotes healing of non-healing corneal epithelial defects. *Invest Ophthalmol Vis Sci* 1991;32:1071.

Florence CHAPUT

Universitary Hospital Saint-Pierre, BRUSSELS – BELGIUM



## JUVENILE IDIOPATHIC ARTHRITIS : 36 YEAR FOLLOW-UP

### ★ INTRODUCTION ★

Juvenile idiopathic arthritis (JIA) is defined by the American Rheumatism Association (ARA) as the presence of arthritis (chronic, seronegative, and peripheral) with no apparent cause which last more than 6 weeks and with disease onset prior to 16 years old. JIA classification is based on predominant clinical manifestations and laboratory features, categorizing patients as oligoarticular (formerly pauciarticular, four or less joints involved), polyarticular (five or more joints involved) and systemic onset JIA. Chronic iridocyclitis is most common in extend oligoarticular JIA and occurs in 10-20% of all patients and is typically asymptomatic either because of the preverbal age of children or the insidious nature of the disease. There is a progressive morbidity with 30-40% of patients with severe loss of vision as leading to possible blindness. Retrospective series have reported that 28-67% of patients with JIA associated uveitis develop ocular complications including cataract, band keratopathy and glaucoma. Glaucoma is a common complication with an incidence which ranges from 14% to 33% and increases with the duration of the disease<sup>[1,9,11,21]</sup> We describe 36 year follow up of a 2.5-year-old Caucasian boy with JIA who developed uveitis, complicated by cataract, band keratopathy and unilateral refractory glaucoma.

## ★ CASE REPORT ★

A 2.5-year-old Caucasian boy was referred to our clinic in 1975 with an oligoarticular JIA. Patient was positive for antinuclear antibody (ANA) and was treated with oral steroids. On examination, uncorrected visual acuity (VA) was 1.0 in both eyes. Biomicroscopy revealed a first episode of bilateral non granulomatous anterior uveitis. In March 1980, the visual acuity was still 1.0 without correction in both eyes. On slit-lamp examination, bilateral band keratopathy with 3+ cells in the anterior chamber and posterior synechiae were noted. A treatment with topical steroids and atropine was started in addition to systemic steroids. Inflammation responded poorly and became chronic. Aqueous cells decreased but posterior synechiae and band keratopathy persisted. Nine months later, inflammation has been controlled and oral steroids have been stopped. In March 1981, corrected VA of the right eye (RE) deteriorated to 0.6, while VA of the left eye (LE) remained good. Moderate anterior inflammation was present but intraocular pressure and posterior segment were normal. The patient developed cataract in the RE. The progression of cataract reduced the VA of the RE to 0.2. In February 1983, cataract surgery of the RE was performed without intraocular lens (IOL) implantation. An optic correction of the RE with contact lens allowed the vision to increase to 1.0. The vision of the LE was still 1.0. Ocular examination demonstrated persistent moderate anterior bilateral uveitis. Cataract developed in the LE later and was operated without IOL implantation in June 1991. Vision and inflammation remained stable until June 1999, where the patient presented an episode of acute raised of intraocular pressure to 50 mmHg in the RE (patient was 26 years old at this time). The gonioscopy was not described. A treatment with betaxolol 0.5%, brimonidine 0.2% and oral acetazolamide was initiated. Despite maximal medical therapy, intraocular pressure remained high at 30 mmHg. A diode laser cycloablation was performed on the RE on February 2000 with no success. In March 2000, the option for surgical treatment with a glaucoma drainage device was brought up. A 350 mm<sup>2</sup> Baerveldt filtering device implantation at the superotemporal quadrant of the RE proceeded routinely without any complications. This intervention resulted in prompt decrease of the IOP around 5 mmHg. IOP of the RE remained between 6 and 14 mmHg. In December 2000, a secondary implantation of intraocular lenses (IOL) was performed bilaterally to improve the vision. His VA was 1.0 in both eyes. In April 2001, the VA of the RE dropped to 0.1. Biomicroscopic examination did not show any anterior inflammation. IOP of the RE and LE were respectively 6 and 8 mmHg. Fundus examination revealed a macular cystoid edema (CME) in the RE. Indomethacin was added to topical steroids. CME did not respond to topical non steroidal anti-inflammatory. Visual field showed superior and inferior arcuate defects and was normal in the LE (figure 4). In January 2002, VA remained 0.1 in the RE and 1.0 in the LE. Oral acetazolamide was started. CME decreased and the visual acuity improved to 0.5 in the RE. IOP was 6 mmHg in the RE and 13 mmHg in the LE. CME became chronic in the RE and the treatment with indomethacin and steroids was continued. Intravitreal injection of triamcinolone was performed in the RE to decrease macular thickness. Steroids injection did not increase IOP. Unfortunately, in September 2003, the Baerveldt implant was dislocated. In October 2003, it had to be



removed. Postoperatively, the intraocular pressure in his RE increased again but did not respond well to the addition of dorzolamide 2% and timolol 0.5%. An Ex-press shunt was placed subconjunctivally in March 2004. One day postoperatively, IOP was 10 mmHg in the RE. Biomicroscopic examination revealed a deep anterior chamber and a thin-walled drainage bleb. Two weeks postoperatively, IOP increased again to 35 mmHg. Topical medical treatment with the association of dorzolamide 2% and timolol 0.5% was started again. Brimonidine 0.2% was added but IOP remained high. A needling of the drainage bleb was performed unsuccessfully. In view of the failed Express shunt placement, a diode laser cycloablation was performed for the second time in the RE in September 2004. One week postoperatively, IOP was still 34 mmHg. Gonioscopy showed closed angle on nearly 360°. The VA was 0.2 in the RE and 1.0 in the LE. Because IOP remained uncontrollable in the RE, surgery was required again. On March 2005, a 350 mm<sup>2</sup> Baerveldt device implantation was placed at the superonasal quadrant of the RE. One day postoperatively, IOP decreased to 5 mmHg. One week later, a two millimeter hyphema occurred. The anterior chamber was deep. The implant was free of hyphema but a corneal touch was noted. The fundus was not visible. A B-scan ultrasonography detected a suprachoroidal hemorrhage. Hyphema resorbed after two months. The Baerveldt tube seemed to be too long and then touched the corneal endothelium. Examination of the posterior segment was difficult due to significant media opacity but the retina appeared attached. RE vision had deteriorated to hand movements. IOP was around 10 in RE and 16 in the LE. In April 2006, a corneal edema of the RE was noted with a consequent decrease of VA to hand motion. A treatment with topical dimeticone (ophtasiloxane®) could not control the corneal edema. In November 2007, a penetrating keratoplasty in conjunction with repositioning of the tube was performed without any complications (figure 1). Corrected visual acuity of the RE improved to counting fingers. A treatment with rimexolone was continued. Three months later, IOP of the RE increased to 26 mmHg. A medical treatment was started again, firstly with the association of dorzolamide 2% and timolol 0.5%. Brimonidine 0.2% was secondly added. IOP of the RE fluctuated in a range of 14 and 23 mmHg. At the same time, the patient complained about diplopia. An orthoptic examination revealed an esotropia of the RE. In February 2009, an edema developed in the temporal part of the corneal graft. Intensive topical steroid therapy was started in addition to brimonidine 0.2%, timolol 0.5%, brinzolamide 1% and oral acetazolamide. The visual field remained normal in the LE and was markedly altered in the RE. The total deviation pattern indicated generalized depression (figure 5). In October 2009, a clear epithelial ingrowth was observed. A stripping of the epithelial membrane had to be done to remove the membrane from the endothelial and iris surface. Chronic edema of corneal graft in the RE persisted (figure 2). In February 2010, the patient was operated for strabismus. A recession of the medial rectus muscle was performed in the RE routinely without any complications. New epithelial membrane developed and removed by surgery. In January 2011, a corneal graft rejection was noted. At the last examination in November 2012, the VA was hands movements in the RE and 1.0 in the LE. Biomicroscopy showed a generalized edema of the corneal graft with active vascularization and a narrow anterior chamber in the RE and remained unchanged in the LE. IOP was 16 mmHg in the RE and 8 mmHg in the LE (figure 3).

## ★ DISCUSSION ★

This case represents several interesting points.

At first, it describes an adult onset unilateral glaucoma complicated JIA. The patient was 26 years old when he developed an episode of acute raised IOP, which is 24 years after the diagnosis of uveitis. At this time, inflammation was controlled in both eyes and he did not take any topical or systemic steroids. In contrast, IOP and visual field of the LE remained strictly normal during the 26 years of follow-up. Incidence of glaucoma in JIA is described between 14% and 33% and increases with duration of the disease.<sup>[1,9,11,21]</sup> It is more frequently caused by progressive closure of the angle by peripheral anterior synechiae. Secondary glaucoma is one of the most common causes of blindness in children and adults with chronic uveitis. Uveitic glaucoma is mainly caused by anterior and intermediary uveitis, in particular when inflammation is chronic. Panek et al. showed that 26% of the eyes with chronic uveitis developed secondary glaucoma, compared with only 12% of the eyes with acute uveitis<sup>[17]</sup> The elevation of IOP may be oscillating, transient and innocuous or persistent and severely damaging. In the other hand, exacerbation of the uveitis may cause shutdown of the ciliary body and lead to hypotony, thus masking the underlying glaucoma. Several mechanisms are involved in the pathophysiology of uveitic glaucoma. The milieu of inflammatory cells, the mediators they release, and the corticosteroid therapy used to treat the uveitis can participate in the pathogenesis of uveitic glaucoma. Those factors alter the normal anatomic structure of the anterior chamber and angle, influencing aqueous production and outflow. These changes act to disrupt the homeostatic mechanisms of intraocular pressure control. Structural changes in the angle can be acute, such as in secondary angle closure with pupillary block glaucoma, or chronic, such as combined steroid-induced and secondary open angle glaucoma.<sup>[14]</sup> In an observational series of 104 patients with JIA-associated uveitis, fourteen (13.5%) had developed ocular hypertension or secondary glaucoma<sup>[11]</sup> In contrary to our patient, all of them had active uveitis. None were corticosteroid responder. However, Sijssens et al. 20 shows that implantation of an IOL in the eyes of children with JIA-associated uveitis was not associated with an increased risk of ocular hypertension or secondary glaucoma. The management of uveitic glaucoma requires a careful balance between adequate anti-inflammatory therapy and intraocular pressure-lowering to prevent long term visual loss.<sup>[23]</sup> Secondary glaucoma in patients with JIA is poor.<sup>[9]</sup> Complications and visual loss reduce currently by the use of immunosuppressive drugs.<sup>[6]</sup>

Secondly, the length of the follow up is very long. Different surgical procedures have been tried because of failure of controlling IOP. Indeed, there is no consensus regarding the best surgical approach for managing inflammatory glaucoma. Trabeculectomy has been the most widely performed filtering surgery. Success rates of trabeculectomy with adjunctive antiscarring agents in patients with uveitic glaucoma range around 71% at 3 years<sup>[7,19]</sup> and between 57% and 76.5% at 5 years.<sup>[3,8,24]</sup> Surgery failure increases with duration of the follow up. Most frequent early postoperative complications are choroidal

effusion, flat anterior chamber, wound leak, hyphema and suprachoroidal hemorrhage, while late postoperative complications include corneal edema, encapsulated bleb, bleb leak, hypotensive maculopathy, endophthalmitis/blebitis and choroidal effusion.<sup>[22]</sup>

Non penetrating deep sclerectomy is a therapeutic option for inflammatory glaucoma when there is no anterior synechiae or narrow angle. However, it is less frequently performed and it requires experience of the surgeon. Dupas and colleagues<sup>[5]</sup> showed that success rate at 12 months of deep sclerectomy and trabeculectomy with antiproliferative agents in both cases were respectively 89% and 88%. Hypotony and choroidal effusion are less frequent in comparison with trabeculectomy.

Furthermore, different studies reported the effectiveness and the safety of glaucoma drainage device (GDD) the management of uveitic glaucoma. TVT study<sup>[22]</sup> is a large multicenter randomized clinical trial comparing trabeculectomy with MMC and GDD that prospectively enrolled 212 patients with medically uncontrolled glaucoma. At 5 years, both procedures were associated with similar IOP reduction and use of supplemental medical therapy. However, cumulative failure rate was 29.8% in the tube group (Baerveldt glaucoma implant) and 46.9% in the trabeculectomy group. The rate of reoperation was higher in the trabeculectomy group (9% versus 29%). Consequences of GDD mainly include persistent corneal edema, persistent diplopia, cystoid macular edema, tube obstruction, recurrent iritis, choroidal effusion and encapsulated bleb.<sup>[2,22]</sup> While uveitic glaucoma were excluded in the TVT study, several studies tested different types of GDD (Baerveldt, Molteno and Ahmed implants) in the management of uveitic glaucoma. Success rates ranged between 39% and 94%; these results varying depending on the length of the follow up (between one and ten years).<sup>[2,13,16,18,25,26]</sup> Valimaki and colleagues<sup>[25]</sup> reported 90% success (IOP  $\leq$  22 mmHg) with Molteno device after 52 months of follow-up in 27 eyes of 19 patients with secondary glaucoma caused by JIA. Finally, laser cyclophotocoagulation procedures have historically been considered at last resort because of the high rate of complications, including reduced visual acuity, uveitis, pain, haemorrhage, phtisis bulbi. Murphy et al. demonstrated that cyclodiode therapy is highly effective in patients with refractory glaucoma but have a significant risk of hypotony, in particular in uveitic eyes (19%).<sup>[15]</sup> The dose-response association remains unpredictable. In another study comparing cyclodiode laser and tube surgery, Malik and colleagues<sup>[12]</sup> found that the possible benefits of IOP control in patients undergoing diode cyclophotocoagulation needed to be weighed against the risks of long-term visual loss and the need for multiple re-treatments.

Concerning our patient, a diode laser cycloablation was the first surgical option. At this time, this technique was tried for a series of patients because it is less invasive and easier to perform. Unfortunately, it failed. Indeed, re-treatments are often needed. Then a 350 mm<sup>2</sup> Baerveldt drainage device implantation has been placed in our patient with success. It was placed instead of trabeculectomy because of high risk of failure of the filtering surgery. Uveitic glaucoma has an increased risk of failure to control IOP, especially when inflammation is active at the time of surgery. There was scar tissue

in the conjunctive because of his previous surgeries. The patient was young. Chawla reported that patients under 30 years of age at surgery seem to be at a higher risk for bleb failure.<sup>[3]</sup> Baerveldt implant permitted to control IOP during 3.5 years. Unfortunately he developed a late complication consisting in tube erosion requiring a reoperation to remove it. An Ex-press valve was tried later but did not succeed. Originally designed to be placed subconjunctivally, common complications of excessive hypotony, tube dislocation or erosion have largely led to the abandonment of this rapid surgical approach.<sup>[4,27]</sup> A newer model has been designed to function under a standard trabeculectomy scleral flap. It has yet to be prospectively established. A cyclodiode laser was tried again because of the low vision and multiple previous surgeries. At last, a second implantation of Baerveldt filtering device was performed in spite of the high risk of failure. In the early postsurgical follow up, hypotony with hyphema and choroidal haemorrhage occurred. It took two months to disappear totally without necessity of surgical treatment. Furthermore, corneal edema appeared two years after implantation. Due to persistence of edema, penetrating keratoplasty in conjunction with repositioning of the tube was performed. Corneal decompensation required penetrating keratoplasty is a serious complication after implantation of GDD and is shown to be predictive of vision decrease.<sup>[11,22]</sup> Indeed, corneal edema may develop after glaucoma surgery secondary to hypotony or endothelial cell loss. Katoniemi et al.<sup>[11]</sup> also described a corneal decompensation required penetrating keratoplasty in 1 of 7 patients after implantation of a second Molteno filtering device. In TVT study, 7 of 107 patients, who underwent placement of a tube shunt, developed persistent corneal edema requiring corneal transplantation.<sup>[22]</sup> At last, our patient developed another late complication: a tube obstruction by an epithelial membrane that required two operations. Moreover a persistent diplopia appeared 3.5 years after 350 mm<sup>2</sup> Baerveldt implantation. A strabismus operation was also performed.

Eventually, the patient also developed epithelial ingrowth. It occurs when an epithelial membrane enters an eye through a wound and then proliferates over the corneal endothelium, trabecular meshwork, anterior iris surface and vitreous face. The epithelial membrane in the angle can contract, producing peripheral angle synechiae and severe angle closure glaucoma. It has been described after several circumstances, particularly penetrating keratoplasty, glaucoma surgery, cataract surgery, penetrating trauma. In our patient, it probably resulted from the penetrating keratoplasty.

## ★ CONCLUSION ★

This case illustrates the difficulties in managing JIA related secondary glaucoma. Glaucoma is a complication of JIA and is one of the most common causes of visual loss in uveitic glaucoma. It can occur late in the stage of the disease. It is a therapeutic challenge because of the complex balance between controlling both glaucoma and inflammation. The use of immunosuppressive drugs is associated with reduced risk of visual loss. Medical therapy must be preferred at first, while surgery must be performed in case of medically uncontrolled IOP. There is no consensus regarding the best surgical procedure. It is associated with a high percentage of failure and complications. Repeat surgery seems to be less successful at achieving IOP reduction.

## ★ REFERENCES ★

1. Camuglia JE, Whitford CL, Hall AJ. Juvenile idiopathic arthritis associated uveitis in adults: a case series. *Ocul Immunol Inflamm*. 2009 Sep-Oct;17(5):330-4.
2. Ceballos EM, Parrish RK 2nd, Schiffman JC. Outcome of Baerveldt glaucoma drainage implants for the treatment of uveitic glaucoma. *Ophthalmology*. 2002 Dec;109(12):2256-60.
3. Chawla A, Mercieca K, Fenerty C, Jones NP. Outcomes and Complications of Trabeculectomy Enhanced With 5-Fluorouracil in Adults With Glaucoma Secondary to Uveitis. *J Glaucoma*. 2012 Jun 14.
4. Dahan E, Carmichael TR. Implantation of a miniature glaucoma device under a scleral flap. *J Glaucoma*. 2005 Apr;14(2):98-102.
5. Dupas B, Fardeau C, Cassoux N, Bodaghi B, LeHoang P. Deep sclerectomy and trabeculectomy in uveitic glaucoma. *Eye (Lond)*. 2010 Feb;24(2):310-4.
6. Gregorij AC 2nd, Kempen JH, Daniel E, Kaçmaz RO, Foster CS, Jabs DA, Levy-Clarke GA, Nussenblatt RB, Rosenbaum JT, Suhler EB, Thorne JE; Systemic Immunosuppressive Therapy for Eye Diseases Cohort Study Research Group. Risk Factors for Loss of Visual Acuity among Patients with Uveitis Associated with Juvenile Idiopathic Arthritis: The Systemic Immunosuppressive Therapy for Eye Diseases Study. *Ophthalmology*. 2012 Oct 11.
7. Iwao K, Inatani M, Seto T, Takihara Y, Ogata-Iwao M, Okinami S, Tanihara H. Long-term Outcomes and Prognostic Factors for Trabeculectomy With Mitomycin C in Eyes With Uveitic Glaucoma: A Retrospective Cohort Study. *J Glaucoma*. 2012 Aug 14.
8. Kaburaki T, Koshino T, Kawashima H, Numaga J, Tomidokoro A, Shirato S, Araie. Initial trabeculectomy with mitomycin C in eyes with uveitic glaucoma with inactive uveitis. *Eye (Lond)*. 2009 Jul;23(7):1509-17.
9. Kanski JJ. Juvenile arthritis and uveitis. *Surv Ophthalmol*. 1990 Jan-Feb;34(4):253-6
10. Kesen MR, Setlur V, Goldstein DA. Juvenile idiopathic arthritis-related uveitis. *Int Ophthalmol Clin*. Summer 2008;48(3):21-38.
11. Kotaniemi K, Sihto-Kauppi K. Occurrence and management of ocular hypertension and secondary glaucoma in juvenile idiopathic arthritis-associated uveitis: An observational series of 104 patients. *Clin Ophthalmol*. 2007 Dec;1(4):455-9.
12. Malik R, Ellingham RB, Suleman H, Morgan WH. Refractory glaucoma--tube or diode? *Clin Experiment Ophthalmol*. 2006 Nov;34(8):771-7.
13. Moltano AC, Sayawat N, Herbison P. Otago glaucoma surgery outcome study : Long-term results of uveitis with secondary glaucoma drained by Moltano implants. *Ophthalmology*. 2001 Mar;108(3):605-13.
14. Moororthy RS, Mermoud A, Baerveldt G, Minckler DS, Lee PP, Rao NA. Glaucoma associated with uveitis. Survey of ophthalmol, march-april 1997
15. Murphy CC, Burnett CA, Spry PG, Broadway DC, Diamond JP. A two centre study of the dose-response relation for transscleral diode laser cyclophotocoagulation in refractory glaucoma. *Br J Ophthalmol*. 2003 Oct;87(10):1252-7.
16. Ozdal PC, Vianna RN, Deschênes J. Ahmed valve implantation in glaucoma secondary to chronic uveitis. *Eye (Lond)*. 2006 Feb;20(2):178-83.
17. Panek WC, Holland GN, Lee DA, Christensen RE. Glaucoma in patients with uveitis. *Br J Ophthalmol*. 1990 Apr;74(4):223-7
18. Papadaki TG, Zacharopoulos IP, Pasquale LR, Christen WB, Netland PA, Foster CS. Long-term results of Ahmed glaucoma valve implantation for uveitic glaucoma. *Am J Ophthalmol*. 2007 Jul;144(1):62-69.
19. Patitsas CJ, Rockwood EJ, Meisler DM, Lowder CY. Glaucoma filtering surgery with postoperative 5-fluorouracil in patients with intraocular inflammatory disease. *Ophthalmology*. 1992 Apr;99(4):594-9.
20. Sijssens KM, Los LI, Rothova A, Schellekens PA, van de Does P, Stilma JS, de Boer HJ. Long-term ocular complications in aphakic versus pseudophakic eyes of children with juvenile idiopathic arthritis-associated uveitis. *Br J Ophthalmol*. 2010 Sep;94(9):1145-9.
21. Skarin A, Elborgh R, Edlund E, Bengtsson-Stigmar E. Long-term follow-up of patients with uveitis associated with juvenile idiopathic arthritis: a cohort study. *Ocul Immunol Inflamm*. 2009 Mar-Apr;17(2):104-8.
22. Steven J. Gedde, Leon W. Herndon, James D. Brandt, Donald L. Budenz, William J. Feuer, Joyce C. Schiffman, Tube Versus Trabeculectomy Study Group. Postoperative Complications in the Tube Versus Trabeculectomy (TVT) Study During Five Years of Follow-up, *American Journal of Ophthalmology*, Volume 153, Issue 5, May 2012, Pages 804-814.e1.
23. Sung VC, Barton K. Management of inflammatory glaucomas. *Curr Opin Ophthalmol*. 2004 Apr;15(2):136-40.
24. Towler HM, McCluskey P, Shaer B, Lightman S. Long-term follow-up of trabeculectomy with intraoperative 5-fluorouracil for uveitis-related glaucoma. *Ophthalmology*. 2000 Oct;107(10):1822-8.
25. Välimäki J, Airaksinen PJ, Tuulonen A. Moltano implantation for secondary glaucoma in juvenile rheumatoid arthritis. *Arch Ophthalmol*. 1997 Oct;115(10):1253-6.
26. Vuori ML. Moltano aqueous shunt as a primary surgical intervention for uveitic glaucoma: long-term results. *Acta Ophthalmol*. 2010 Feb;88(1):33-6.
27. Wamsley S, Moster MR, Rai S, Alvim HS, Fontanarosa J. Results of the use of the Ex-PRESS miniature glaucoma implant in technically challenging, advanced glaucomacases: a clinical pilot study. *Am J Ophthalmol*. 2004 Dec;138(6):1049-51.

★ FIGURES ★

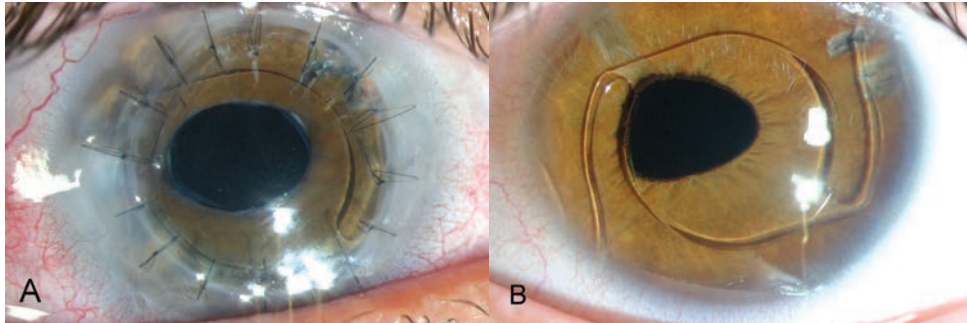


Figure 1 : A. Color photograph of the right eye showing the corneal graft, one month following penetrating keratoplasty (2007).  
B. Color photograph of the left eye.

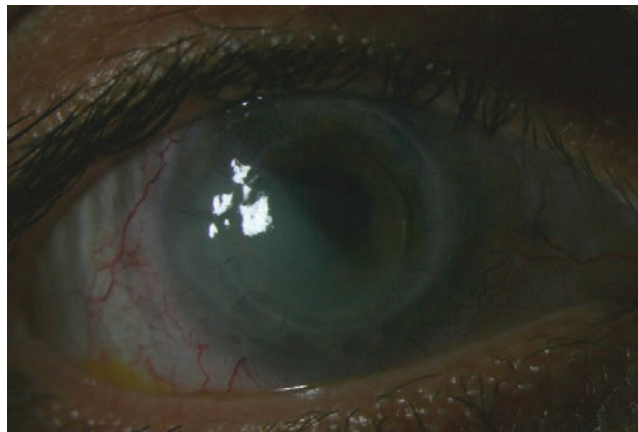


Figure 2 : Color photograph of the right eye showing temporal edema of the corneal graft in November 2009

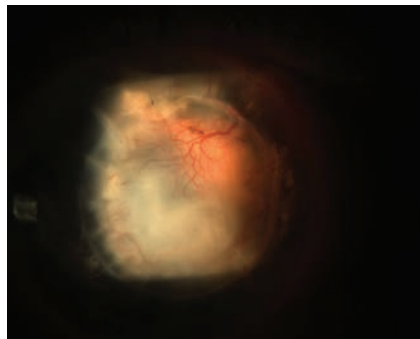


Figure 3 : Color photograph of the right eye showing corneal graft rejection (2012).

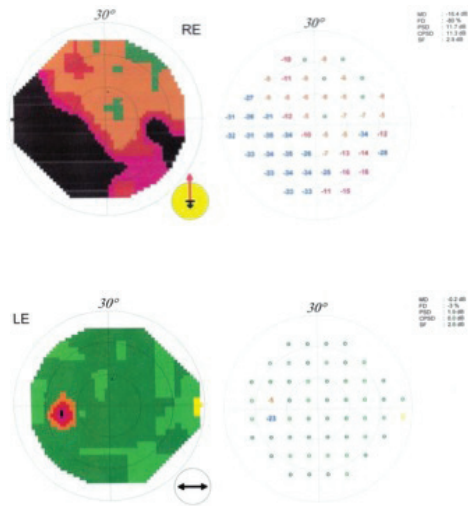


Figure 4: Visual field of the right eye and the left eye (October 2001)

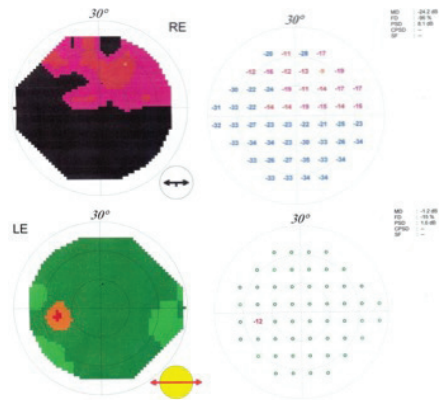


Figure 5: Visual fields of the right eye and the left eye (February 2009)





.....  
**DIFFICULTIES IN THE TREATMENT  
OF GLAUCOMA PATIENTS WITH  
ALLERGIC REACTION FOR  
ANTIGLAUCOMA EYE DROPS**  
.....

★ **INTRODUCTION** ★

Glaucoma is a neuropathy of the optic nerve. It is characterized by the atrophy of the optic disc and cause defects in the visual field. It is a slowly progressing disease and, if left untreated, can lead to blindness. Its pathogenesis still remains unclear<sup>[1]</sup>. One of the reasons may be chronic, local or general use of corticosteroids. In predisposed persons can lead to steroid glaucoma, caused by morphological and functional changes in the trabecular meshwork system<sup>[2]</sup>. Corticosteroids (glucocorticoids), used frequently as potent anti-inflammatory agents, increase the risk of glaucoma by raising the intraocular pressure (IOP) when administered exogenously (topically, periocularly or systemically) responsiveness of the patient<sup>[3]</sup>. Because glaucoma is a chronic disease the topical treatment usually has to be continued for a long time and side effects may cause serious problems<sup>[1]</sup>.

## ★ CASE PRESENTATION ★

26 year-old Caucasian male admitted to the Ophthalmology Ward because of the pain of the right eye and headaches on the right side, with an elevated intraocular pressure (IOP) to 58 mmHg OD and 24mmHg OS. In an interview with chronic use of artificial tears, dexamethasone and other corticosteroids topically due to conjunctivitis and eye discomfort ( since 2005) , there was no glaucoma in family history. No previous ocular trauma or surgery. Allergy to pollen and animal dander in childhood, allergy tests negative in adulthood.

Visual acuities without correction: 20/20 OD, 20/20 OS

Gonioscopy showed wide open angles and uneven iris insertion, with no abnormal pigmentation.

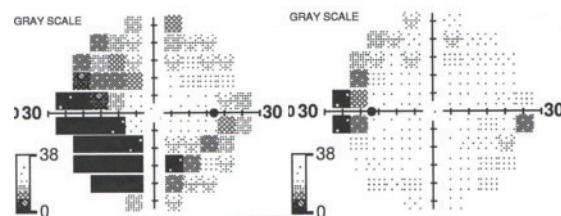


Figure 1: Humphrey Visual Field test results show defects that are typical for glaucoma.

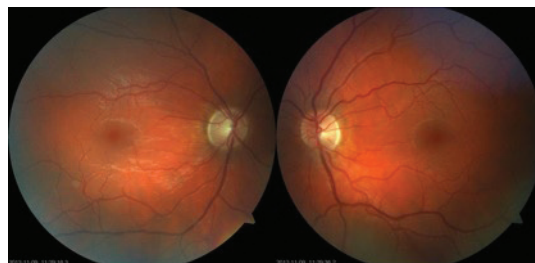

Figure 2: Optic nerve photographs show grey color of the optic disc in right eye.

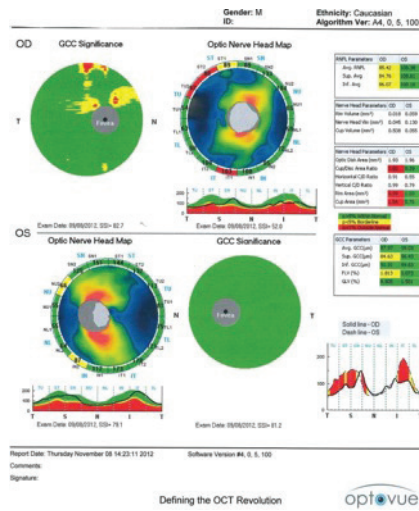


Figure 3. SLO-OCT borderLine thin NFL in right eye.

OCT	Right eye	Left eye
CCT	537 $\mu\text{m}$	542 $\mu\text{m}$
ACD	2,84 mm	2,81 mm
ACA nasal	27 °	29 °
ACA temporal	36 °	24 °

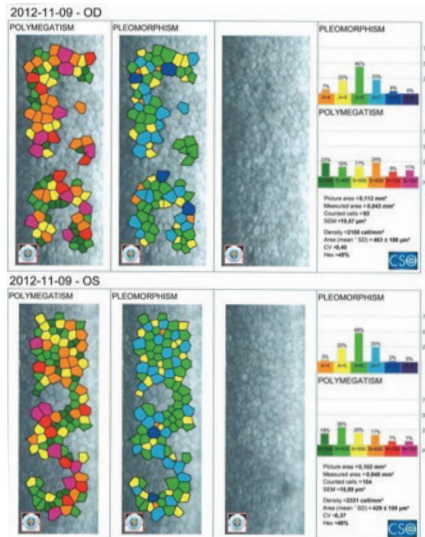


Figure 4. Central endothelial cell density reduced 2158 cell/mm<sup>2</sup> OD, 2331 cell/mm<sup>2</sup> OS

After normalization of IOP (18mmHg OD, 17mmHg OS) patients discharged from the Department of Ophthalmology. Recommended monitoring in the outpatient clinic and drugs OU: Cosopt 2x, Xalatan 1x. In the outpatient clinic after 2 days Cosopt discontinued because of a strong burning eyes after application and Azopt 2x included, Xalatan 1x remained. After a month Azopt changed for Dorzolamide 2x because of blurred vision, eye redness, itching, burning, Xalatan 1x remained. Next changes of drugs for the same reasons. After 10 days discontinued Dorzolamide and Brimoteva 2x included, Xalatan 1x remained. After 2 weeks discontinued Brimoteva only instilled Xalatan 1x. After 1 week Xalatan changed for Travatan 1x. After 10 days included Brimoteva 1x, Travatan 1x remained. After 3 weeks discontinued Brimoteva, Travatan 1x remained. At all visits in the outpatient clinic IOP measurements were about 11-16mmHg OU. After 2 weeks only installed Travatan 1x patient reported to ophthalmic emergency room because of blurred vision, eye discomfort, eye redness, burning and itching of the eyes.

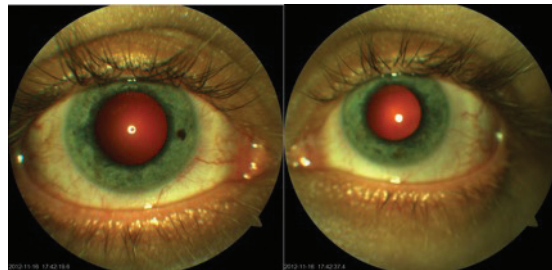


Figure 5. Allergic reaction

Discontinued Travatan and Taflotan (preservative-free tafluprost) 1x included. After 10 days of use Taflotan, the patient observed a reduction in symptoms of eye irritation and improve visual comfort.

## ★ DISCUSSION ★

Preservatives protect multiple dosage eye drops against microbial contamination. Ocular tolerance of these chemicals can vary. It may result in adverse toxic or allergic reactions. The main preservatives involved in allergic contact reactions are thiomersal, chlorhexidine, EDTA, BAK, sorbic acid, phenylmercuric nitrate and polyquat. An allergic reaction to the preservative may include: itching, burning sensations of the eye, epiphora, photophobia, foreign body sensation, follicular conjunctivitis, eczematoid blepharitis, periocular dermatitis, conjunctival hyperemia, discharge and edema <sup>[4]</sup>. Adverse effects of the preservative-containing topical antiglaucoma medications on the ocular surface are well documented. Benzalkonium chloride (BAK), a cationic detergent is the most common preservative of the eye drops. BAK changing the ionic resistance of the cell membranes, causes protein denaturation and disruption of the cytoplasmic membranes. It may also induce immuno-allergic reactions and dry eye syndrome. Its cytotoxic effects are dose dependent and are responsible for its pro-apoptotic and necrotic effects <sup>[1]</sup>. Prolonged use of eye drops containing BAK has been assumed to induce toxic endothelial degeneration in human eyes. Single layer of hexagonal cells of endothelium do not regenerate. Therefore, damage to endothelium is far more serious than damage to the epithelium is accompanied by marked corneal swelling and results in loss of corneal transparency <sup>[4]</sup>. All antiglaucoma drugs may affect the corneal endothelial cell function through alteration of the Ca<sup>2+</sup> mobility. Corneal swelling in the absence of extracellular calcium is probably due to the induction of morphologic changes in the endothelium, such as rounding of the cells, loss of their apical junctions, and increased membrane permeability for calcium <sup>[1]</sup>.

To minimize these side-effects of the long-term therapy a once-a-day application of the preservative-free, BAKfree, long-acting eyedrops should be recommended in almost all of the glaucoma cases. Compared with the preserved latanoprost, travoprost, and bimatoprost the preservative-free solution of tafluprost (PF tafluprost) showed reduced toxicity and very low pro-apoptotic or pro-oxidative activities in the human conjunctival epithelial cell lines in vitro <sup>[1]</sup>.

## ★ CONCLUSION ★

Topical ophthalmic medications sometimes may cause toxic or allergic reactions resulting in iatrogenic ocular disease [4]. Because of serious side-effects of antiglaucoma drugs, chronic topical treatment of the glaucoma patients may be very difficult. A rational decision about the long-term therapy is very important and choices between the one day-dosing drugs, combined formulations, preservative-free, or less toxic medicines should always be considered [1].

## ★ REFERENCES ★

1. Pożarowska D. *Toxic effects of antiglaucoma drugs on superficial tissues of the eye* Department of Ophthalmology, Medical University, Lublin, Poland Int. Rev. Allergol. Clin. Immunol., 2008; Vol. 14, No. 3-4
2. Niżankowska M.H. *Basis of clinical ophthalmology*, 2007
3. Tripathi R.C.; Parapuram S.K.; Tripathi B.J.; Zhong Y.; Chalam K.V. *Corticosteroids and Glaucoma Risk* Drugs & Aging, Volume 15, Number 6, December 1999, pp. 439-450(12)
4. Furrer P., Mayer J. M., Gurny R. *Ocular tolerance of preservatives and alternatives* European Journal of Pharmaceutics and Biopharmaceutics Volume 53, Issue 3, May 2002, Pages 263– 280



# OBSTRUCTIVE SLEEP APNEA SYNDROME AND GLAUCOMA : HOW STRONGLY ARE THEY ASSOCIATED ?

## ★ INTRODUCTION ★

Glaucoma is the second leading cause of blindness of the world and the first cause in many developed countries<sup>(1)</sup>. Classically glaucomatous neuropathy is associated with intraocular hypertension (IOHT). Particular cases of the disease, as normal tension glaucoma (NTG), and recent evidence of different physiopathologic mechanisms revealed other ocular and systemic risk factors to glaucoma<sup>(2)(3)</sup>. Growing evidence relating vascular disorders (nocturnal lower blood pressure, subclavian artery stenosis, atrial fibrillation, among others) and glaucoma suggests that compromised blood flow and ischemia are important factors in its pathogenesis.

OSAS is a sleep disorder characterized by recurrent partial or total upper airway obstruction during sleep. It is an important independent risk factor for neurologic and cardiovascular disease<sup>(4)</sup>, and has been associated with important vascular and cardiac modifications during sleep. A strong association has been found between OSAS and open angle glaucoma<sup>(5)</sup>, and some authors have hypothesized that the typical cardiovascular modifications observed in OSAS would induce a transitory neuroretinal ischemia that may be the trigger to the development of glaucomatous neuropathy. However, no A level evidence has yet emerged to corroborate this finding<sup>(6)</sup>.

In this case report we describe the evolution of a patient suffering from glaucomatous neuropathy, in whom the diagnosis of OSAS has changed the course of the glaucomatous disease.

## ★ CASE REPORT ★

This case reports to a 79 years old male, Caucasian, retired from construction work business, with past ocular history of minor refractive error correction with spectacles and primary open angle glaucoma of both eyes (OU) diagnosed 2 years ago, treated medically with instillation of combined colirium of timolol and dorzolamide 5+20mg/ml, twice a day. Past systemic history of primary arterial hypertension, treated with amlodipine/valsartan 5/80 mg pill at night, roncopathy and previous episode of Thrombophlebitis of right superficial lower limb vein 3 years ago. The patient had no family history of glaucoma or other severe ophthalmic pathology. The patient had neither complaints nor symptoms related to the disease or the treatment, which he claimed to administer rigorously. Nevertheless, during normal follow-up in ophthalmology consultation, the series of automated static perimetry (ASP) (Octopus 501® dG2 program) revealed progressive visual field defect. A superior arcuate scotoma in the right eye (OD) (Fig. 1) showed slight evidence of progression and a double arcuate scotomata affecting both superior and inferior visual fields in the left eye (OS) (Fig. 2) showed obvious progression of visual field loss.

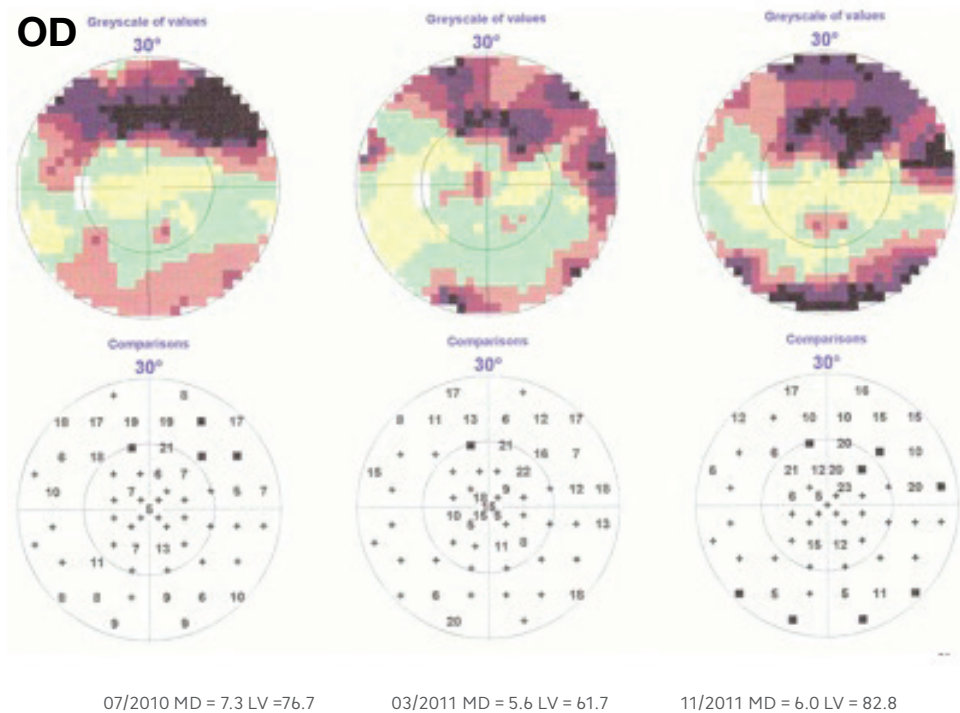


Figure 1 : Automated static perimetry (Octopus 501® dG2 program) of OD. MD – mean deviation; LV – loss of variance.



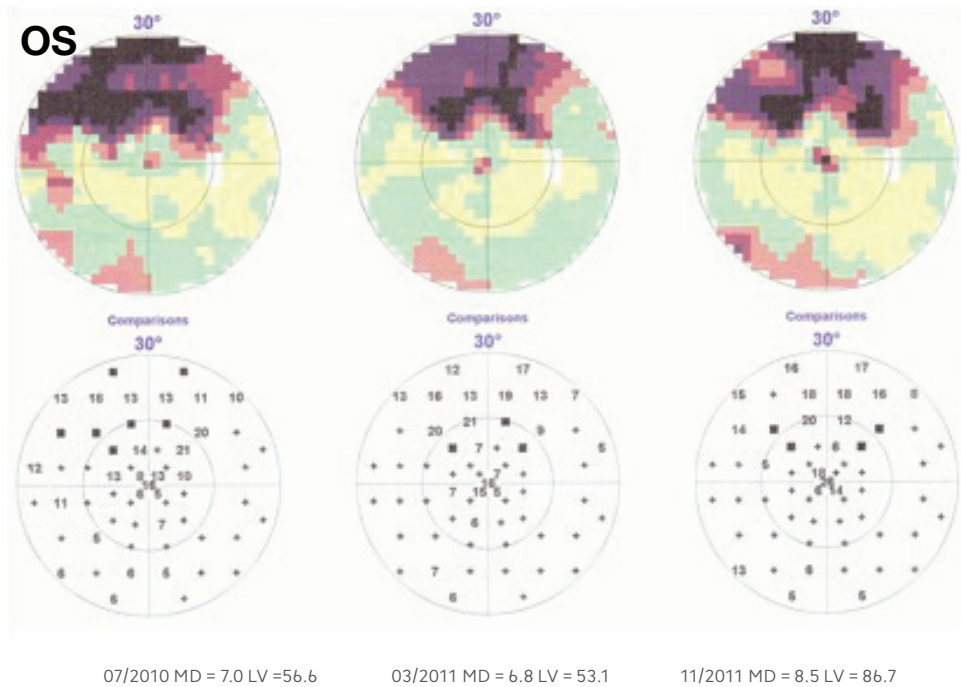


Figure 2: Automated static perimetry (Octopus 501® dG2 program) of OS. MD – mean deviation; LV – Loss of variance.

A complete ophthalmic examination was performed and unveiled :

- Best corrected visual acuity of +0.1 logMAR OU;
- Intra-ocular pressure evaluation performed with Goldman aplanation tonometer showed 10 mmHg in both eyes;
- Gonioscopic observation revealed a grade IV Schaffer angle all over the 360° in both right and left eye;
- Slit-lamp examination disclosed incipient corticonuclear cataracts (Lens Opacities Classification System III NII CII P0) bilaterally;
- Vitreous and fundus examination revealed optic disks with a symmetrically augmented excavation, with a cup/disk ratio of 0.7. The diminished neuroretinal rim presented with an inferior notch in the two eyes. Both type A and B peripapillary atrophy were patent. Discrete pigmented epithelium atrophy was present and a slight arteriolar tightening was also seen. No macular alterations were visible (Fig. 3 and 4).

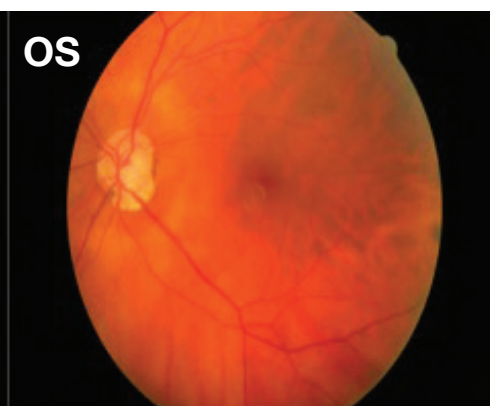
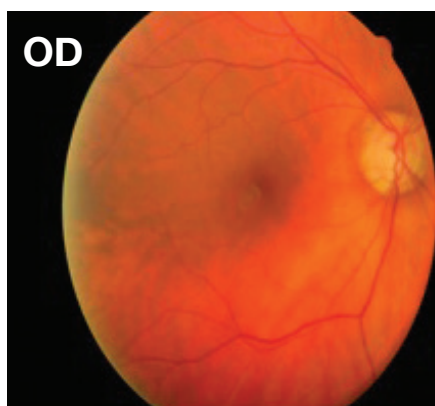
Figure 3: OD Retinography.

Figure 4: OS Retinography

**OBSTRUCTIVE SLEEP APNEA SYNDROME AND GLAUCOMA :  
HOW STRONGLY ARE THEY ASSOCIATED ?**

The diagnosis of NTG with progression was established. The evaluation was completed with more diagnostic data. Pachymetric evaluation (Alcon® Ocuscan RXP) of the corneal central thickness revealed mean values of 516  $\mu\text{m}$  in the OD and 508  $\mu\text{m}$  in the OS. Structural evaluation of the retinal nerve fiber layer (RNFL) (Heidelberg Engineering® Spectral-domain Optic Coherence Tomography) revealed generalized decrease in nervous layer thickness, most evident in the inferior quadrant of OD and in the inferior and superior quadrant of OS (Fig. 5).

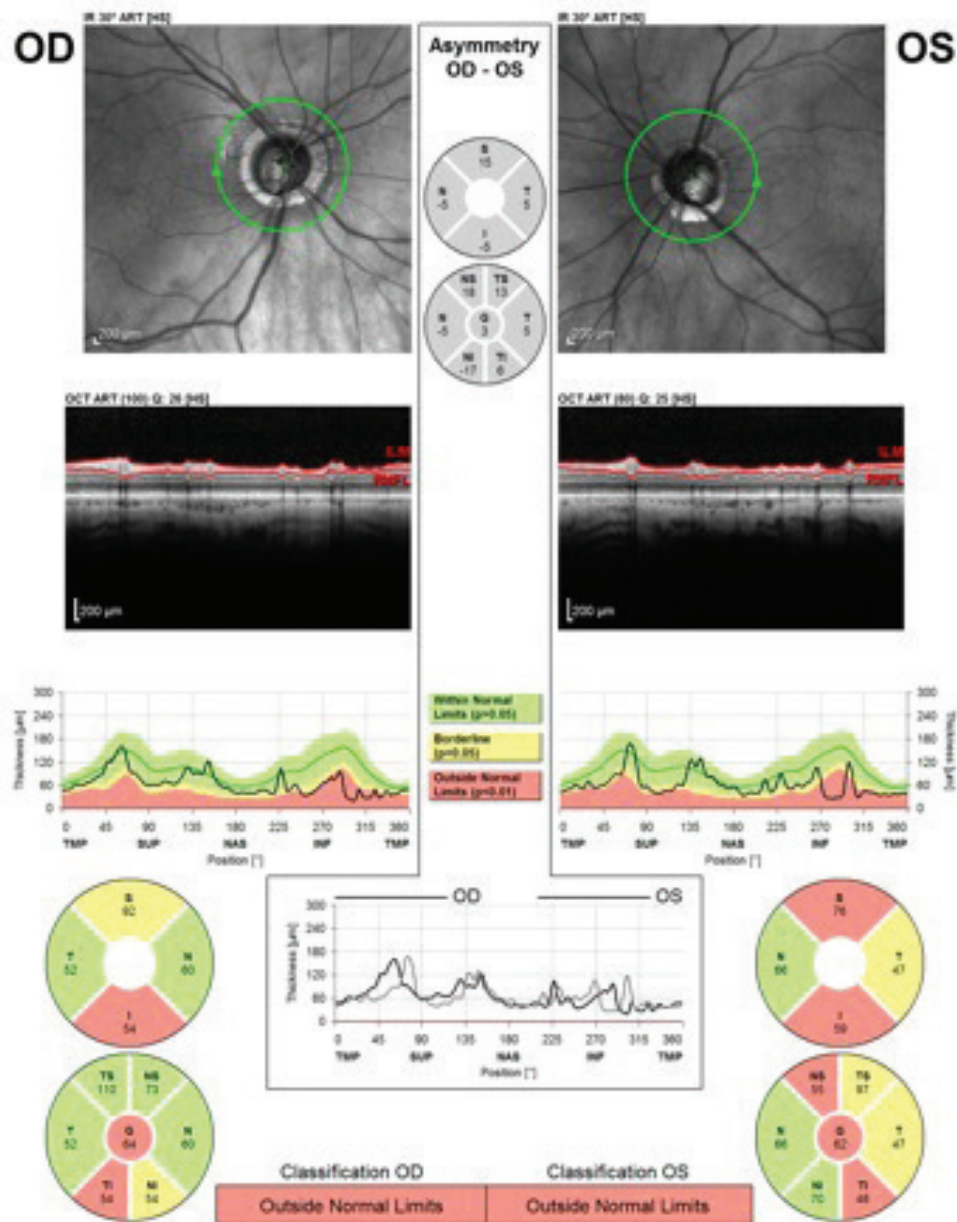


Figure 5: Spectral-Domain Optic Coherence Tomography (OCT). Upper images show enlargement of optic disk excavation and peripapillary atrophy. The analysis of OD's RNFL reveals a depletion (54 $\mu\text{m}$ ) in the inferior quadrant. In OS both superior and inferior quadrants show important decrease of RNFL, with 76 $\mu\text{m}$  and 59 $\mu\text{m}$ , respectively.

A thorough investigation for a secondary cause of glaucoma was initiated. A cranial and orbital CT scan was performed and revealed only early phase atheromatosis plates on the carotid artery bifurcation. Carotid and neck vessels ultrasonography confirmed that these findings had no hemodynamic repercussion and excluded other vascular pathologic findings. Ophthalmic circulation ultrasonography revealed normal hemodynamic flow and velocity of the ophthalmic, short posterior ciliar and central retina arteries. An Arterial Pressure Ambulatory Monitoring (APAM) examination was conducted, which reported stage 1 systolic arterial hypertension (Arterial Pressure (AP) mean value 141/71 mmHg), with a nocturnal dipper profile (AP mean diurnal value of 145/74 mmHg, AP mean nocturnal value of 134/66 mmHg). Since the patient had documented roncopathy, a polysomnography was performed. It had the duration of 3 hours and 12 minutes and during that period 78 respiratory events were documented, 55 episodes of obstructive apneas, 3 episodes of central apneas and 20 episodes of hypopnea. Mean oxygen saturation levels were of 95%, with minimum value of 76% and a 8 minutes period with 90% saturation level (Fig 6).

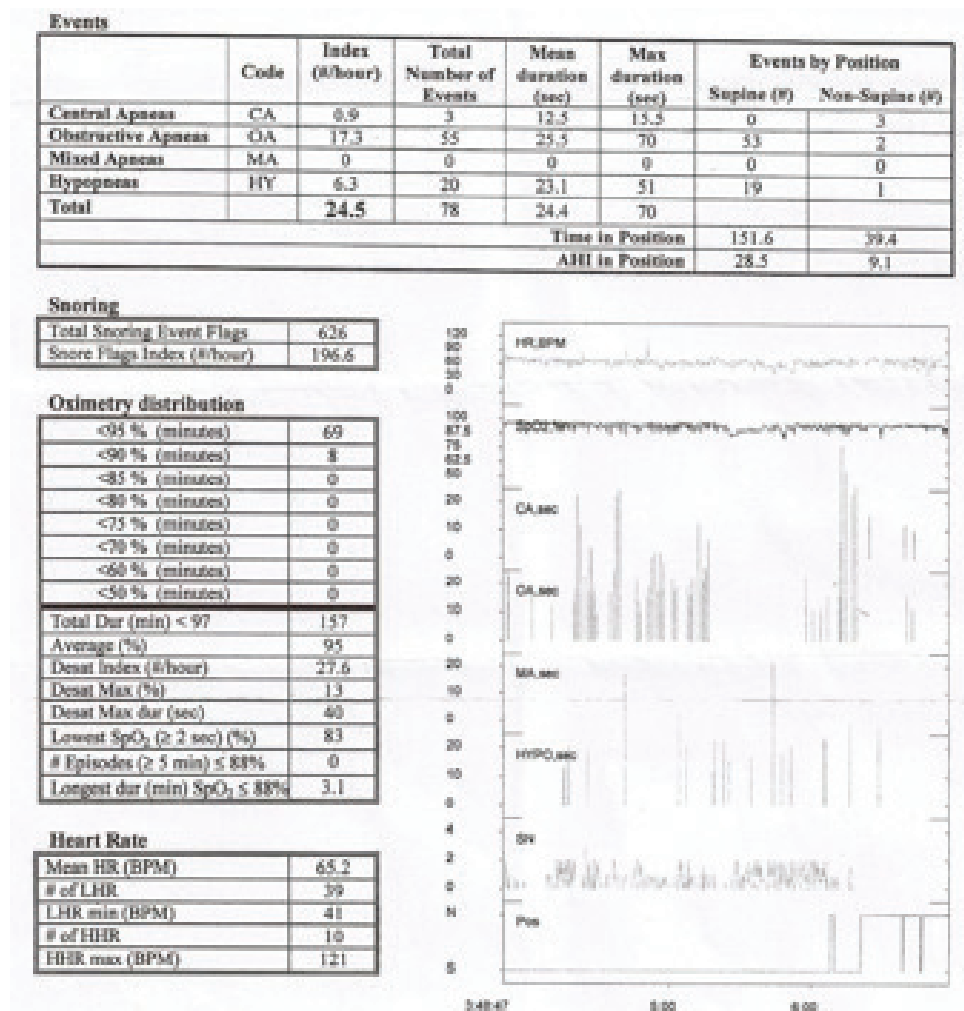


Figure 6: Polysomnographic evaluation report.

**OBSTRUCTIVE SLEEP APNEA SYNDROME AND GLAUCOMA :  
HOW STRONGLY ARE THEY ASSOCIATED ?**

.....

The patient was diagnosed with moderate OSAS and nocturnal therapy with continuous Positive Airway Pressure (cPAP) was initiated at the end of November 2011.

The patient continued the same ophthalmologic treatment and ophthalmic consultation every trimester. On June 2012 maintained a similar ophthalmologic objective examination. A ASP evaluation was performed and clear signs of stabilization and regression of the visual fields defects in both eyes were documented (Fig. 7 and 8).

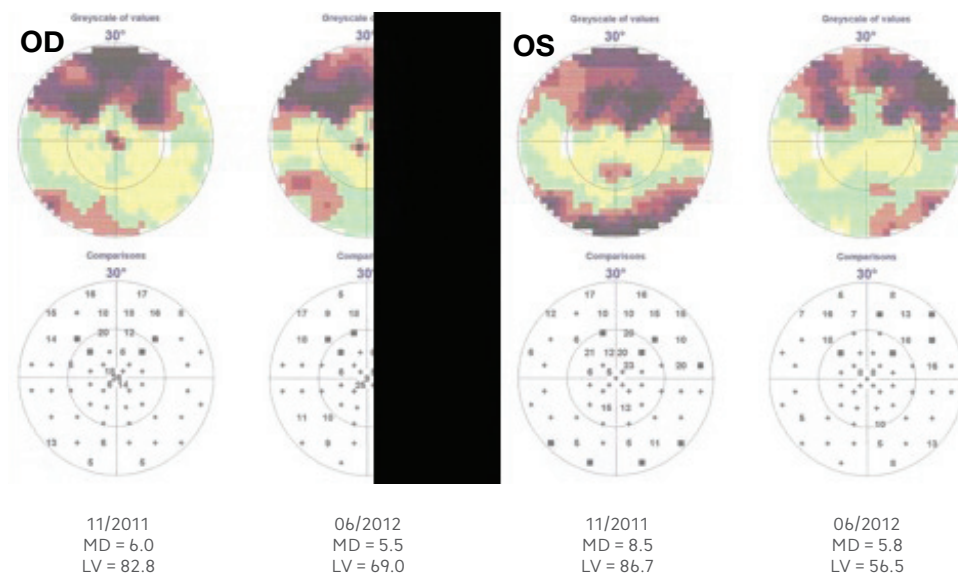


Figure 7 and 8: Automated static perimetry (Octopus 501® dG2 program) of OD and OS, respectively. MD – mean deviation; LV – Loss of variance.

The patient evaluated every trimester and there wasn't any ophthalmologic examination alteration and no new signs of progression were seen in the visual fields monitorization until the present day.

## ★ DISCUSSION ★

The relationship between sleep breathing disorders and glaucomatous neuropathy is a theme of growing interest in the scientific community. In 2000, Onen<sup>(7)</sup> and collaborators observed a high prevalence of snoring and excessive daytime sleepiness among patients with primary open angle glaucoma. Since then, populational studies found also a high prevalence of glaucoma in patients with previous diagnosis of OSAS. Incidence of glaucoma higher than general population was found in many studies<sup>(5)(8)</sup>. Bendel<sup>(8)</sup> obtained a prevalence of 27% for glaucoma among one hundred patients with moderate to severe OSAS, although he found no relation between IOP and the sleep disorder. Visual function abnormalities were also increased in OSAS patients, with a higher incidence of visual defects<sup>(9)</sup>, and the incidence of structural defects with lower RNFL was identified in individuals suffering from moderate to severe OSAS<sup>(10)</sup>. In this patient a glaucomatous neuropathy was already diagnosed a year ago, with documented optic disk alterations and typical visual field defects. The emergence of visual field defects progression with pharmacologically controlled IOP arouses the need for further investigation to exclude secondary causes of glaucoma. The medical history of roncopathy and the exclusion of vascular pathologic findings conducted to the polysomnographic study, which enabled OSAS diagnosis and treatment with nocturnal cPAP.

The association of OSAS and glaucomatous neuropathy is not restricted to primary open angle glaucoma with increased IOP, but also with NTG<sup>(11)</sup>. This finding is consistent with the theory of a different physiopathological mechanism that involves the cardiovascular alterations caused by OSAS. The respiratory and vascular modifications typically seen in OSAS (high intrathoracic pressure, decreased circulation levels of oxygen, autonomic alterations with augmented sympathetic discharge, elevated pulmonary and systemic arterial pressure) cause instability of tissue oxygenation, with consequent endothelial dysfunction. This cascade of events compromises ganglion cells metabolism, causing hypoxia, oxidative stress and cell apoptosis. This continuous and repetitive process results in progressive visual field narrowing and vision loss<sup>(12)</sup>. This mechanism explains the normal IOP found in this patient, attributing the progressive visual loss to the insufficient vascular supply caused by OSAS.

Furthermore, in this case one can identify a obvious relation between the beginning of cPAP nocturnal treatment and the stabilization of the visual field defect, since there was no other apparent factor modified during this time gap. The glaucomatous neuropathy was probably stopped by the reestablishment of normal vascular hemodynamic in the eye during sleep. Although anecdotic, the cause-effect relation can not be ignored and is consistent with other studies findings of the association of NTG and OSAS. Nevertheless, a study found deleterious effects of nocturnal cPAP treatment, with increase in IOP mean levels and decrease in ocular perfusion pressure<sup>(13)</sup>. On the other hand, Kadyan and collaborators<sup>(14)</sup> suggested a possible beneficial effect of cPAP treatment in glaucomatous neuropathy in patients with OSAS, associated with other beneficial effects in ocular surface disease. Further studies are needed to clarify the effect of cPAP treatment on glaucomatous neuropathy and the risk-benefit of this treatment should always be weighed for each individual case.

## ★ CONCLUSION ★

Nowadays growing scientific evidence points out OSAS as a secondary cause of open angle glaucoma and NTG. This is particularly obvious in moderate to severe cases of OSAS. The physiopathologic mechanism is probably related with ocular vascular flow impairment that leads to hypoxia and oxidative stress, with consequent ischemia of neural retina and neural death. The structural and functional consequences are manifest and equivalent to glaucomatous neuropathy progression. This case report value is focused on the cause-effect relation between the beginning of cPAP treatment for OSAS and the visual field defect stabilization, which confirms the delaying of glaucomatous neuropathy evolution. Multicentric, prospective, randomized controlled trials are needed to confirm and evaluate the strength of the association of these two diseases.

## ★ REFERENCES ★

- (1) Glaucoma is second leading cause of blindness globally. *Bull World Health Organ* 2004;82(11):887.
- (2) Mozaffarieh M, Flammer J. New insights in the pathogenesis and treatment of normal tension glaucoma. *Curr Opin Pharmacol.* 2012 Oct 20. pii: S1471-4892(12)00197-X. doi: 10.1016/j.coph.2012.10.001.
- (3) Douglas R Anderson. Normal-tension glaucoma (Low-tension glaucoma) *Indian J Ophthalmol.* 2011 January; 59(Suppl1): S97-S101. doi: 10.4103/0301-4738.73695
- (4) Olson EJ, Moore WR, Morgenthaler TI, Gau PC, Staats BA. Obstructive sleep apnea hypopnea syndrome. *Mayo Clin Proc.* 2003;78: 1545-1552.
- (5) Mojon DS, Hess CW, Goldblum D, Fleischhauer J, Koerner F, Bassetti C, Mathis J. High prevalence of glaucoma in patients with sleep apnea syndrome. *Ophthalmology.* 1999 May;106(5):1009-12.
- (6) C A Girkin, G McGwin, Jr, S F McNeal, C Owsley. Is there an association between pre-existing sleep apnoea and the development of glaucoma? *Br J Ophthalmol.* 2006 June; 90(6): 679-681. doi: 10.1136/bjo.2005.086082
- (7) Onen SH, Mouriaux F, Berramdane L, Dascotte JC, Kulik JF, Rouland JF. High prevalence of sleep-disordered breathing in patients with primary open-angle glaucoma. *Acta Ophthalmol Scand.* 2000 Dec;78(6):638-41.
- (8) Bendel RE, Kaplan J, Heckman M, Fredrickson PA, Lin SC. Prevalence of glaucoma in patients with obstructive sleep apnoea--a cross-sectional case-series. *Eye (Lond).* 2008 Sep;22(9):1105-9. Epub 2007 May 4.
- (9) Tsang CS, Chong SL, Ho CK, Li MF. Moderate to severe obstructive sleep apnoea patients is associated with a higher incidence of visual field defect. *Eye (Lond).* 2006 Jan;20(1):38-42.
- (10) Lin PW, Friedman M, Lin HC, Chang HW, Pulver TM, Chin CH. Decreased retinal nerve fiber layer thickness in patients with obstructive sleep apnea/hypopnea syndrome. *Graefes Arch Clin Exp Ophthalmol.* 2011 Apr;249(4):585-93. Epub 2010 Oct 19.
- (11) Mojon DS, Hess CW, Goldblum D, Boehnke M, Koerner F, Gugger M, Bassetti C, Mathis J. Normal-tension glaucoma is associated with sleep apnea syndrome. *Ophthalmologica.* 2002 May-Jun;216(3):180-4.
- (12) Calvo P, Ferrández B, Ferreras A, Marín JM. Retinal nerve fiber layer thickness alterations in patients with obstructive sleep apnea. *Arch Soc Esp Ophthalmol.* 2012 Jan;87(1):1-2.
- (13) Kiekens S, Veva De Groot, Coeckelbergh T, Tassignon MJ, van de Heyning P, Wilfried De Backer, Verbraecken J. Continuous positive airway pressure therapy is associated with an increase in intraocular pressure in obstructive sleep apnea. *Invest Ophthalmol Vis Sci.* 2008 Mar;49(3):934-40.
- (14) Kadyan A, Asghar J, Dowson L, Sandramouli S. Ocular findings in sleep apnoea patients using continuous positive airway pressure. *Eye (Lond).* 2010 May;24(5):843-50. Epub 2009 Aug 14.



ACUTE TRANSIENT MYOPIA  
WITH SHALLOWING OF THE  
ANTERIOR CHAMBER INDUCED BY  
SULPHAMETHOXAZOLE IN PATIENT  
WITH PSEUDOXANTHOMA ELASTICUM

★ INTRODUCTION ★

Acute transient myopia with shallowing of the anterior chamber is a known but rare idiosyncratic effect to sulphonamides. This phenomenon has been recognized for many years, and numerous case reports describing it were published. Sulphamethoxazole + trimethoprim (cotrimoxazole) is an antibiotic combination, despite its widespread use for prophylaxis and treatment of numerous infections, there are few case reports of acute transient myopia with shallowing of anterior chamber and functional angle closure glaucoma with this sulfa drug. Clinical picture is generally uniform and ranges from symptoms attributable to acute myopia and if present symptoms attributable to angle closure glaucoma. Symptoms usually appear 1-2 days following drug ingestion and last for 2-8 days after medication has been withdrawn.

The degree of myopia induced by sulphonamides ranges from  $-0.75^{[1]}$  to  $-8^{[2]}$  diopters. In addition to acute myopia, the anterior chamber may become markedly shallower, with risk of acute angle closure glaucoma <sup>[3]</sup>. In most cases, it was reported a favorable clinical outcome, with a complete recovery. There is only one case reported in the literature, in which the final outcome was bilateral phthisis bulbi, despite early diagnosis and prompt withdrawal of the cotrimoxazole<sup>[4]</sup>.

To our knowledge, acute myopia with shallowing of the anterior chamber has not been described as an ocular manifestation of Pseudoxanthoma Elasticum. There is one case reported in the literature about transient myopia and angle closure glaucoma induced by cotrimoxazole in a patient with bilateral few retinal stria radiating from the macula<sup>[3]</sup>. Although unlikely, the relationship between Pseudoxanthoma Elasticum and the development of acute myopia and angle closure glaucoma cannot be completely ruled out. On the other hand we cannot exclude a possible predisposition for ocular side effects of sulfonamides in patients with Pseudoxanthoma Elasticum.

## ★ CASE REPORT ★

A 45 year old white woman with no previous ocular known disease was admitted to our emergency department with 2-days history of bilateral visual loss, headache and generalized itching. Arterial hypertension was diagnosed 2 weeks before the onset of the clinical picture, and she was medicated with fosinopril. Patient was also treated for cystitis with sulphamethoxazole (800mg) + trimethoprim (160 mg) and tropsium chloride (20 mg) that were started five days before. On examination the best corrected visual acuity was 6/10 (-3.50 - 1.50x100°) in the right eye and 9/10 (-4.00 - 0.75x70°) in the left eye.

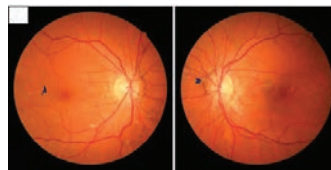


Figure 1 - Retinography images (A) right eye, (B) left eye. Bilateral angioid streaks (arrowheads), peau d'orange pigmentary pattern of the retina (stars)

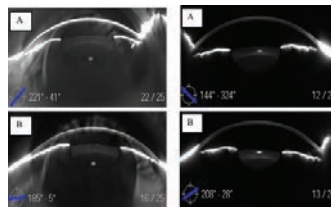


Figure 2 - PENTACAM images (A) right eye, (B) left eye) of the anterior chamber and angle opening during the acute phase. Shallow anterior chambers with narrow angles (19.4° in the right eye // 19.2° in the left eye).

Figure 3 - PENTACAM images (A) right eye, (B) left eye) of the anterior chamber and the angle opening during the convalescent phase. Complete resolution of the iris-lens diaphragm anterior displacement.

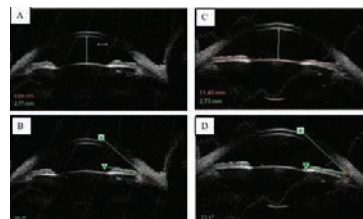


Figure 4 - Ultrasound Biomicroscopic images (A,B) right eye, (C,D) left eye) of the anterior chamber and angle during the convalescent phase. Central ACD: 2.77mm RE// 2.73 mm LE. Angle opening 30.7° RE // 32.1° LE.

Slit lamp examination disclosed a shallow anterior chamber in both eyes. Goldmann applanation tonometry revealed intraocular pressure (IOP) of 36 mmHg in the right eye and 38 mmHg in the left eye. Zeiss four mirror gonioscopy was performed and revealed slit angles in both eyes. Indentation gonioscopy opened the angles and no peripheral anterior synechiae (PAS) could be observed. The remaining anterior segment examination of both eyes was unremarkable. Undilated fundus examination of both eyes disclosed few retinal striae radiating from the papilla in both eyes compatible with angioid streaks (figure 1). External examination showed several redundant skin folds on the neck and axillae. Pentacam was subsequently performed (figure 2), and confirmed the presence of shallow anterior chambers with narrow angles (19.4° in the right eye // 19.2° in the left eye) in both eyes. It was given topical and systemic intraocular pressure lowering medication with acetazolamide



(500mg id), timolol and brimonidine (one drop in both eyes). After treatment the intraocular pressure, measured by Goldmann applanation tonometry, decreased to 22 mmHg in the right eye and to 20 mmHg in the left eye. The patient was advised to discontinue Cotrimoxazole and was treated with timolol (1 drop 2id) and brimonidine (1 drop 2id). On the following day, the anterior chambers were slightly deeper and the myopic shift was 2.50D in the right eye and -3.00D in the left eye. Intraocular pressure was normal (IOP RE10mmHg // LE 10 mmHg).

The myopic shift further decreased over the following days with progressive deepening of the anterior chamber. One week after, patient best corrected visual acuity was 10/10 in both eyes with +0.50 -1.25x70° on the right eye and -0.75 on the left eye. Goldmann applanation tonometry revealed IOP of 16 mmHg in both eyes. Pentacam was repeated (figure 3), confirming complete resolution of the iris-lens diaphragm anterior displacement. Central anterior chamber depth (ACD) and angle opening measured by Ultrasound Biomicroscopy (UBM) were respectively 2.77mm RE/2.73mm LE and 30.7° RE/32.1° LE (figure 4). The last automated static white-on-white perimetry performed, (program 24-2, SITA standard, Humphrey Instruments, Dublin, CA, USA) disclosed no significant visual field lost (figure 5).

The diagnosis of Pseudoxanthoma Elasticum was confirmed by skin lesions biopsy and for further systemic workup the patient was referred for evaluation by cardiology.




Figure 5 - Static white-on-white perimetry (A) right eye, (B) left eye (program 24-2, SITA standard, Humphrey Instruments, Dublin, CA, USA) disclosed no significant visual field lost

## ★ DISCUSSION ★

We report a case of acute transient myopia with shallowing of the anterior chamber and bilateral acute angle closure glaucoma in a patient with Pseudoxanthoma Elasticum, treated with sulphonamides for cystitis.

Sulphamethoxazole + trimethoprim (cotrimoxazole) is an antibiotic combination and is widely used for prophylaxis and treatment of numerous infections. The risk of an adverse reaction to a sulphonamide is approximately 3%<sup>[5]</sup>.

Transient myopia is a rare idiosyncratic reaction to systemic administration of sulphonamides. The myopic shift is usually bilateral and is usually completely reversible after discontinuation of the sulphonamide therapy. Various degrees of anterior chamber shallowing and angle narrowing have been reported. Controversy still exists regarding the exact mechanism by which sulphonamides induce iris-lens diaphragm displacement with acute myopia

and angle closure glaucoma. Most authors have assumed that ciliary body edema and anteriorly rotation secondary to a choroidal effusion was responsible for such observations. Due to relaxation of the zonules, the edema would lead to a thickening of the lens as well as to the displacement of the iris-lens diaphragm and consequent shallowing of the anterior chamber and angle closure glaucoma<sup>[6,7,8]</sup>. In any case, convincing explanations for the etiology of edema of the ciliary body are lacking, but it is suggested that this is related to the inhibition of carbonic anhydrase or an effect mediated by prostaglandins<sup>[9]</sup>. In this case, a displacement of the iris-lens diaphragm with shallowing of the anterior chamber was documented by Pentacam.

Cotrimoxazole points to a causative relation between these agents and the clinical picture seen in our patient. This patient was also medicated with tropium chloride which is a parasympatholytic drug that may dilate the pupil and place the susceptible patient at risk of an attack of angle-closure glaucoma. But the possible parasympatholytic effect of this drug in the eye does not explain the acute myopia and anterior displacement of the diaphragm iris-lens that occurred.

Pseudoxanthoma elasticum (PXE) is a complex heritable disorder at the genome/environment interface. It is a multisystemic heritable disorder with ectopic mineralization, and is characterized by progressive calcification and fragmentation of elastic fibers<sup>[10]</sup>. Typically the presentation includes characteristic skin findings, ocular involvement and cardiovascular problems. The classic forms of PXE are due to loss-of-function mutations in the *ABCC6* gene, which under physiologic conditions is expressed at high levels on the basolateral surface of the liver where it facilitates the transport of currently uncharacterized molecule(s) from hepatocytes to the circulation.

These molecules are postulated to serve physiologically as potent anti-mineralization factors, which under normal Ca/P homeostasis prevent precipitation of metastable calcium/phosphate complexes in the peripheral tissues<sup>[11]</sup>. The characteristic ocular sign, angioid streaks, results from degeneration and calcification of the elastic fibers of the retina leading to breaks in Bruch's membrane.

Although unlikely, the relationship between Pseudoxanthoma Elasticum and the development of anterior displacement of the lens-iris diaphragm with consequent myopic shift and shallowing of the anterior chamber cannot be completely ruled out. On the other hand one cannot exclude a possible predisposition in patients with Pseudoxanthoma Elasticum for ocular side effects of sulfonamides.

## ★ CONCLUSION ★

Anterior displacement of the lens iris-diaphragm with consequent myopic shift and shallowing of the anterior chamber is a rare idiosyncratic reaction to the action of sulfonamides. Although the mechanism is not fully understood, it has been postulated that there is a supraciliary choroidal effusion with consequent rotation of the ciliary body and zonular relaxation.

This is one of the few reported cases of an extremely rare sulphametoxazole reaction, in which was possible to document by Pentacam the anterior displacement of the diaphragm iris- lens.

Although unlikely, the relationship between Pseudoxanthoma Elasticum and this clinical picture cannot be completely ruled out.

This case highlights the importance of the ophthalmologist awareness of the sulfonamides and their derivatives adverse effects widely used in several diseases. Patients should also be informed about the importance of reporting changes in their vision when initiating therapy with such agents.

## ★ REFERENCES ★

- 1-Boissonnot L, Boissonnot M, Charles- Gervais C, Breux JP, Myopie aigue due à Indapamide. Presse Med 1986;15:802-3. (cross ref from: Krieg PH, Shipper I. Drug-induced ciliary body oedema: a new theory. Eye. 1996;10(Pt 1):121-6.)
- 2-Fan JT, Johnson DH, Burk RR. Transient myopia, angle-closure glaucoma and choroidal detachment after oral acetazolamide. Am J Ophthalmol 1993; 115:813-4. (cross ref from: Krieg PH, Shipper I. Drug-induced ciliary body oedema: a new theory. Eye. 1996;10(Pt 1):121-6.)
- 3-Postel EA, Assalian A, Epstein DL. Drug- induced transient myopia and angle-closure glaucoma associated with supraciliary choroidal effusion. Am J Ophthalmol 1996;122:110-12.
- 4-Spadoni VS, Pizzolo MM, Muniz CH, Melamed J, Fortes Filho JB. Bilateral angle- closure glaucoma induced by timolol and sulfamethoxazole combination: case report. Arq Bras Oftalmol. 2007 May-Jun;70(3):517-20.
- 5-Panday VA, Rhee DJ. Review of sulfonamide-induced acute myopia and acute bilateral angle-closure glaucoma. Compr Ophthalmol Update. 2007 Sep-Oct;8(5):271-6.
- 6-Bovino JA, Marcus DF. The mechanism of transient myopia induced by sulfonamide therapy. Am J Ophthalmol 1982;94:99-102. (cross ref Krieg PH, Shipper I. Drug-induced ciliary body oedema: a new theory. Eye.1996;10(Pt 1):121-6.)
- 7-Ryan EH, Jampol LM. Drug-induced acute transient myopia with retinal folds. Retina 1986;6:220-3.(cross ref 10. Krieg PH, Shipper I. Drug-induced ciliary body oedema: a new theory. Eye. 1996;10(Pt 1):121-6.)
- 8-Murihead JF, Scheie HG. Transient myopia after acetazolamide. Arch Ophthalmol 1960;63:315-8. (cross ref Krieg PH, Shipper I. Drug-induced ciliary body oedema: a new theory. Eye. 1996;10(Pt 1):121-6.)
- 9-Krieg PH, Shipper I. Drug-induced ciliary body oedema: a new theory. Eye. 1996;10(Pt 1):121-6.
- 10-Robert P. Finger, Peter Charbel Issa, Ladewig MS, Gatting C, Szliska C, Scholl HP, Holz FG. Pseudoxanthoma Elasticum: Genetics, Clinical Manifestations and Therapeutic Approaches. 2009;54(2):272-285.
- 11-Uitto J, Li Q, Jiang Q. Pseudoxanthoma elasticum – molecular genetics and putative pathomechanisms. J Invest Dermatol. 2010a; 130:661–670.
- 12-Waheeb S, Feldman F, Velos P, Pavlin CJ. Ultrasound biomicroscopic analysis of drug- induced bilateral angle-closure glaucoma associated with supraciliary choroidal effusion. Can J Ophthalmol. 2003 Jun;38(4):299-302.
- 13-Grinbaum A, Ashkenazi I, Gutman I, Blumenthal M. Suggested mechanism for acute transient myopia after sulfonamide treatment. Ann Ophthalmol. 1993 Jun;25(6):224-6.
- 14-Grinbaum A, Ashkenazi I, Avni I. Drug induced myopia associated with treatment for gynecological problems. Eur J Ophthalmol.1995 Apr-Jun;5(2) 136-8.
- 15-Ramos-Esteban JC, Goldberg S, Danias J Drug induced acute myopia with supraciliary choroidal effusion in a patient with Wegener's granulomatosis. Br J Ophthalmol .2002 May;86(5) 594-6.

.....  
Filipe FERREIRA

Centro Hospitalar e Universitário de Coimbra – PORTUGAL  
.....



.....  
**ACUTE ANGLE CLOSURE  
CRISIS AFTER ALBUTAMOL  
ADMINISTRATION**  
.....

**★ INTRODUCTION ★**

Acute angle closure crisis (AACC) is a new term that replaces the former “Acute angle closure glaucoma (AACG)” in patients who don’t present glaucoma criteria.

AACG is a major cause of blindness being the most frequent type in Asian countries<sup>[1]</sup>. About 33% cases of AACG are related with some type of medication<sup>[2]</sup>. Drugs can precipitate these episodes mainly by two mechanisms: mydriasis ( $\alpha_1$  adrenergic or anticholinergic) or ciliochoroidal effusion (sulfa-based and anticoagulants).  $B_2$  adrenergic agents like salbutamol, can also increase intraocular pressure (IOP) inducing transient trabecular meshwork closure and aqueous secretion.

## ★ CASE PRESENTATION ★

A 39-year-old woman was admitted in the emergency room (ER) complaining of acute bilateral visual loss, frontal headache and vomiting. The patient had history of asthma and did nebulized salbutamol in the morning.

Ophthalmic observation disclosed bilateral fixed, mid-dilated pupil, best correct visual acuity (BCVA) in the right eye (RE): hands movement at 2 meters and left eye (LE) : 1/10, anterior segment examination demonstrated bilateral conjunctival hyperemia, corneal edema, markedly shallow anterior chamber. IOP applanation method RE: 66 mmHg and LE : 64 mmHg. Ophthalmic past history was irrelevant and had a medical history of : asthma medicated with salbutamol 5mg/ml nebulization.

In the ER medical treatment was performed with brimonidine 0.2% 1 drop every 12 hours, pilocarpine 2% 1 drop every 5 minutes for 15 minutes, followed by 1 drop every 6 hours, dexametasone sodium phosphate 1mg/ml 1 drop every 2 hours and manitol 200mg/ml ev id.

After 6h the patient report improvement in visual acuity (VA) and was observed a decrease of the corneal edema, IOP dropped down to 22mmHg RE and 23 mmHg. Two peripheral iridotomies were performed with laser Nd :YAG OU. Twelve hours after therapeutic measures, the patient was without headache and BCVA was 2/10 bilaterally (OU). Anterior segment examination objected tyndall+, corneal edema, patent iridotomies at 11h and 2h RE and 11h and 8h LE and good deep anterior chambers (grade 2 Van Herick classification). Fundoscopy examination revealed vascular tortuosity, normal optic disc and a maintained retinal nerve fiber layer (Fig. 2).

Gonioscopy: grade II-III Shaffer classification. IOP decreased to 10mmHg OU (the patient was prescribed fluorometolone 0.1% 4 id and brimonidine 0.2% 2 id). Additional exams performed: Visual fields test (24-2 Humphrey perimetry) with Swedish Interactive Thresholding Algorithm (Fig. 3);- Optical Coherence Tomography (OCT) (Fig.4) and pachymetry RE:550µm, LE:560µm. No refraction error was found.

On 1-month follow up (without medication), BCVA was 10/10 OU, biomicroscopy : observation presented no cornea edema, an anterior chamber deepness of grade 3 in the Van Herick classification, no tyndall, and permeable iridotomies (Fig.1). Gonioscopy: was grade III Shaffer classification and IOP 7 mmHg OU.

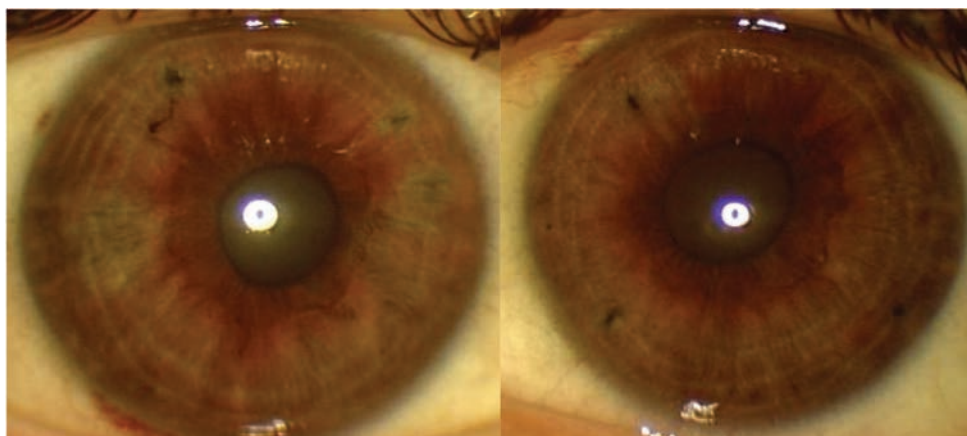


Fig. 1: Biomicroscopy OU

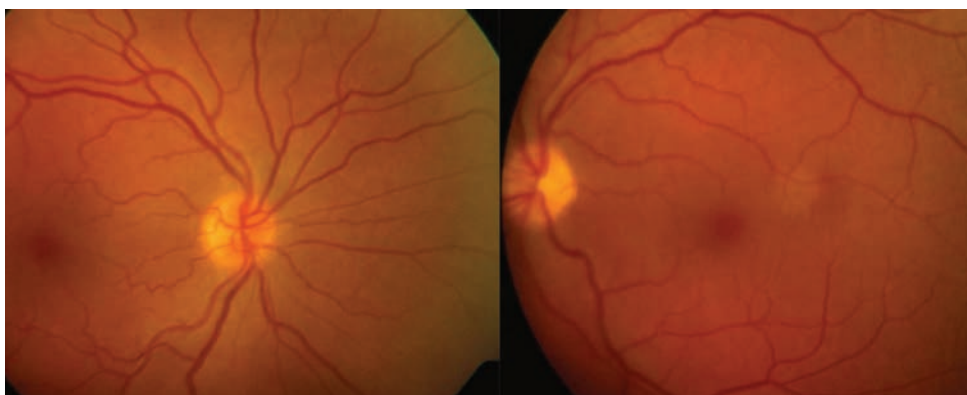


Fig. 2: Retinography OU

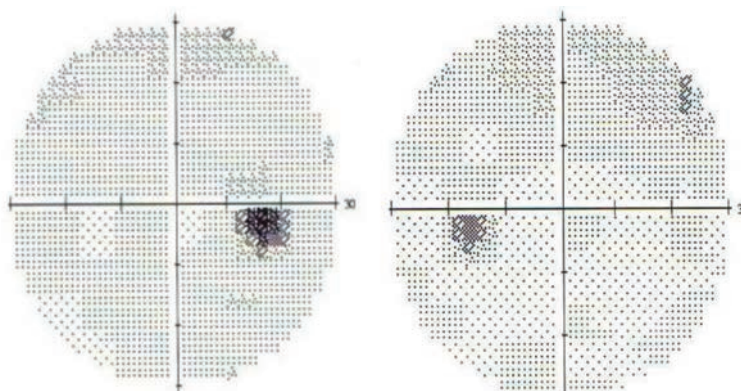


Fig. 3: 24-2 Humphrey perimetry

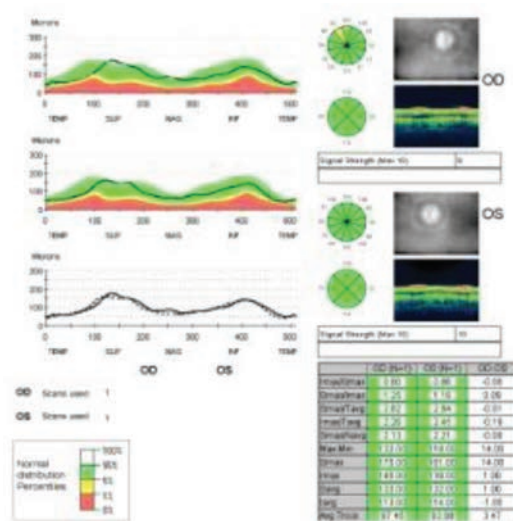


Fig. 4: OCT

## ★ DISCUSSION ★

AACG is a major cause of blindness, being the most frequent type of Glaucoma in Asian countries<sup>[1]</sup>.

There are some risk factors for AACG like : hypermetropia, narrow angle, shallow anterior chamber, female gender and family history.

Some drugs like adrenergic agonists, anticholinergics, tricyclic antidepressants, sulfa- based and anticoagulants may predispose to the occurrence of AACG<sup>[3-5]</sup>.

The adrenergic agents, especially  $\beta_2$  adrenergic, like salbutamol, are used in nebulization to promote bronchodilatation in patients with asthma or chronic obstructive pulmonary disease. These drugs can increase IOP and induce angle closure by several mechanisms: stimulating ciliary body  $\beta_2$  adrenergic receptors that promote aqueous secretion, narrowing of anterior chamber angle and promoting mydriasis. At the eye level, its adverse effects are due local (conjunctiva) and systemic absorption<sup>[6-7]</sup>.

In the majority of cases described in the literature, as this case, patient's don't have history and criteria of Glaucoma/Ocular hypertension, so it's more correct the term AACG. The incorrect application of masks and the high pharmacological dosages of the inhaled drugs facilitate the development of AACG<sup>[6,7]</sup>.

By our research in Pubmed (Key words), there are no cases of AACG/AACG with salbutamol individual administration, the authors found only a case described by Ro et al after use of albuterol<sup>[7]</sup>. There are some cases of AACG described after using a combination of ipratropium bromide and salbutamol<sup>[6,8,9]</sup>. These adverse reactions are more frequent with combinations versus individual administration.

Recognition of the situation and a rapid intervention in our case allowed a prompt recovery, with medical and laser therapy.



## ★ CONCLUSION ★

The occurrence of bilateral AACC after use of some medication is a rare but dangerous situation. When quickly recognized and treated, the results are great.

Increase awareness by health care providers of potential acute angle closure after salbutamol may decrease incidence of this complication. The adequate fitting of the mask and the use of therapeutic doses can minimize ocular deposition of nebulized medication and these adverse effects.

## ★ REFERENCES ★

- 1 Ramesh S, Maw C, Sutton CJ, Gandhewar JR, Kelly SP (2005) Ethnic aspects of acute primary angle closure in a UK multicultural conurbation. *Eye* 19:1271.
- 2 Lachkar Y and Walid Bouassida W (2007) Drug-induced acute angle closure glaucoma. *Curr. Opin Ophthalmol* 18:129-133.
- 3 Tripathi RC, Tripathi BJ, Haggerty C (2003) Drug-induced Glaucomas : mechanism and management. *Drug Saf* 26:749-767.
- 4 Banta JT, Hoffman K, Budenz DL, Ceballos E, Greenfield DS (2001) Presumed topiramate-induced bilateral acute angle-closure glaucoma. *Am J Ophthalmol* 132:112-114.
- 5 Cruciani F, Lorenzatti M, Nazzarro V, Abdolrahimzadeh S (2009) Bilateral acute angle closure glaucoma and myopia induced by topiramate. *Clin Ter* 160:215-216.
- 6 Hall SK (1994) Acute angle-closure glaucoma as a complication of combined beta- agonist and ipratropium bromide therapy in the emergency department. *Ann Emerg Med* 23: 884-887.
- 7 Rho DS (2000) Acute angle-closure glaucoma after albuterol nebuliser treatment. *Am J Ophthalmol* 130: 123-124.
- 8 De Saint M, Bourcier T, Borderie V, Moldovan M, Touzeau O, Laroche L (2000) Glaucome aigu par fermeture de l'angle après un traitement par aerosols de bromure d' ipratropium et de salbutamol. *J. Fr. Ophtalmol* 23: 603-605.
- 9 Reuser T, Flanagan DW, Borland C, Bannerjee DK (1992) Acute angle closure glaucoma occurring after nebulized bronchodilator treatment with ipratropium bromide and salbutamol. *J R Soc Med* 85:499-500.

Javier GARCIA BELLA

Hospital Clinico San Carlos (C/ Profesor

Martín Lagos S/N, 28040, MADRID) – **SPAIN**



.....

## CYP1B1 GENE MUTATIONS IN THREE MEMBERS WITH PRIMARY CONGENITAL GLAUCOMA OF A SPANISH FAMILY : PHENOTYPIC AND FUNCTIONAL VARIABILITY

.....

### ★ INTRODUCTION ★

Primary congenital glaucoma (PCG) is the most common childhood glaucoma and is a significant cause of visual loss in children. Autosomal recessive inheritance with incomplete penetrance is well documented for this disease. Sporadic cases have also been classically described, but it cannot be ruled out that some of them are also recessively inherited because this type of genetic transmission is particularly difficult to assess in families where the proband has no siblings. Frequently, developmental abnormalities of the trabecular meshwork (trabeculodysgenesis) are responsible for remarkably increased aqueous outflow resistance, elevated intraocular pressure and optic nerve degeneration associated with this disease. PCG is usually diagnosed in the neonatal or infantile period, generally before the age of 3. Age-based classifications are clinically useful, but they are arbitrary. Its incidence has been reported to range from 1/1,250 to 1/2,500 births in inbred Slovakian Gypsy<sup>(1)</sup> and Saudi Arabian populations<sup>(2)</sup>, respectively, to between 1/5,000 and 1/10,000 in Western countries<sup>(3)</sup>. In Spain a study of 1,124,654 consecutive births reported 2.85 PCG/100,000 births<sup>(4)</sup>. Linkage analyses have identified four PCG loci: GLC3A (2p21), GLC3B (1p36), GLC3C (14q24.3) and GLC3D (14q24.3). The last two loci are adjacent but do not overlap. To date, only two glaucoma genes have been identified. Mutations in CYP1B1, situated at GLC3A, are the predominant known genetic cause of this type of glaucoma in different worldwide populations.

To date, analysis of the genotype-phenotype relationship clearly shows that CYP1B1 genotypes influence the clinical severity of PCG. Particularly interesting are the null genotypes, which are associated with very early diagnosis, quite frequently at birth, and more trabeculectomies than patients with other genotypes.

We present a case report that emphasizes the participation of CYP1B1 gene in GCP and shows incomplete penetrance with variable expressivity. The same CYP1B1 gene mutations can modulate the phenotype varying the onset of the disease and evolution.

## ★ CASE REPORT ★

We report three siblings diagnosed with PCG for a total of 7. There had been genetic study of CYP1B1. To determine the presence of mutation, the gene's coding regions were amplified by PCR and were processed through automated sequencer, obtaining genomic DNA from peripheral blood leukocytes. This analysis confirmed the presence of two mutations R355-x69/T404-x38 (heterozygous compound). The study of healthy parents (non-consanguineous marriage) revealed the presence of the mutation T404-x38 and R355-x69 in the mother and father respectively. Two of the 4 healthy siblings present only one mutation (R355-x69). There is great variability among the 3 patients who developed PCG (Fig 1).

▶ **Patient 1** : 13-year-old male who was diagnosed with PCG at the age of 5 years and debuted with initial IOP (IOP) of 24 and 26 mm Hg in the right eye (RE) and left (LE) respectively, that required treatment with topical prostaglandins (latanoprost, hypotensive drops). Currently IOP was 12-14 mmHg in both eyes (BE) without requiring surgery. Actual examination reveals a visual acuity (VA) of 1 in BE without correction (Snellen scale), no strabismus or alterations in the anterior segment and ophthalmoscopy reveals good optic nerve (0.5 both eyes) and Octopus Visual Field (TOP strategy) showed no significant defects of glaucoma (RE: MD 0.0, MF 0.6, LE: MD 1.4, LV 3.6).

▶ **Patient 2** : 9-year-old girl, diagnosed of bilateral PCG at birth. This patient required an initial bilateral surgery (trabeculectomy) (7days old) and a second surgery 8 months later. Pediatric Ahmed valve was implanted in the superior temporal area in BE. The RE was controlled with topical drops without new surgeries (Bimatoprost eye drops). In LE, trabeculectomy was performed 7 years after the diagnosis. Actual examination reveals an IOP of 14mmHg in RE and 25-28 mmHg in LE so a new surgery will be programmed to control IOP of the right eye. BCVA is 0.4 in RE (+4.50 -4 to 30 °) and 0.2 in LE (+4.50-4.00 to 120) (Snellen) with diffuse defects in the Octopus visual field (RE: MD 6.1 LV 8.6; LE: MD 6.1, LV 6.5).

▶ **Patient 3** : 7 years old male. He was diagnosed with bilateral PCG (4 days old) and treated with bilateral trabeculectomy. One month later, a second intervention was required in BE. Pediatric Ahmed valve implant was put in the superior temporal quadrant. At the same time RE showed good control of IOP with topical hypotensive treatment (beta-blocker eye drops) without further surgery. However the poor control of LE, required a new adult Ahmed valve positioned in the superior nasal quadrant and the withdrawal of the previous valve. And 3 years later a trabeculectomy was required. Actually, IOP was 22 mmHg in both eyes treated with drops (beta-blocker and brinzolamide).

## ★ DISCUSSION ★

The PCG was considered a sporadic disease, but advances in genetic studies of glaucoma in recent years show otherwise. This is a genetically heterogeneous disease and CYP1B1 gene is the most frequent genetic factor<sup>(1,4)</sup>.

The PCG is mainly characterized by an alteration of the iridocorneal angle and more specifically of the trabecular meshwork that interferes the normal out-flow of aqueous humor with consequent elevation of intraocular pressure. The protein synthesized from CYP1B1, is part of the cytochrome P450 superfamily and plays a central role in the development of ocular structures involved in the drainage of aqueous humor due to its enzymatic action monooxygenase<sup>(5)</sup>. In the presence of mutation there is a clear decrease in enzyme activity with a significant loss of function.

The incidence of mutation between the affections shows wide geographical variation. With a very different frequency, including 10% in Mexico, 20% in Indonesia and Japan, 40% in Turkey, 50% in Brazil and even 100% in Saudi Arabia<sup>(6,7,8,9)</sup>. In Spain described an incidence of mutation around 34%<sup>(1)</sup>.

The CYP1B1 gene has been associated with GLC3A locus (2p21) and its inheritance is an autosomal recessive. The presence of CYP1B1 mutation was described in affected subjects of PCG in a very heterogeneous form (homozygous or heterozygous compound) although this behavior is not typical of recessive inheritance<sup>(10)</sup>. This variability is an important detail when developing genetic counseling<sup>(11)</sup>.

Strictly, the heterozygous mutation would not explain the presence of disease following the reasoning of recessive inheritance. These cases suggest others not yet detected locus or even the involvement of other genes that participates in the anterior segment development. Several studies were reported of PCG in which there are two variants of CYP1B1 heterozygous mutation with a FOXC1 gene mutation.<sup>(12)</sup>

Evidently the influence and involvement of modifier genes or environmental factors may have an additional effect on the functional loss of CYP1B1. However harder work is required to understand this mechanism<sup>(2)</sup>.

Regarding the case report, there are several studies that attempt to correlate the presentation of the disease with CYP1B1 gene mutation. Greater severity was observed in mutated cases, and more in those who carried homozygous. Earlier age at diagnosis was described in mutated and higher intraocular pressure at baseline. Similarly, more number of surgeries were required to control IOP and worst prognosis<sup>(4)</sup>. Our experience has also allowed us to observe this negative influence on the prognosis of CYP1B1 PCG, however this case report shows a huge disparity between the three children suffering from the same family carrying the same mutation reflecting the great variability genotype – phenotype.

There are certain mutations that are associated with worse prognosis <sup>(2)</sup>, for example the mutation found in this family, R355X. This mutation was associated with a worse outcome and increased risk of blindness.

Participation of CYP1B1 was described in other diseases : chronic open-angle glaucoma (COAG) and juvenile glaucoma. There is an hypothesis that shows the differences in levels of CYP1B1 enzyme activity might be correlated with different phenotypes of glaucoma. The PCG appears if there is a severe absence of the enzyme's catalytic activity and moderate or mild in cases of COAG and juvenile glaucoma <sup>(11)</sup>. But this theory must be clarified. It's difficult to explain why the presence of the same mutation is associated with so different clinical evolution.

Finally the clinical utility of genetic studies in the GCP is undeniable. These analyses facilitate early diagnosis and performing genetic counseling, however we still consider this disease as little predictable.

Further studies are needed to clarify that other factors may influence the severity of the course of disease with the presence of the same mutation.

## ★ CONCLUSION ★

In conclusion, our case report demonstrates the relationship of the presence of the mutation CYP1B1 with GCP and this great clinical variability must be considered. The importance of a detailed genetic study of the parents and adequate genetic counseling were remarked.

## ★ REFERENCES ★

1. CYP1B1 mutations in Spanish patients with primary congenital glaucoma: phenotypic and functional variability. Campos-Mollo E, López-Garrido MP, Blanco-Marchite C, Garcia-Feijó J, Peralta J, Belmonte-Martinez J, Añuso C, Escribano J. Mol Vis. 2009;15:417-31.
2. Tanwar M, Dada T, Sihota R, Dada R. Identification of four novel cytochrome P4501B1 mutations (p.I94X, p.H279D, p.Q340H, and p.K433K) in primary congenital glaucoma patients. Mol Vis. 2009 Dec 30;15: 2926-37.
3. Vincent A, Billingsley G, Priston M, Williams-Lyn D, Sutherland J, Glaser T, Oliver E, Walter Ma, Heathcote G, Levin A, Heon E. Phenotypic heterogeneity of CYP1B1: mutations in a patient with Peters' anomaly. J Med Genet 2001; 38:324-6.
4. Hollander Da, Sarfarazi M, Stoilov I, Wood IS, Fredrick DR, Alvarado JA. Genotype and phenotype correlations in congenital glaucoma. Trans Am Ophthalmol Soc 2006; 104: 183-95.
5. Schwartzman ML, Masferrer J, Dunn MW, McGiff JC, Abracham NG. Cytochrome P450, drug metabolizing enzymes and arachidonic acid metabolism in bovine ocular tissues. Curr Eye Res 1987; 6, 623-30.
6. Zenteno JC, Hernandez-Merino E, Mejia-Lopez H, Matias- Florentino M, Michel N, Elizondo-Olascoaga C, Korder-Ortega V, Casab-Rueda H, Garcia- Ortiz JE. Contribution of CYP 1B1 mutations and founder effect to primary congenital glaucoma in Mexico. J Glaucoma 2008; 17: 189-92.
7. Sitorus R, Ardjo SM, Lorenz B, Preising M. CYP1B1 gene analysis in primary congenital glaucoma in Indonesian and European patients. J Med Genet 2003; 40: e9.
8. Batiyeva S, Marfanu G, Gonzalez-Angulo O, Gonzalez-Duarte R. Mutational screening of CYP1B1 in Turkish PCG families and functional analyses of newly detected mutations. Mol Vis 2007; 13:1458-68.
9. Stoilov IR, Costa VP, Vasconcellos JP, Melo MB, Betinjane AJ, Carani JC, Oltromogge EV, Sarfarazi M. Molecular genetics of primary congenital glaucoma in Brazil. Invest Ophthalmol Vis Sci 2002; 43:1820-7.
10. Sarfarazi M, Akarsu AN, Hossain A, Turacli ME, Aktan SG, Barsoum-Homsu M, Chevrette L, Saqli BS. Assignment of a Locus (GLC3A) for primary congenital glaucoma (Buphtalmos) to 2p21 and evidence for genetic heterogeneity. Genomics 1995;30:171-7.
11. López-Garrido MP, Blanco-Marchite C, Sánchez-Sánchez F, López-Sánchez E, Chaqués-Alepuz V, Campos-Mollo E, Salinas-Sánchez AS, Escribano J. Functional analysis of CYP1B1 mutations and association of heterozygous hypomorphic alleles with primary open-angle glaucoma. Clin Genet. 2010 Jan;77(1):70-8.
12. Chakrabarti S, Kaur K, Rao KN, Mandal AK, Kaur I, Parikh RS, Thomas R. The transcription factor gene FOXC1 exhibits a limited role in primary congenital glaucoma. Invest Ophthalmol Vis Sci 2009; 50: 75-83.

## ★ FIGURES ★

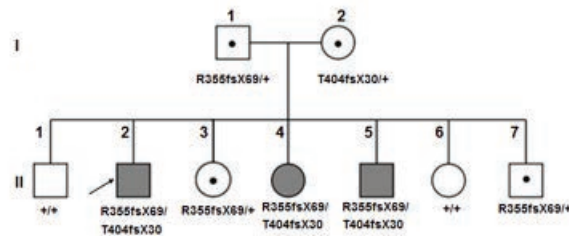


Figure 1. Pedigrees of Spanish family of our case report, with CYP1B1 gene mutations. Genotypes are indicated below the symbols. Grey symbols indicate PCG and arrow shows Juvenile glaucoma. Points refer healthy carriers.

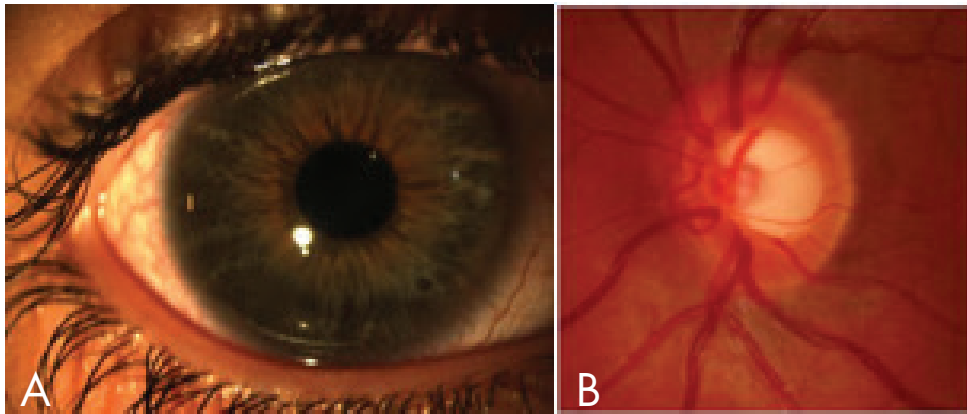


Figure 2. Biomicroscopy and ophthalmoscopy of case 1 (13 years old) reveals transparent cornea without estriae of Haab.

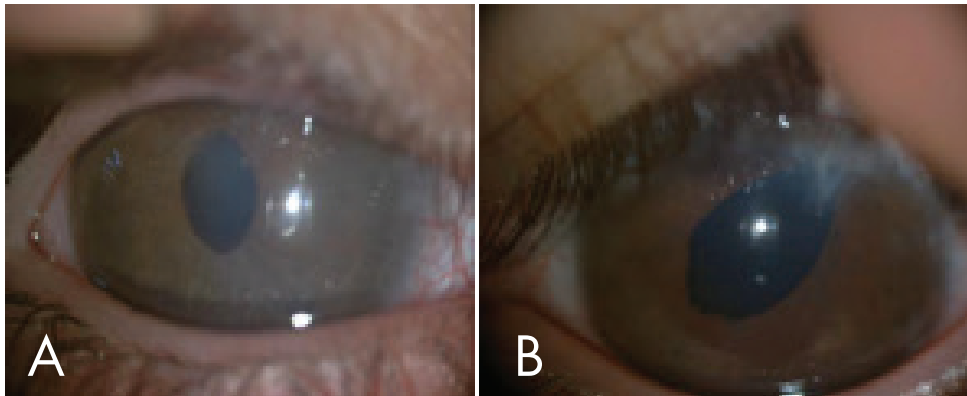


Figure 3. Case 2, corneal opacity and peripheral leucomas are observed in both eyes. Biomicroscopy of right eye (A) and left eye (B).

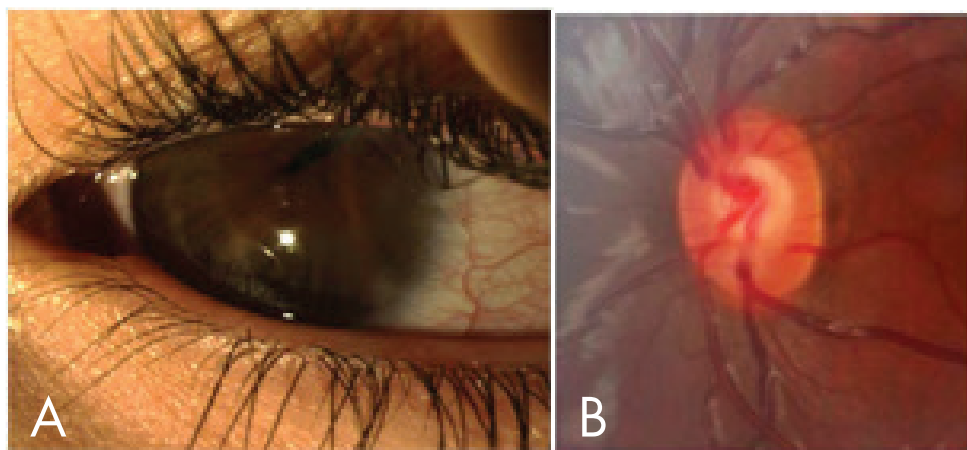


Figure 4. Biomicroscopy (A) y ophthalmoscopy (B) of the case 3 (7 years old). Corneal opacity and desviation of the pupil are observed.



.....  
Claudia BACALHAU

Centro Hospitalar de Setubal – PORTUGAL  
.....



.....  
**EYES AND DEVICES - A  
BILATERAL REFRACTORY  
GLAUCOMA CASE REPORT**  
.....

**★ INTRODUCTION ★**

We classify a patient as having “refractory glaucoma” by the following criteria : IOP>21 mmHg despite maximal antiglaucomatous medication, previously failed surgical treatment, or a combination of both. In some cases, not tolerable ocular symptoms related to topical medications difficult an aggressive medical strategy, and the step to other treatments must be done quicker. Trabeculectomy remains the gold standard surgical procedure for POAG (primary open angle glaucoma) but aqueous drainage devices have now assumed an important role as a safe surgical option, both as a primary choice and as a secondary or even tertiary procedure, when others have failed. We present a bilateral refractory glaucoma clinical case in a middle age patient submitted to multiple surgical procedures.

## ★ CASE REPORT ★

Female patient, 45 years old, followed by our Glaucoma Department since 5 years ago. She had a previous diagnosis of bilateral primary open angle glaucoma (made 3 years before) and was under topical therapy with a prostaglandin analogue. She was facing some described side effects of topical prostaglandin analogues, specially an accentuated conjunctival hyperemia, and this was her biggest concern so far. She had no other health conditions at this time and her familial history was not relevant.

At her first appointment we observed a 360° open angle OD and OS and a pachymetry of 538µm OD and 544µm OS. Intra-ocular pressure (IOP) was measured by Goldmann applanation tonometer and was 22 mmHg OD and 20 mmHg OS. Fundoscopy revealed pathologic glaucomatous optic discs, with neuroretinal rim thinning and optic disc excavation of 0,7 OD and 0,5 OS. We decided to continue a medical approach, changing the topical therapy to Timolol+Dorzolamide twice-a-day. Automated Static perimetry did not show significant loss of visual field (Figure 1 – examination 1).

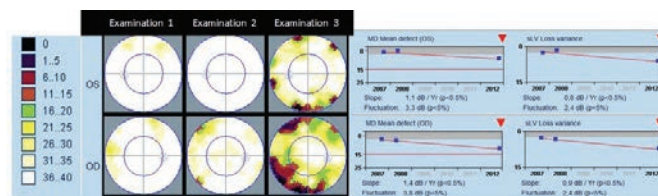


Figure 1 – Automated Static Perimetry and evaluation of tendency

Three months later the IOP had increased to 33 mmHg OD and the patient was still complaining about ocular hyperemia and discomfort. We decided to re-introduce a prostaglandin analogue (Latanoprost) in addition to conservative free lubrication drops, but IOP remained high. It was decided to perform a trabeculectomy on the right eye but at this time the patient was diagnosed with breast cancer and started chemotherapy. Although this situation she decided to undergo trabeculectomy, so she would not have to use so many drops and topical side effects would become more tolerable. There were no surgical complications and she remained with topical timolol. IOP was stable during one year, with no visual field significant progression (Figure 1 – examination 2). At this time we registered an increased IOP on the left eye (36 mmHg) and decided to also perform a trabeculectomy. The cancer situation was not still resolved and was under treatment and surgery planning and the patient was both renitent to excessive topical therapies and ocular discomfort. She remained with topical timolol after surgery. After 9 months of good tensional control the right eye IOP increased to 34 mmHg, even though there was a good filtration bubble. Since the patient was not receptive to more topical therapies the implantation of an Ahmed Valve was the choice procedure, and once again the post-surgical result was very good, with 16 mmHg achieved short time after surgery. Later that year the left eye also developed an increased and sustained IOP (>30 mmHg at three different measurements) and meanwhile right eye IOP remained very well controlled. We perform another surgical procedure: Ahmed Valve implantation on the left eye. The patient was extremely satisfied with her right eye situation so

she was really determined to undergo similar procedure on the other eye. The Ahmed Valve implantation on the left eye had no complications. Nine months later the right eye IOP started to increase again, to values up to 28 mmHg. We observed that the Valve's tube had a fibrin obstruction and surgical recanalization was successfully made. Nevertheless, the IOP remained high and the patient refused other medical therapies than topical timolol. Oral acetazolamide was tried, in a 500mg twice-a-day protocol, but IOP didn't drop as expected. At this time, while we were discussing therapeutic options with the patient, she started to complain about visual acuity difficulties on the right eye and the left eye IOP, which had been controlled so far, also increased to pre-surgical values. BCVA were 7/10 OD and 8/10 OS.

It was decided to perform another surgical procedure on the right eye, with implantation of mini-shunt express®, which occurred without complications. IOP dropped to 18 mmHg and sustained. Left eye IOP remained high and attended to the good result of the mini-shunt implantation in the right eye we decided to perform similar procedure to the left eye.

We have now 1 year follow-up since last surgical procedure and the patient remains with topical timolol. IOP was 16 mmHg both eyes in the last appointment. BCVA remains stable. The last perimetry shows slightly progression since the first examination, mainly OD (Figure 1). Optic discs OCT also shows the advanced glaucomatous damage (Figure 2).

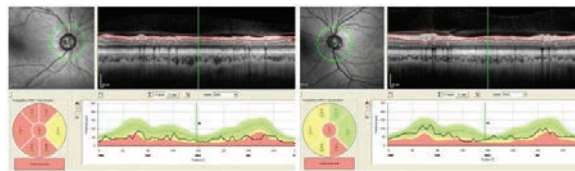


Figure 2 – Coherence Optic Tomography

Anterior segment photographs show the actual aspect of both eyes, with 4 devices implanted (Figure 3).

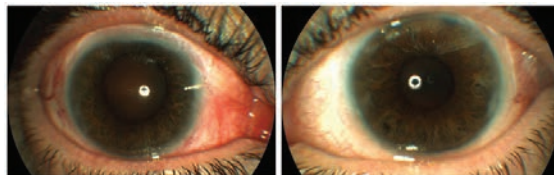


Figure 3 – Actual photographs from both eyes

## ★ DISCUSSION ★

This case still represents a challenge to us. When we started to follow this patient she was a 40 year-old women already with glaucomatous damage, so we established a lower target IOP. Her intolerance to most of topical therapies made that approach alone not suitable, and the choice for a surgical approach was made. The surgical procedures had no complications, besides the tube obstruction. Nevertheless, IOP control didn't last as expected, with functional failure of both trabeculectomies and Ahmed Valve implantations. Souza et al<sup>[2]</sup> in a retrospective study had 50% successful Ahmed Valve implantation after 5 years of follow up and prior glaucoma surgery was associated with higher failure rates, which was our situation. Anand et al<sup>[1]</sup> concluded that second glaucoma implant may effectively lower IOP in eyes with refractory glaucoma and these evidences were the support to decide for the mini- shunts implantations.

## ★ CONCLUSION ★

This bilateral refractory glaucoma case became a difficult case to manage because the patient remained non-receptive to more medical therapies. The mini-shunt implantations were the third IOP lowering procedure performed to each eye, in just 5 years of follow up. IOP is now controlled but we don't know for how long and how many invasive procedures will still be necessary for this patient. As she is still a young patient, she will have a long term glaucomatous eyes and this is another reason to control disease progression very carefully.

## ★ REFERENCES ★

- [1] Anand A, Tello C, Sidoti P, Ritch R, Liebmann J: *Sequential Glaucoma Implants in Refractory Glaucoma*. American Journal of Ophthalmology Volume 149, Issue 1, January 2010, Pages 95-101.
- [2] Souza C, Tran D, Loman J, Law S, Coleman A, Caprioli J: *Long-term Outcomes of Ahmed Glaucoma Valve Implantation in Refractory Glaucomas*. American Journal of Ophthalmology Volume 144, Issue 6, December 2007, Pages 893-900.
- [3] JC Das, Z Chaudhuri, P Sharma and S Bhomaj: *The Ahmed Glaucoma Valve in Refractory Glaucoma: experiences in Indian Eyes*. Eye (2005) 19, 183- 190.
- [4] Kitazawa Y, Yamamoto T, Sawada A, Hagiwara Y: *Surgery for refractory glaucoma*. Australian and New Zealand Journal of Ophthalmology 1996; 24(4).
- [5] Aljazzaf A, Abdelmoaty S, Behbehani A, Abdulmuez A, Aljazzaf H: *The Outcome of the Ahmad Glaucoma Valve implantation for refractory glaucoma in Kuwait*. Saudi Journal of Ophthalmology – Article in Press.
- [6] Nguyen Q: *Primary surgical management refractory glaucoma: tubes as initial surgery*. Curr Opin Ophthalmol. 2009 Mar;20(2):122-5.



.....

**TENON'S CYST TREATMENT BY  
NEEDLE BLEB REVISION WITH  
BEVACIZUMAB. EVALUATION OF  
THE BLEB BY OPTICAL COHERENCE  
TOMOGRAPHY**

.....

★ **INTRODUCTION** ★

The main reason for failure in glaucoma surgery is the development of fibrosis in the conjunctiva and episclera due to fibroblast proliferation and collagen deposition at the site of the filtration bleb. This excessive postoperative scarring of the conjunctiva and Tenon at the sclerostomy site leads to poor postoperative intraocular pressure control with the consequent progression of glaucoma. The use of adjunctive antifibrotic agents such as 5-fluorouracil (5-FU) and mitomycin C (MMC) has significantly improved the success rate of filtration surgery. However, these agents can cause complications such as severe postoperative hypotony, bleb leaks, and endophthalmitis.

Vascular endothelial growth factor (VEGF) is best known as an endothelial growth and permeability factor. Bevacizumab (Avastin; Genentech, San Francisco, CA) is a humanized, non-selective monoclonal antibody against VEGF. It has been approved by the U.S. Food and Drug Administration as a treatment for widespread metastatic colorectal cancer, as well as breast cancer.

Several case reports have described the use of subconjunctival bevacizumab injections for improving success and limiting scar tissue formation after trabeculectomy filtration surgery.

In this study we describe the use of bevacizumab injections and bleb needling for the treatment of encapsulated filtering bleb also called Tenon's capsule cyst and the use of Optical Coherence Tomography as a promising tool to analyze intrableb structures and to establish the relationship between features of bleb morphology and bleb function.

## ★ CASE REPORT ★

We present the case of a 65 year old woman with uncontrolled POAG on maximal medical therapy. Personal history filtration surgery with antimetabolic agents ten years ago. Because of the high risk of another failed surgery and after signing full informed consent, the patient underwent trabeculectomy and injection of 1.25 mg / 0.1 ml Bevacizumab into the upper subconjunctival space at the end of the procedure.

One month after surgery, we found an IOP of 25 mm Hg and the presence of a Tenon's capsule cyst on slit lamp examination. Optical Coherence Tomography reveals a bleb with very thin, homogeneous and highly hyperreflective walls with a large hyporeflective central bleb cavity (1600 microns). (Figure 1).

After signing informed consent, bleb needling and injection of 1.25 mg/0.1 ml bevacizumab is performed.

Seven days after the procedure, the bleb was noted to be more diffuse and with a decrease in surface vascularization. The IOP was 12 mm Hg without hypotensive medication. A smaller hyporeflective central bleb cavity (630 microns) with thickening and decreased reflectivity of the walls is evidenced by OCT. (Figure 2).

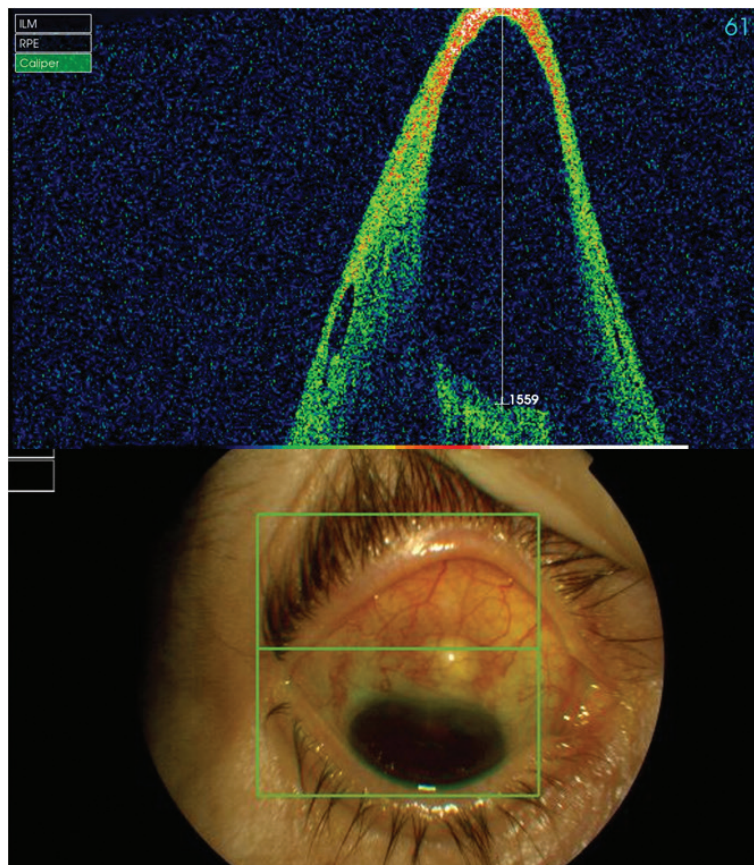


Figure 1: Tenon's cyst one month after surgery. OCT: bleb with very thin, homogeneous and highly hyperreflective walls with a large hyporeflective central bleb cavity

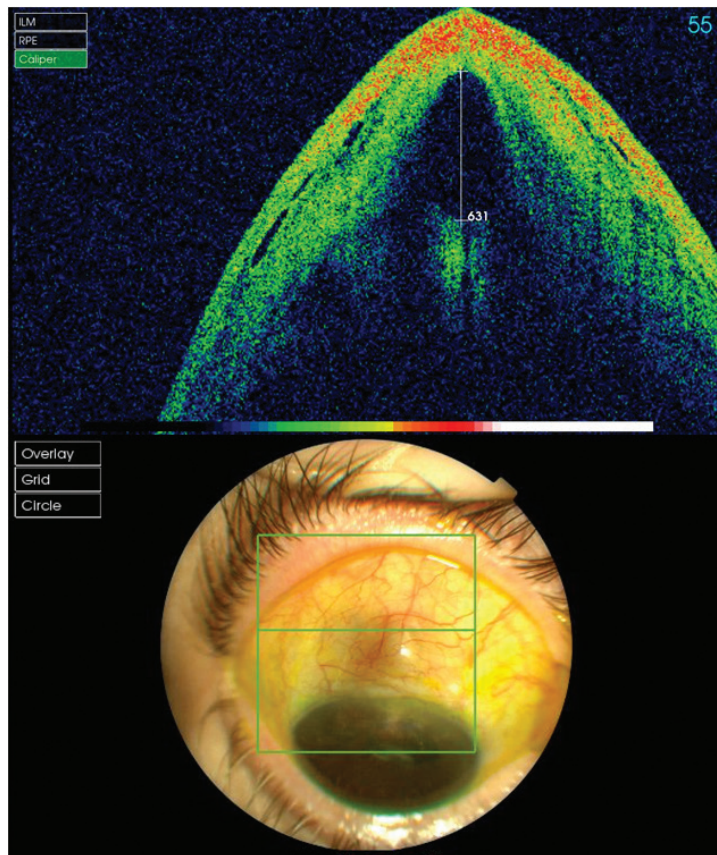


Figure 2: Evolution of cyst 7 days after needling and bevacizumab. OCT: A smaller hyporeflective central bleb cavity with thickening and decreased reflectivity of the walls

Three months after needling, the patient presents flattening of the cyst with a more diffuse bleb and a IOP of 15 mm Hg without treatment. OCT shows multiple large hyporeflective spaces located within the bleb wall with a small bleb cavity instead of a large central bleb cavity. (Figure 3).

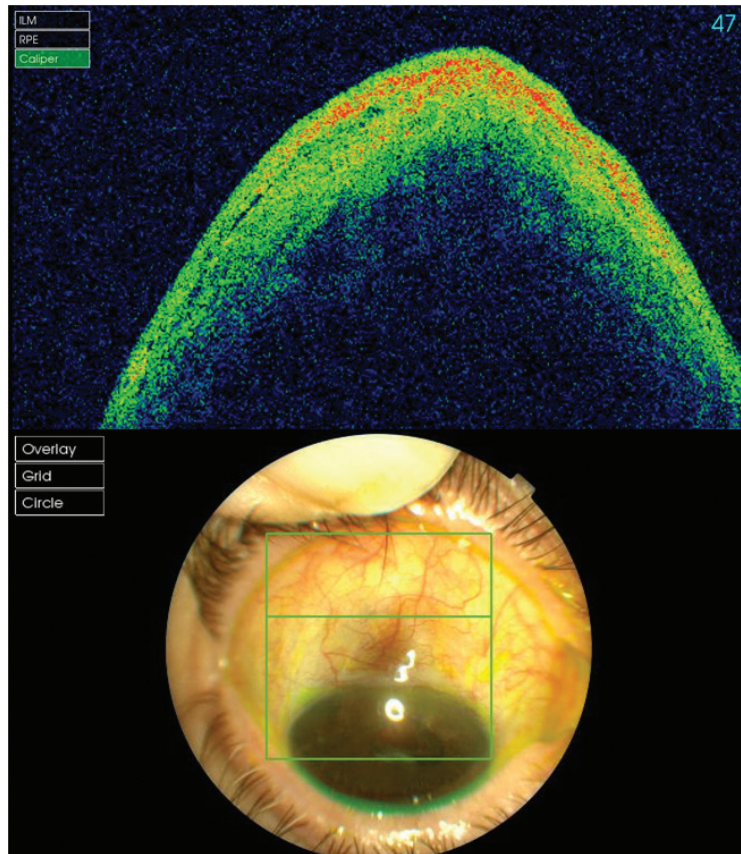


Figure 3: Three months post-needling, functioning bleb, complete flattening of the cyst with thick and hyporeflective walls with multiple microcysts within the bleb wall.

One year after surgery, the patient remains well controlled without hypotensive glaucoma drugs.



## ★ DISCUSSION ★

The main cause of filtration failure is the excessive postoperative scarring of the fistula tract that occurs at subconjunctival and sub-Tenon's space. Recent studies<sup>(1)</sup> have suggested the possibility that the vascular endothelial growth factor (VEGF) plays a central role in the subconjunctival healing process that appears after glaucoma surgery.

VEGF not only stimulates vasculogenesis but seems to have a direct effect on tenon fibroblasts, key cells in the healing process<sup>(2)</sup>. In vitro, VEGF binds to receptors on the membrane of fibroblast stimulating their activity and proliferation.

Anti-angiogenic drugs like Bevacizumab have proven to be antiscarring agents in experimental models of Trabeculectomy<sup>(3)</sup> and have been reported to be useful in the treatment of post-operative failure.<sup>(4)</sup>

Our patient represents a case of high risk of failure of the surgery due to previous failed surgery and the chronic use of antiglaucomatous drugs. However, the use of anti-angiogenic drugs at the same time of the surgery with a second dose a month later seems to have finally achieved the success.

The OCT has proved to be useful in the evaluation of the morphology and the function of subconjunctival filtering blebs. It has provided interesting information about the close relationship between the structural and functional characteristics of the filtering bleb.<sup>(7)</sup>

Functioning blebs have most frequently and statistically significantly thicker, low reflectivity and heterogeneous walls with hyporeflective spaces located within the bleb walls.<sup>(6)</sup>

These findings would be the representation of a laxer connective tissue and with little fibrosis. In addition, the OCT allows us to follow up the evolution of blebs making measurements of the hyporeflective central space and of the thickness of the bleb walls.<sup>(7,8)</sup>

## ★ CONCLUSION ★

We believe that our case could be a representative example of the antiscarring effect that the antiangiogenic drugs seem to have. The images shown by Optical Coherence Tomography are consistent with those described in the literature and show the usefulness of this instrument in the analysis of filtering blebs morphology.

## ★ REFERENCES ★

- 1) How A, Chua JL, Charlton A, et al. (2010) : Combined treatment with bevacizumab and 5- fluorouracil attenuates the postoperative scarring response after experimental glaucoma filtration surgery. Invest Ophthalmol Vis Sci. 51(2):928-32
- 2) Zhongqiu Li, Tine Van Bergen, Sara Van de Veire, et al. (2009) : Inhibition of Vascular Endothelial Growth Factor Reduces Scar Formation after Glaucoma Filtration Surgery. Invest Ophthalmol Vis Sci. 50(11):5217-25.
- 3) Memarzadeh F, Varma R, Lin LT, et al. (2009) : Postoperative use of bevacizumab as an antifibrotic agent in glaucoma filtration surgery in the rabbit. Invest Ophthalmol Vis Sci. 50(7):3233-7.
- 4) Malik Y Kahook; Joel S Schuman; Robert J Noecker (2006) : Needle Bleb Revision of Encapsulated Filtering Bleb With Bevacizumab Ophthalmic Surgery, Lasers and Imaging; Mar/Apr ; 37, 2;
- 5) Keisuke Kawana, Takahiro Kiuchi, Yoshiaki Yasuno, et al. (2009): Evaluation of Trabeculectomy Blebs Using 3-Dimensional Cornea and Anterior Segment Optical Coherence Tomography. Ophthalmology. 116(5):848-5
- 6) Leung CK, Yick DW, Kwong YY, et al. (2007) : Analysis of bleb morphology after trabeculectomy with Visante anterior segment optical coherence tomography. Br J Ophthalmol 91:340-4.
- 7) Singh M, Chew PT, Friedman DS, et al.(2007) : Imaging of trabeculectomy blebs using anterior segment optical coherence tomography. Ophthalmology. 114(1):47-53.
- 8) Zhang Y, Wu Q, Zhang M, et al. (2008) : Evaluating subconjunctival bleb function after trabeculectomy using slit-lamp optical coherence tomography and ultrasound biomicroscopy. Chin Med J. 121(14):1274-9.

.....  
Martin VANTOMME

Cliniques Universitaires St-Luc, UCL, BRUSSELS – BELGIUM  
.....



.....  
**AN UNEXPECTED  
HYPOTONY MACULOPATHY  
AFTER TRABECULECTOMY**  
.....

**★ INTRODUCTION ★**

Hypotony syndrome is characterized by an IOP statistically defined as lower than or equal to 6 mmHg with associated fundus changes, including chorioretinal folds, optic nerve swelling and vascular tortuosity. Young age, male gender, myopia - particularly young high myopic patients who have a sclera less rigid and more susceptible to swelling and contraction- and above all peroperative use of Mitomycin C are known risk factors for post-operative hypotony. Prolonged hypotony and its associated maculopathy had been found to develop in 1.3% to 7% in eyes having application of Mitomycin-C [1].

Hypotony may lead to wrinkling of the retina, thickening of the choroid and/or inward collapse of the scleral wall. This results in hyperopia, due to shortening of the axial length [2].

Normalisation of IOP leads to decrease in the chorioretinal folds, thereby improving visual acuity. However, in long-standing macular hypotony, visual acuity may not improve after IOP normalisation due to permanent retinal dysfunction [1].

## ★ CASE REPORT ★

A 48-year-old teacher came to see his ophthalmologist in November 2010 because of visual field difficulties that had an impact on his daily activities. During the examination, an ocular hypertension of 30 mmHg in both eyes, associated with a severe glaucomatous excavation of the optic discs was diagnosed while the patient was referred to our Ophthalmology Department.

During the first visit the patient complained about coloured halos without accompanying headaches for a long time and the sensation of a strongly restricted visual field in his right eye.

A detailed patient's personal, ocular and systemic as well as family history was negative.

During the clinical examination, his corrected visual acuity with a spherical equivalent of -1.00 D was 1.0 in both eyes in far and near vision.

In automated perimetry, the right visual field was tubular. Initially the LE also showed a severely restricted visual field that improved during the next following examinations (Fig 1).

Except for a borderline Von Herick test, the slitlamp examination was normal. IOP was 23 mmHg in the RE and 21 mmHg in the LE with combined Timolol and Latanoprost. Central corneal thickness measurements were within normal limits. In gonioscopy, in primary position, an iridotrabecular contact was visible on the entire angle circumference in primary position without any marked anterior convexity of the iris. After dynamic gonioscopy, the scleral spur was visible everywhere, the trabecular meshwork appeared finely pigmented and a double hump aspect of the peripheral iris gave rise to a suspicion of an iris plateau configuration.

Ophthalmoscopy showed a severe excavation of the two optic discs. As showed on fig. 2, the right optic disc was particularly pale and showed a vicariant circulation on its inferior side. Associated increased vascular tortuosity, especially in the inferotemporal vein compared to the LE, were suggestive of a previous retinal branch venous occlusion.

As a result of these findings, a diagnosis of bilateral severe juvenile-onset glaucoma associated with an iris plateau configuration and a predisposition to angle closure was made.

Considering that the target pressure should be optimally in the low teens in the right eye and in a range between 14 mmHg and 16 mmHg in the left eye, a bilateral filtering surgery was suggested to the patient.

An uneventful trabeculectomy was performed in the right eye in November 2011 and was combined with a Mitomycin C application at the concentration of 0.2 mg/ml during 3 minutes. A total of four sutures of nylon 10-0 were placed on the scleral flap.

The first postoperative month passed without complications. In view of a moderately excessive vascularisation of the bleb filtration, together with

a subsequent risk of bleb failure, four 5 FU sub-conjunctival injections were performed.

At six weeks postoperatively, the IOP was 7 and 23 mmHg in the RE and the LE respectively. For work-related reasons, the patient preferred to postpone the trabeculectomy in his other eye. In the meantime, he was referred back to his ophthalmologist.

At three months postoperatively, his IOP was 12 and 30 mmHg in RE and LE respectively.

Five months after the trabeculectomy, the patient complained about blurred and fluctuating vision in his right eye since a few weeks. He had not had any further topical treatment in his RE. His visual acuity was 0.15 blurred with correction in the right eye, improving to 0.9- with +0.75 dioptres and Asta 2- with +2.25 dioptres in near vision. He did not notice any metamorphopsia and the visual field loss was stable.

A slitlamp examination showed a mild shallowing of the right anterior chamber and a moderately over-filtrating diffuse watertight bleb. The IOP was 10-11 mmHg.

In ophthalmoscopy, numerous horizontally delineated folds of the papillo-macular choroid and retina were visible (Fig 3). Neither a choroidal detachment nor further increased vascular tortuosity were noted. At this stage, it was decided to wait and see what would happen.

Three months later, the situation had worsened somewhat. Visual acuity reached 0.8- with +2.00 D and Asta 2 with an appropriate addition. Metamorphopsias were described by the patient. The shallowing of the anterior chamber was unchanged. The IOP was still 10 mm Hg. In gonioscopy, the trabeculectomy opening was visible in the immediate vicinity of the trabecular meshwork. No cyclodialysis cleft was observed.

Spectral-Domain Optical Coherence Tomography (OCT) could confirm the finding during the ophthalmoscopy of numerous macular folds (Fig 4).

After discussion with the patient and, considering all the circumstances, a surgical revision of the trabeculectomy was offered right away and performed at the end of September 2012. Peroperatively, the scleral flap appeared to be gaping abnormally on the nasal side. Two new nylon 10-0 sutures were added on this side together with another suture on the long side of the flap.

In the immediate postoperative period, the patient complained of violent headaches resulting from an IOP peak reaching 52 mmHg that were treated successfully after having proceeded to Argon laser suture lysis of one of the newly added sutures (Fig 5).

During the next following weeks, the situation gradually improved. Two months and half after this surgical revision, visual acuity reached 0.9+ with a spherical equivalent of +1.00 dioptre and Asta 1 slowly. Mild metamorphopsias were still present, 10- degrees central visual field was unchanged and the anterior chamber was only slightly deeper. The IOP was 16 mmHg. OCT-scan showed a

noticeable decrease of the macular retinal folds (fig 6), whereas ophthalmoscopy changes were not so well perceptible.

## ★ DISCUSSION ★

This case serves as a good reminder of some important issues concerning very advanced glaucomas in one hand and ocular hypotony after filtering surgery on the other hand.

The concept of target IOP should be kept in mind for every individual patient. The target IOP determination is based on a risk factor analysis of different outcomes for the individual patient (amount of glaucoma damage, individual progression, risk factors for progression, life expectancy,...)<sup>[3]</sup>. Clearly there is no single IOP level that is safe for each individual patient.

According to the EGS Guidelines, the target IOP should be lower than 18 mmHg in early POAG, lower than 15 mmHg when there is a moderate damage, lower than 12 mmHg in a more advanced stage and less than 10 mmHg in terminal glaucoma; just as in our patient<sup>[4]</sup>.

As mentioned in the introduction, ocular hypotony refers to an IOP lower or equal to 6 mmHg. However hypotony-related complications (and especially hypotony maculopathy) may indeed develop at higher IOP levels, i.e. at 10 mmHg as in our patient, whereas they will never develop in other patients with chronic 2-3 mmHg levels.

Moreover in our case, ocular hypotony developed in the absence of any over-filtrating bleb although the anterior chamber remained mildly shallow for some unknown reason. In addition to a direct toxic effect of Mitomycin C on the ciliary body, a previous history of retinal venous occlusion as suggested by the aspect of the optic disc and the tortuosity of the retinal vessels in our patient, cannot be excluded as a contributing factor to this hypotony syndrome.

## ★ CONCLUSION ★

This case illustrates a paradoxical situation where a low target IOP of 10 mmHg has been obtained with trabeculectomy, but at the cost of an impaired vision secondary to the occurrence of a hypotony maculopathy. The resuturing of the scleral flap was associated with a decrease of hypotony maculopathy but also with a slight IOP increase that will potentially compromise the control of glaucoma itself in term. Moreover OCT-scan proved to be a more useful diagnostic tool in the follow-up of this hypotony maculopathy than ophthalmoscopy where changes were less perceptible.

Whether the young age of our patient, the peroperative use of Mitomycin, the possible changes in the choroidal circulation secondary to previous venous retinal occlusion as well as the degree of collapse of the scleral wall, have interfered individually or not, is still a debate.

★ FIGURES ★

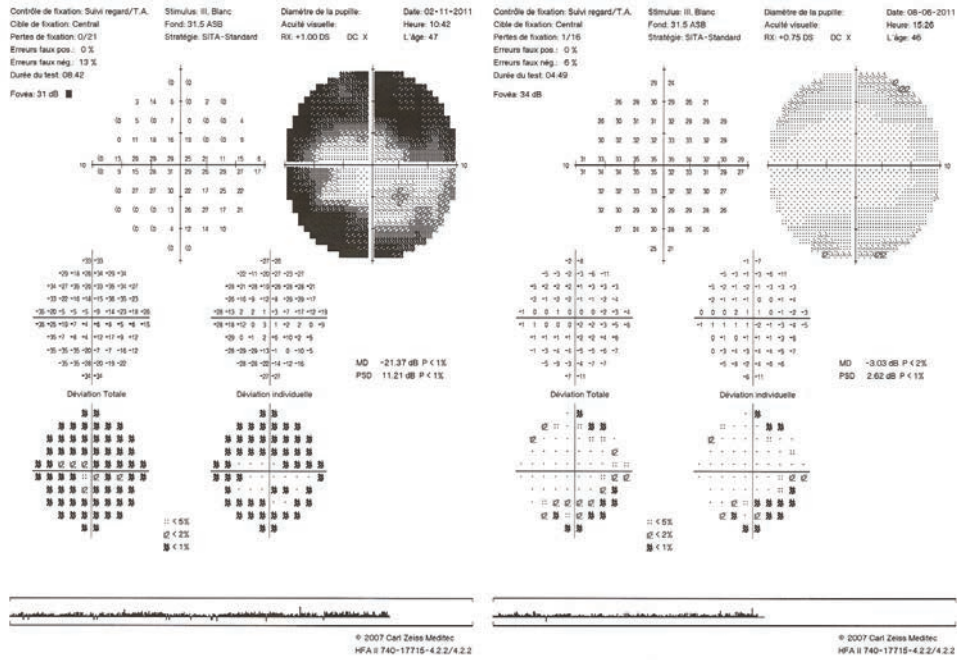


Fig 1 Static Automated Perimetry in both eyes (Sita Standard 10.2, Humphrey Field Analyzer)

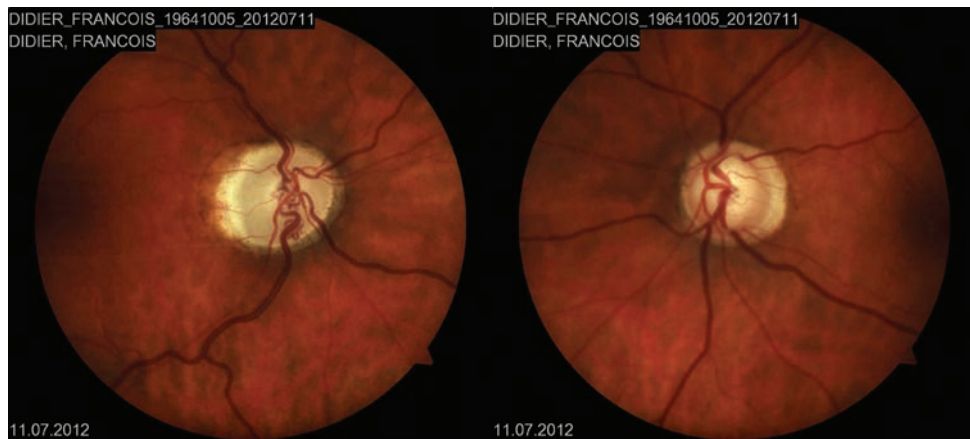


Fig 2 Ophthalmoscopy. Notice the vicariant circulation on the right optic nerve head and the increased inferotemporal venous tortuosity in the RE compared to the LE.

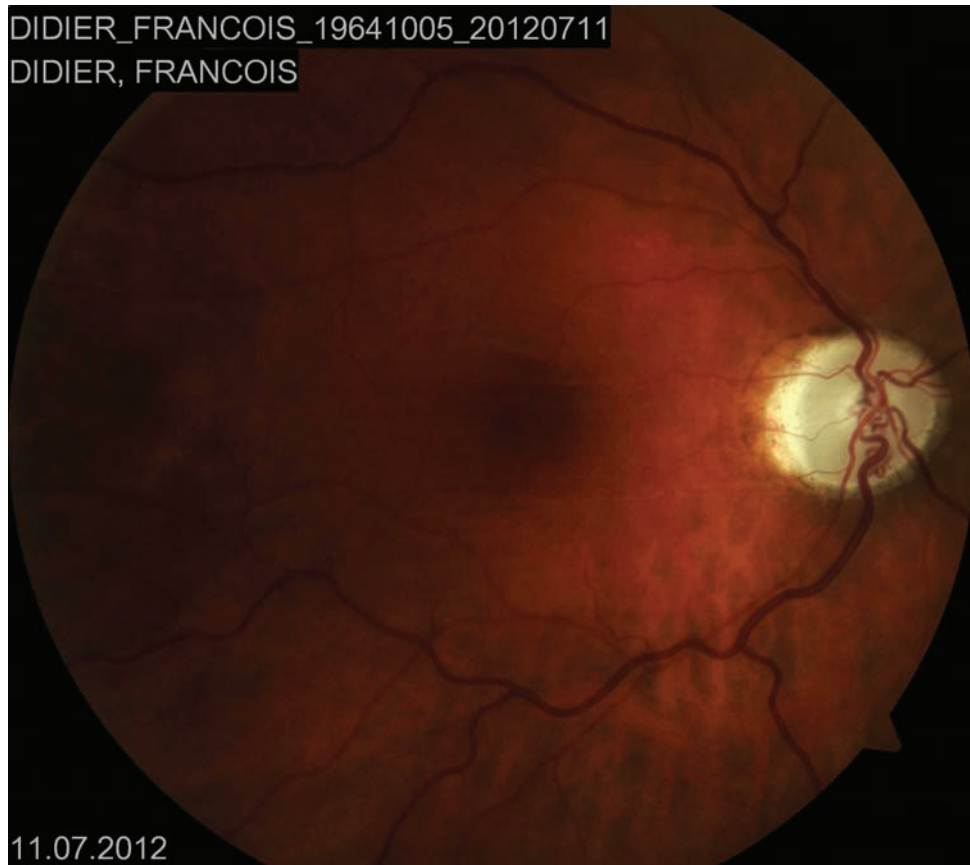

Fig 3 Horizontally delineated folds of the papillo-macular choroid and retina in the RE

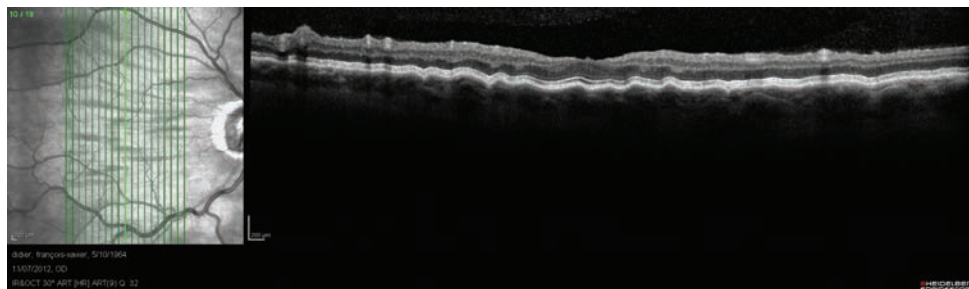


Fig 4 Optical Coherence Tomography (Spectral Domain-OCT) shows the chorioretinal folds

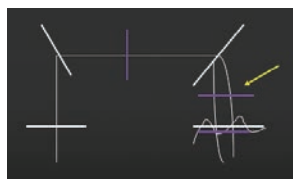


Fig 5 Scheme of the scleral flap and nylon 10.0 sutures. Three Nylon 10.0 sutures (in purple) were added during surgical revision. The infero-nasal suture was removed post-operatively by argon suture lysis because of high postoperative IOP.



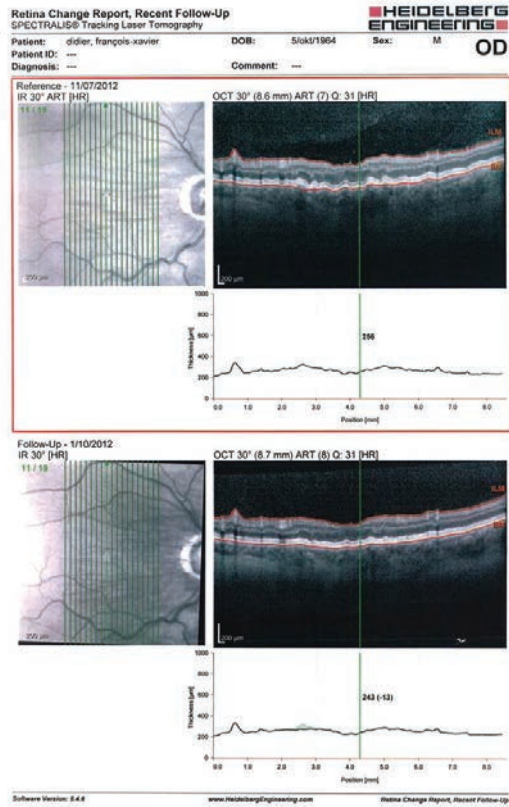


Fig 6 Decrease in the macular folds seen on OCT-Scan after resuturing the scleral flap and thereby increasing the IOP After surgical revision

## ★ REFERENCES ★

- [1] SCOTT M. L. et al. - Ophthalmic Pearls: Glaucoma. Assessing and Managing Hypotony Maculopathy. Edited by Sharon Fekrat, MD, and Ingrid U. Scott, MD, MPH: American Academy of Ophthalmology Web Site: [www.aao.org](http://www.aao.org)
- [2] COSTA V., ARCIERI E. - Hypotony maculopathy. Acta Ophthalmologica Scandinavica, Volume 85, Issue 6, pages 586-597, September 2007
- [3] JAMPEL H. - Target IOP in clinical practice. Intraocular Pressure. Edited by RN. Weinreb, JD Brandt, D. Garway-Heath and FA. Medeiros. Kugler Publications, Amsterdam, The Netherlands, Consensus series 4, 2007: 121-5.
- [4] THE EUROPEAN GLAUCOMA SOCIETY - Terminology and guidelines for Glaucoma Ed DOGMA 2003.



.....  
**TREATMENT DILEMMA IN A  
PATIENT WITH GLAUCOMA AND  
RECURRENT SCLERITIS : ENDOSCOPIC  
CYCLOPHOTOCOAGULATION AS  
ULTIMATE THERAPY**  
.....

**★ INTRODUCTION ★**

The ophthalmologist has a broad armamentarium of local, systemic, laser and surgical treatment options in the treatment of POAG (primary open angle glaucoma). Often, the therapeutic strategy needs to be switched because of insufficient effects or side effects. When glaucoma is associated with anterior eye segment disorders and a changed anatomy of the conjunctiva and sclera treatment options are often limited.

## ★ CASE REPORT ★

A 60-year woman presented in 2003 with primary open angle glaucoma with a glaucomatous visual field defect in the left eye and a stable intraocular pressure (IOP) under latanoprost and brimonidine. In her past medical history, she had a bilateral phaco-emulsification with intraocular lens implantation. Systemic antecedents are an ablation for an atrial flutter, asthma, chronic obstructive pulmonary disease and a benign thyroid nodule. After 2 years loss to follow-up she complained in 2008 about bilateral painful red eyes since several weeks. On slitlamp examination both episcleral and scleral veins were dilated and nodular scleral thickening with chemosis was noticed (Fig. 1). The IOP in the left eye was 38 mmHg. On gonioscopy the angle was open over 360 degrees. Visual field examination demonstrated a dramatic decline in visual field of the left eye (Fig. 2).

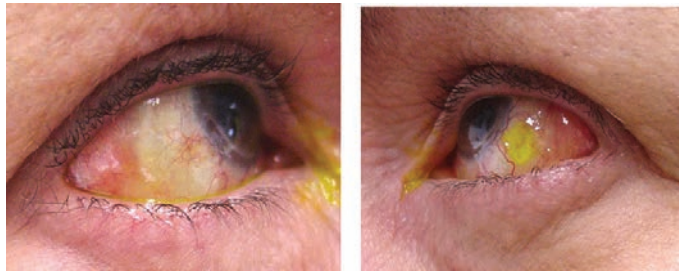


Fig. 1 Nodular scleritis since several weeks




Fig. 2 Dramatic decline of the visual field of the left eye

Diagnosis of scleritis was made and treatment with systemic high dose NSAID (non-steroidal anti-inflammatory drugs) was started. An immunological work

up was performed. Although this case is clinical suggestive for rheumatoid arthritis the work up could not support the diagnosis of any systemic disease, even when repeated twice. Because prostaglandin analogues can promote inflammation, latanoprost was switched to timolol, brimonidine was continued and systemic acetazolamide was started.

The scleritis resolved slowly with some recurrent attacks and IOP decreased to an acceptable level so treatment was continued. In 2009 systemic NSAID were stopped because of side effects and glucosamine in combination with chondroitin sulphate was started. Unfortunately in 2011 IOP increased to 28 mmHg under maximal topical medication and systemic acetazolamide.

Treatment compliance was also a major problem in this case because the patient complained about side effects of every medical treatment. She refused any systemic immunosuppressive therapy for the scleritis and when the eye pressure in the left eye increased she did not want to take a higher dose of systemic acetazolamide because of subjective side effects.

Recurrent scleritis had caused scleromalacia more significant in the left eye with scleral thinning over 3 clock hours and thickening over more than 3 clock hours (Fig. 3,4) so standard glaucoma laser treatment and surgical filtering treatment options were contraindicated.

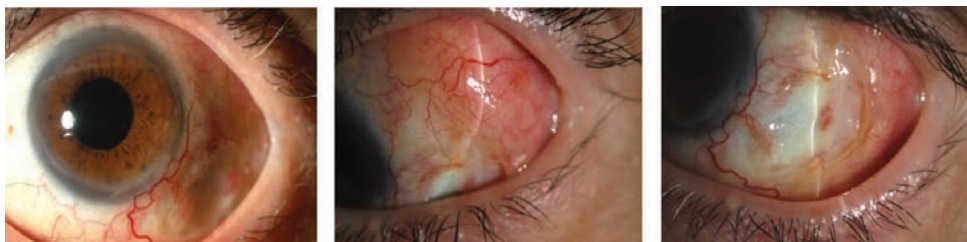

Fig 3. Scleromalacia of 6 clock hours in the left eye

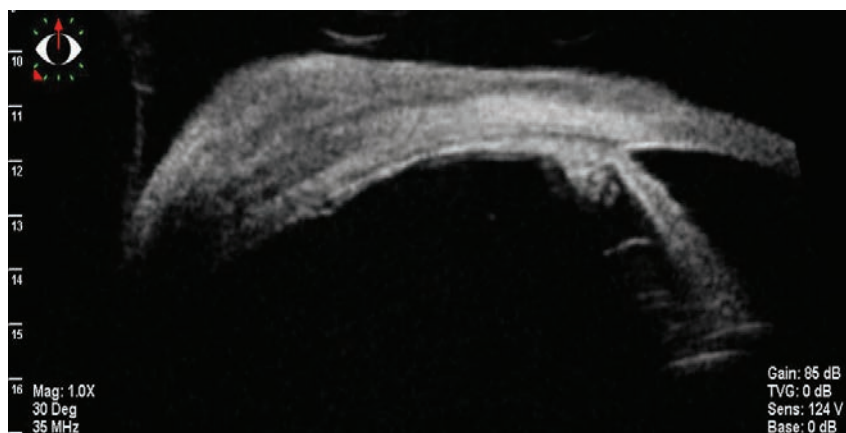


Fig 4. UBM ultrasonography of the scleromalacia of the left eye

Under retrobulbar anesthesia an endoscopic cyclophotocoagulation with the Iridex 532nm endolaser was performed over 180 degrees. Perioperative there were no complications. Postoperative timolol and brimonidine was continued. Hydrocortison 10mg/oxytetracycline (hydrochloride) 30mg/g cream was

given for 2 weeks to prevent postoperative inflammation and infection. One week postoperative IOP was 11 mmHg without any significant inflammation or scleritis. Since endocyclophotocoagulation follow up period is 15 months, IOP remained in the range between 11 and 17 mmHg with timolol and brimonidine, the visual field is stable (Fig. 5) and no exacerbations of the scleritis were noticed.

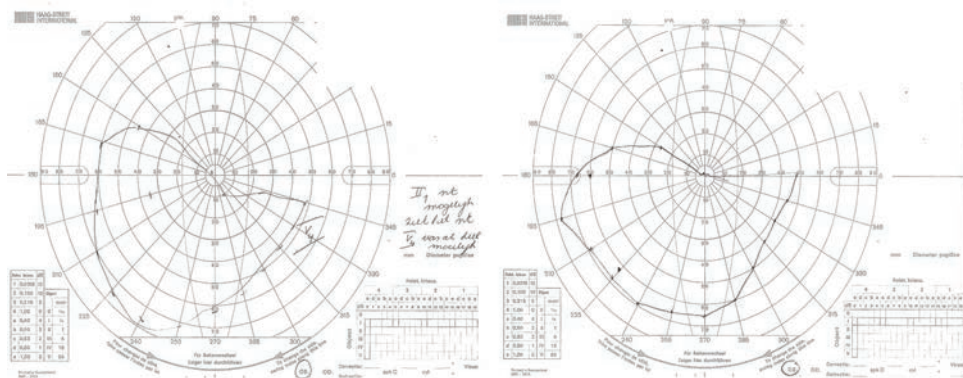


Fig 5. Since endoscopic cyclophotocoagulation, visual field of the Left eye in 2010 (left panel) remains stable (2012, right panel).

## ★ DISCUSSION ★

Prostaglandin analogues are very potent in lowering IOP and are a first line treatment in POAG. In this case the patient suffered from redness of the eyes since several weeks. This conjunctival redness can be caused by the prostaglandin analogues as common side effect but as ophthalmologist every “common redness” needs to be differentiated. Because in inflammation and in this case scleritis continuing prostaglandin analogues might promote inflammation. Since latanoprost was stopped, there was a markedly decrease in scleritis attacks but this decrease can also be explained by the systemic NSAID or glucosamines and chondroitin sulphate. The use of glucosamines and chondroitin sulphate is controversial in the anti-inflammatory treatment of osteoarthritis (Miller and Clegg, 2011) and in ophthalmology there are no reported experiences. Nevertheless, we started the glucosamines and chondroitin sulphate because the patient absolutely refused any other anti-inflammatory treatment after side effects of the NSAID.

In this case the patient suffered from POAG before she developed scleritis. Scleritis is also a risk factor for ocular hypertension and secondary “vascular” glaucoma because the chronic scleral inflammation blocks the ciliary emissary veins impairing uveoscleral outflow of the aqueous humor (Bietti and Vanni, 1961; De Keizer, 1983; Rosa 2012). In a recent study of 271 scleritis patients, a significant increase of the IOP was seen in 18% of the patients with nodular scleritis and in 18% of the cases of diffuse anterior scleritis. In 82% the IOP increase was measured during the acute phase of the scleritis (Heinz et al, 2012). In the diagnoses and follow up of scleritis, the IOP should be measured, but interpreting intra ocular pressure measurements in scleritis patients needs to be done with caution as it is influenced by the scleral rigidity. Nessim et al. (2005) reported a case of unilateral glaucoma with falsely

Low intraocular pressure reading as a result of scleral thinning from anterior scleritis. In scleritis and glaucoma, gonioscopy should be performed as it is known that an associate posterior scleritis can promote angle closure glaucoma (Ugurbas et al, 2012).

Laser and surgical treatment options are limited in scleritis patients because these interventions should promote reactivation of the inflammation and scleritis. Filtering surgery usually fails because of scleromalacia and the risk for inducing scleritis and scleral melting even more when antimetabolites are used (Fourman, 1995). Although Williams et al. (2011) reported a successful case of a trabeculectomy with mitomycin C performed in refractory glaucoma associated with non-necrotizing anterior scleritis secondary to a transscleral cyclophotocoagulation.

In our case endoscopic cyclophotocoagulation resulted in a good control of the IOP and an stable visual field. Most studies report transscleral cyclophotocoagulation for therapy resistant inflammatory glaucoma (Schlote et al, 2000; Pushka and Tarkkanen, 2007). In this case photocoagulation was performed through a clear corneal 1 mm incision. We hypothesize that this approach carries less risks for complications because scleral perforation and necrotizing scleritis were reported after transscleral cyclophotocoagulation in scleritis and scleromalacia (Gaasterland and Pollack, 1992; Shen et al, 2004).

## ★ CONCLUSION ★

Scleritis is a chronic inflammation of the eye and carries an increased risk for ocular hypertension and secondary glaucoma. Glaucoma treatment can be challenging in these patients. Prostaglandin analogues should be avoided because the risks of inflammation. The IOP lowering effect is also limited as prostaglandin analogues increase uveoscleral outflow and chronic inflammation of the sclera obstructs this outflow. When local and systemic medication fails to lower the IOP or when compliance is low because of side effects laser treatment and filtering surgery have a high risk of failing. In these cases endoscopic cyclophotocoagulation can be a valuable treatment option.

## ★ REFERENCES ★

- Bietti G, Vanni. Glaucoma secondary to extraocular venous obstruction. *Opt Acta (Lond)* 1961;142:227-65.
- De Keizer R. Secondary vascular glaucoma. *Doc Ophthalmol* 1983;56(1-2):195-202.
- Fourman S. Scleritis after glaucoma filtering surgery with mitomycin C. *Ophthalmology* 1995;102(10):1569-71.
- Gaasterland D, Pollack I. Initial experience with a new method of laser transscleral cyclophotocoagulation for ciliary ablation in severe glaucoma. *Trans Am Ophthalmol Soc* 1992;90 :225-246.
- Heinz C, Bograd N, Koch J, Heiligenhaus A. Ocular hypertension and glaucoma incidence in patients with scleritis. *Graefes Arch Clin Exp Ophthalmol* 2012 [Epub ahead of print]
- Miller K, Clegg D; Glucosamine and chondroitin sulphate. *Rheum Dis Clin North Am* 2011;37(1):103-18. Epub 2010 Dec4.
- Nessim M, Kyprianou I, Kumar V, Murray P. Anterior scleritis, scleral thinning, and intraocular pressure measurement. *Ocul Immunol Inflamm* 2005;13(6):455-7.
- Pushka P, Tarkkanen A. Transscleral red laser cyclophotocoagulation for the treatment of therapy-resistant inflammatory glaucoma. *Eur J Ophthalmol* 2007;17(4):550-6.
- Rosa R.S. Jr. (2012). Pathology and intra ocular tumors 2012-2013, Chapter Sclera. *Academy of American Ophthalmology*. 402pp.
- Schlote T, Derse M, Zierhut M. Transscleral diode laser cyclophotocoagulation for the treatment of refractory glaucoma secondary to inflammatory eye diseases. *Br J Ophthalmol* 2000;84(9):999-1003.
- Shen S, Lai J, Lam D. Necrotizing scleritis following diode laser transscleral cyclophotocoagulation. *Ophthalmic Surg Lasers Imaging* 2004;35(3)251-3.
- Ugurbas SH, Alpay A, Ugurbas SC. Posterior scleritis presenting with angle closure glaucoma. *Ocul Immunol Inflamm*. 2012;20(3):218-20.



.....  
Elena JURADO GONZÁLEZ

Hospital de l'Esperança (Parc Salut Mar).

Sant Josep de la Muntanya, 12. BARCELONA 08024 – SPAIN  
.....



.....

# OPTIC NERVE DRUSEN AND GLAUCOMA

.....

## ★ INTRODUCTION ★

The word “druse” comes from the german language word “drusen” meaning tumor, swelling or tumescence.

Histologically they are composed by mucopolysaccharides, amino acids and deoxyribonucleic acids concentric lamellae and a small amount of iron and calcium. Most often they are located anterior to the cribriform plate.

Its prevalence is 0.34% in adults and 0.4% in children, being two of every three cases bilateral.

They follow a dynamic process throughout life, they increase in size and calcify, becoming more visible and after adulthood they begin to atrophy.

Diagnostic confirmation in cases of doubt can be done by imaging methods such as B- mode ultrasound. They can also be seen using Computerized Tomography due to their calcium density and in retinal photographs with anterior light filters since they are autofluorescent.

Optic disc drusen are classified depending on optic nerve head cupping and drusen visibility. Their classification grading system increases at the same time drusen become more visible and cupping reduces (I-buried, excavated to III- visible, without cupping).

They are the most common cause of pseudopapilledema.

Clinically, they can produce transient and recurrent visual obscurations, usually lasting only few seconds. They can be cause of permanent vision loss producing visual field defects.

Drusen-related complications like neovascularization and hemorrhages, central retinal artery occlusion, central retinal vein occlusion and nonarteritic anterior ischemic optic neuropathy can occur. This last one is the main cause of visual loss in these patients.

There is currently no effective treatment, so periodic visual examination is recommended.

## ★ CASE REPORT ★

A 32-year-old female was referred to our hospital to study asymptomatic optic nerve head drusen.

She did not have significant previous ophthalmological or general history.

In her initial exam visual acuity was 20/20 in both eyes, no relative afferent pupillary defect was present, extraocular movements were unaltered and Ishihara test was OD 17/20 and OS 16/20. Slit lamp examination showed intraocular pressure (IOP) of 16 mmHg in both eyes and normal anterior segment. The fundus revealed of the eye appear small, little excavated papillae with surface drusen and probably some others buried (fig.1 and 2).

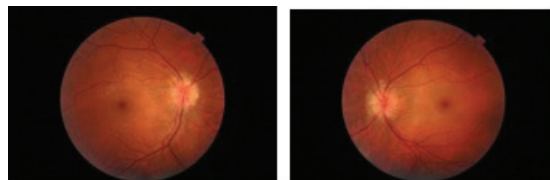


Figure 1. Optic nerve drusen appearance in our patient's both eyes

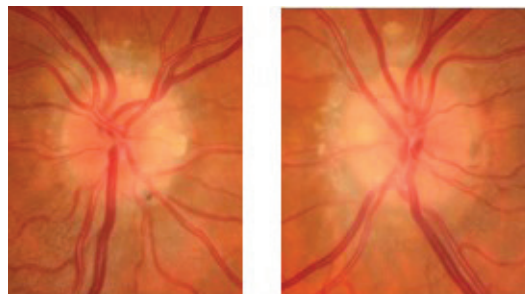


Figure 2. Optic nerve drusen at higher magnification

Additional tests were then performed to further study structure and functional status of our patient: autofluorescence by Spectral-Domain OCT, Humphrey 24-2 SITA-standard, perimetry and optic nerve head retinal nerve fiber layer study with OCT (fig. 3, 4 and 5). As seen in figure 3, Spectral Domain OCT is able to generate high-quality optic disc drusen images.

The visual field test was normal in the right eye and showed an inferior arcuate defect in the left eye. This finding was compatible with the papillary OCT thinning found in the same eye. However, since intraocular pressure was normal we decided to not treat the patient for the moment and follow her every three months.

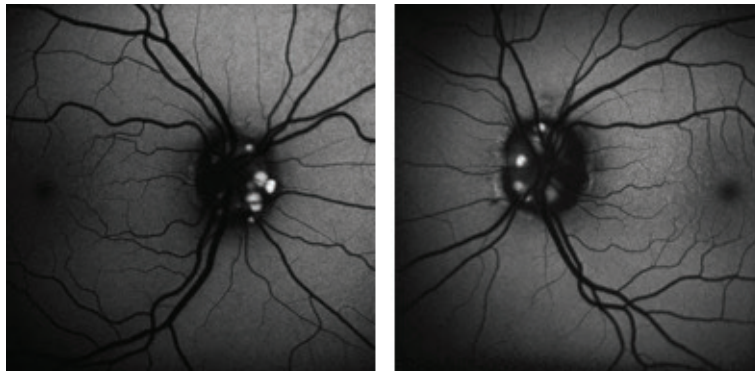


Figure 3. Optic nerve head drusen, autofluorescence images obtained with Spectral Domain OCT




Figure 4. Visual field shows abnormal test in the right eye and a left eye with an inferonasal arcuate defect

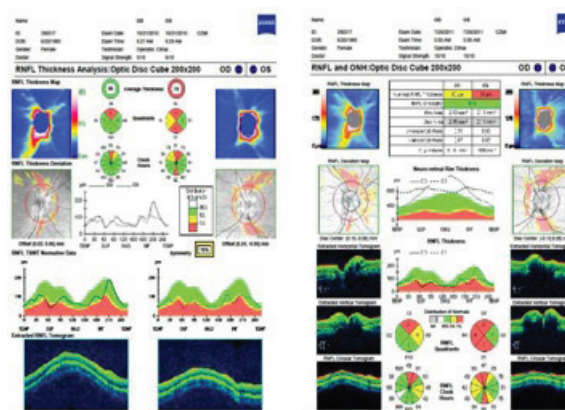


Figure 5. OCT optic nerve head shows an altered right eye upper quadrant and in the left eye the average thickness is reduced as well as upper, lower and nasal quadrant. Nasal quadrant experimented a further reduction after 9 months

Over a follow-up of 9 months, progression by OCT was confirmed and borderline IOP of 19-20 mmHg was found. So in the context of a visual field defect suggestive of glaucoma we decided to initiate topical treatment with Tafluprost one drop every 24 hours in the left eye. We had good IOP control of 12 mmHg in that eye without perimetric or structural progression.

Half a year later, the patient wants to get pregnant and is afraid to stop topical treatment, so we decided to replace the treatment prescribed by Timolol 0.50% 1 drop every 12 hours in both eyes until confirmation of pregnancy.

## ★ DISCUSSION ★

Optic nerve drusen have multiple systemic and ocular associations (fig 6 and 7), including glaucoma <sup>(5)</sup>.

Systemic abnormalities associated NOD	Ocular abnormalities associated NOD
Dyslexia and psychomotor retardation	Ophthalmic artery aneurysm
Epilepsy	Atrophy pigmented venous retinochoroidal
Tuberous Sclerosis	Atrophy gyrata
Schizophrenia	Congenital night blindness
Migraine	Thin cornea
Tubulointerstitial nephritis and uveitis	Macular dystrophy family
POEMS	Cone dystrophy
Pseudotumor cerebri	Birdshot disease and syndrome Cacchi-Ricci
Pseudoxanthoma elasticum	Glaucoma
Mental retardation	Astrocytic hamartoma
Intracranial tumor	Nanophthalmos
Sd de Alagille, Alport, Alstrom, Noonan, Joubert, Sturge-Weber, Usher	Central serous retinopathy peripapillary
	Retinitis pigmentosa
	Syndrome Nanophthalmos-Retinitis pigmentosa- Foveosquiosis-DNO
Figure 6	Figure 7

The diagnosis of drusen is easier in the case of visible drusen although imaging is usually needed for confirmation. Ultrasound B is the most frequently used system but images are sometimes difficult to interpret. As we have seen, the autofluorescence-mode Spectral Domain OCT can generate high quality images giving us the diagnosis and localization of drusen.

In cases of association between drusen and glaucoma the diagnosis is more complex because of a variety of reasons: firstly drusen visual field defects may mimic glaucomatous pattern and secondly because of the difficulty of interpretation of the papilla in the fundus <sup>(2,3,4,7)</sup>. Furthermore, both glaucoma and optic nerve drusen may lead to a decrease of thickness of layers of nerve fibers measured by optical nerve OCT <sup>(6)</sup>.

Therefore, if the presence of drusen is associated with severe visual field damage or if progression is confirmed, regardless of presence or absence of

associated ocular hypertension, antihypertensive ocular treatment is recommended <sup>(4)</sup>.

Our patient wanted to get pregnant and asked us for advice about her topical treatment. Although there is not consensus on what action to take and considering that physiological IOP lowering occurs during pregnancy, it is recommended to stop treatment if possible and closely monitor the patient. If topical treatment is mandatory because of advanced glaucoma or progression confirmation or if the patient prefers to be treated until the pregnancy is confirmed (like our patient), then beta-blockers may be started <sup>(8, 9, 10, 11)</sup>. Although there are few data on the safety of antiglaucoma drugs during pregnancy and most of drugs are category C betablockers are by far the most known option since they are used in other diseases that can appear during pregnancy. For this reason it is very important to have close communication with the ob/gyn specialist.

## ★ CONCLUSION ★

Optic nerve drusen can be associated to glaucoma.

For diagnosis and follow-up we have seen that Spectral-Domain OCT autofluorescence mode can be very useful.

In cases in which drusen are accompanied by damage or visual field progression is confirmed, regardless of ocular hypertension, initiating antihypertensive ocular treatment is recommended.

If the patient has also desires to get pregnant, it is necessary to put emphasis on the importance of close monitoring, assessing the possibility of taking off antiglaucoma treatment temporarily.

During pregnancy, none of the antiglaucoma drugs is completely safe. However, if needed or requested, beta-blockers can be used with precaution.

## ★ REFERENCES ★

1. Guerrero Altares L. Study quantifying the nerve fiber layer optical coherence tomography spectral domain (Cirrus OCT) and time domain (stratus OCT) in patients with optic disc drusen. Thesis. Department of morphological sciences and surgery. University Alcalá. 2010.
2. Optic disc drusen and glaucoma--case report. Pojda-Wilczek D, Herba E, Jedrzejewski W, Pojda SM. Optic disc drusen and glaucoma--case report. *Klin Oczna*. 2004; 106(1-2 Suppl):263-5.
3. Viestenz A, Langenbacher A, Mardin CY. Bilateral visual field defects with optic disc drusen and secondary open angle glaucoma with PEX--clinical correlation with the HRA. *Klin Monbl Augenheilkd*. 2004 Apr; 221(4):280-4.
4. Spalding JM. Visual-field loss with optic nerve drusen and ocular hypertension : a case report. *Optometry*. 2002 Jan; 73(1):24-32.
5. Piccone MR, Piltz-Seymour JR, Shin D. Coexisting optic nerve head drusen and glaucoma. *Ophthalmology*. 1998 May; 105(5):761-2.
6. Roh S, Noecker RJ, Schuman JS. *Ophthalmology*. Evaluation of coexisting optic nerve head drusen and glaucoma with optical coherence tomography. 1997 Jul;104(7):1138-44.
7. Samples JR, van Buskirk M, Shults WT, Van Dyk HJ. Optic nerve head drusen and glaucoma. *Arch Ophthalmol*. 1985 Nov;103(11):1678-80.
8. Yasemin Kozluca Efe, MD, Silay Canturk Ugurbas, MD\*, Atilla Alpay, MD, Suat Hacı Ugurbas, MD. The course of corneal and intraocular pressure changes during pregnancy. *CAN J OPHTHALMO*, 2012.
9. M. Reza Razeghinejad, MD, Tak Yee Tania Tai, MD, Scott J. Fudemberg, MD, and L. Jay Katz, MD. Pregnancy and Glaucoma. *Survey of Ophthalmology* Volume 56 Number 4 July–August 2011
10. Kara L. Schultz, Andrea D. Birnbaum and Debra A. Goldstein. Ocular disease in pregnancy. *Current Opinion in Ophthalmology* 2005, 16:308—314
11. D. Denis, G. Touvron. Conduite à tenir chez une patiente présentant un glaucome pendant la grossesse. *Entretiens Annuels d’Ophtalmologie*. 8 mars 2010

.....  
Bielecka ANNA  
SPKSO Warsaw Sierakowskiego 13 – **POLAND**  
.....



.....  
**CHRONIC IMMUNOLOGICAL  
DYSREGULATION OF THE OCULAR  
SURFACE AND ITS CONSEQUENCES IN A  
PATIENT TREATED FOR PRIMARY OPEN  
ANGLE GLAUCOMA FOR A LONG TIME**  
.....

**★ INTRODUCTION ★**

This case report presents a patient with primary open angle glaucoma treated with ocular drops and with surgical procedures for high intraocular pressure (IOP). The ocular surface of his eye was chronically damaged by eye drops' preservatives. He suffered from chronic inflammation of the ocular surface. IOP was uncontrolled despite the surgical procedures. The analysis of this case draws a conclusion that increased amounts of eye drops does not mean better result and chronic inflammation of the ocular surface causes difficulties to obtain the reliable IOP values.

## ★ CASE REPORT ★

84 years old patient with primary open angle glaucoma has been treated for 20 years. He underwent extracapsular cataract extraction with intraocular lens implantation in both eyes in 2000. He was using different kind of topical drops for glaucoma treatment over the period of 20 years. Rise intraocular pressure (IOP) was observed periodically. It was poorly controlled on medical treatment so patient was referred for antiglaucoma surgery. He underwent trabeculectomy in the right eye in 2005, one year later in the left eye. The microshunt Ex-Press was implanted in the left eye in 2010. In the early postoperative period there were complications and it was necessary to rinse the anterior chamber and administer antibiotics to the anterior chamber during the first and second day after surgery. The patient was under care of different clinics at that time.

He was admitted to my clinic in 2011. He came to the ophthalmological emergency with pain of his eyes. The IOP was 40 mm Hg in both eyes. He was taking at that time 3 antiglaucoma topical drugs – 2% dorzolamide, 0,03% bimatoprost and 0,5% maleate timolol.

Ocular investigation

BCVA of right eye - 0.5 BCVA of left eye - hand movements

Tod 40 mmHg Tos 40 mmHg

Anterior segment of both eyes: generalized redness of the conjunctiva, filtering bleb in the upper quadrant, cornea – smooth, dry, in the anterior chamber of the left eye –microshunt Ex-Press, iridectomy at 1 o'clock, posterior chamber intraocular lens.

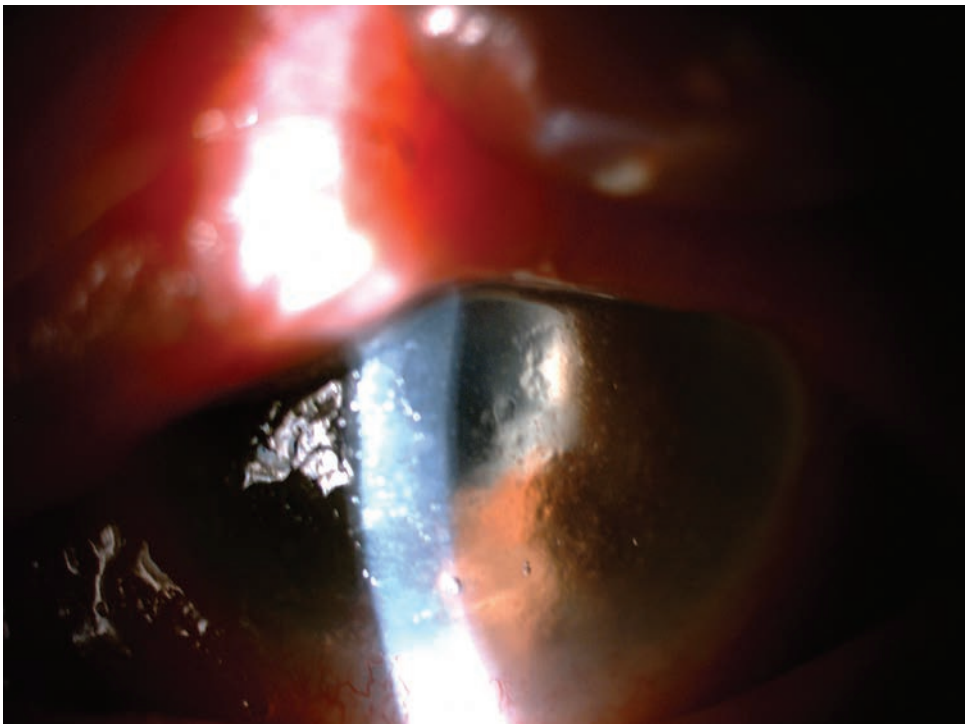
Fundus of both eyes: optic disc pale, cup to disk ratio 0.9 – 1.0, narrow arteries, regular veins, macula in OD without neovascularization, in OS difficult to evaluate, retina attached in both eyes.

Acetazolamide orally was given to decrease his IOP. And after few days he was admitted to the hospital. He was qualified for implantation of microshunt Ex-Press to the right eye and removing Ex-Press from the left eye because of dislocation. 2 months after surgery patient came with uveitis in the right eye and kerato-uveitis in the left eye. Patient was admitted to the hospital. During this hospitalization he underwent cyclophotocoagulation in the right eye because hypotensive effect of previous surgery was not satisfactory. Patient had to take antiglaucoma topical drops all the time because his IOP remained elevated despite the performed procedures. Patient was visiting the clinic very often with many complaints, especially painful eyes. These complaints were caused by very severe dry eye disease, cornea erosion or recurring increase of IOP. 2 months after last hospitalization patient was again admitted to the hospital for cyclophotocoagulation in the left eye because of elevated IOP. One week after procedure patient came back with much escalated pain

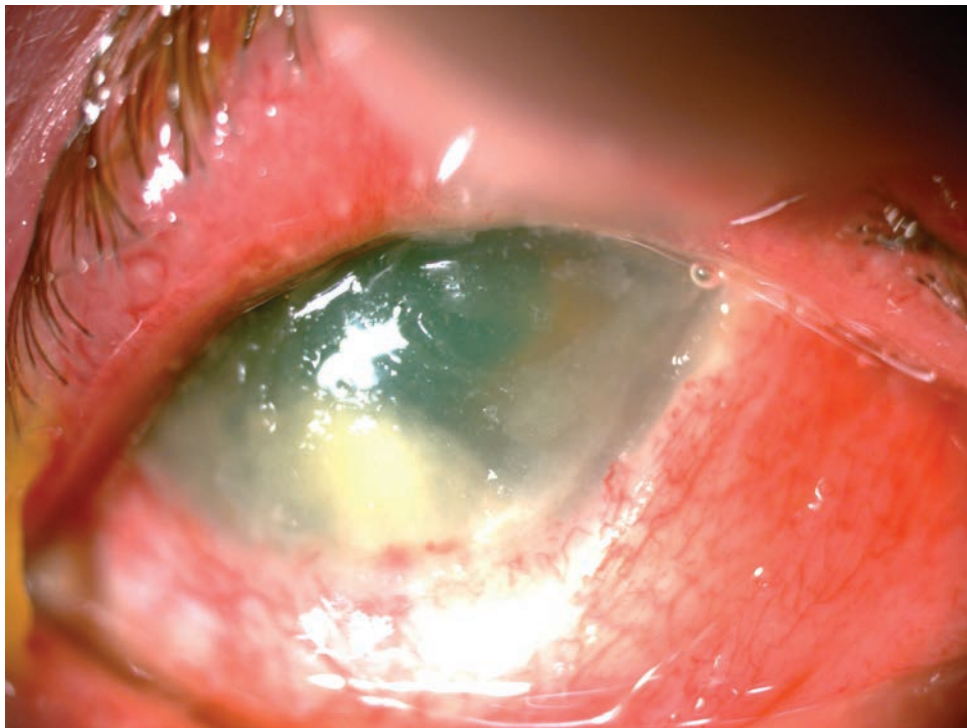
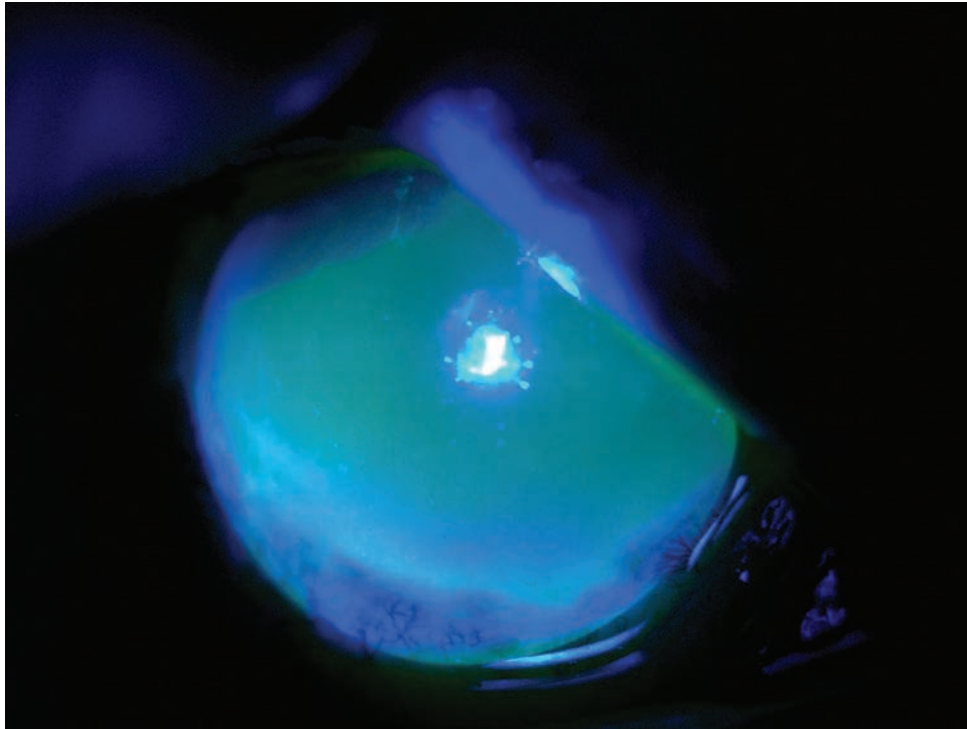


in both eyes. The eye examination revealed purulent discharge and precipitates on the endothelium in both eyes, with fibrinous exudate in the anterior chamber in the right eye. Due to very severe symptoms and because patient wasn't able to use drops on his own he was again admitted to the hospital for intensive medical treatment. Topical antibiotics, steroids, nonsteroidal anti-inflammatory drugs and cycloplegics as well as steroids systematically were administered. Because of erosion contact lens was used as a bandage to heal the ocular surface. During the hospitalization his condition improved.

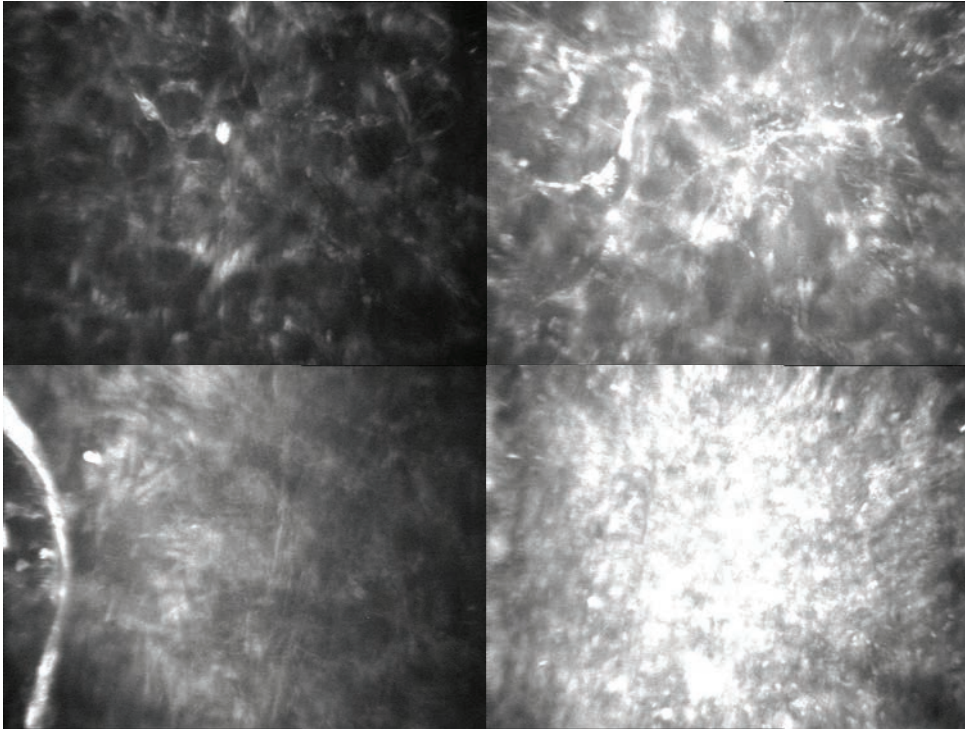
Additional investigations Photos of the anterior surface Severe dry eye



Huge erosion



Confocal microscopy revealed oedema of the stroma with postinflammatory changes in the stroma.



Using tearlab osmolarity system OcuSens the tear film osmolarity was measured. In each examination it was over 310 mmOsmol/ml.

Tear break-up time with fluorescein was about 5 seconds. Noninvasive Schirmer test (using anesthetic drops) was 6mm.

## ★ DISCUSSION ★

We should draw conclusions from medical history of my patient. Some conclusions can be made when take into account summary paperwork of professor Christophe Baudouin based on review of international literature about effect of preservatives on the surface of the eye. Most of the topical drops used in glaucoma treatment contain preservatives. The most popular is benzalkonium chloride which belongs to the quaternary ammonium compounds and at the same it is one of the most toxic and the best known preservative. In vitro studies suggested that preservatives are responsible for most of the toxicity of ocular agents. In case of my patient there were observed increasing corneal changes. At first he had dry eye syndrome, then kerato-uveitis, recurrent erosions and at last keratopathy. Adverse effects were seen also in the conjunctiva and the eye lids as the fibrosis and scarring. There was seen edema in confocal microscopy of the patient. Preservatives act as detergents. These properties cause holes in the cornea which enable some substances and microorganisms to enter to intra- and intercellular spaces and that makes the cornea edematous because of increased fluid absorption. The endothelium failure and opacities of the cornea are the consequences of this process. Detergent effect also causes destabilization of the tear film.

They dissolve the lipid layer and that's the reason why the tear film is not of full value and the watery layer evaporates faster from the surface causing severe dry eye syndrome. In vitro studies proved that preservatives cause huge morphological changes in the corneal and conjunctival cells and finally to their death. Preservatives in topical drops initiate the inflammation on the anterior surface which was proven by in vitro studies. During that process there is increased production and activation of the mediators of inflammatory response, for example metalloproteinase 9 (MMP 9), TNF- $\alpha$ , IL-1 and proteolytic enzymes. These mediators destroy intracellular junctions between epithelium cells of the cornea and that causes decreased permeability. That eliminates function of the epithelium as a protective barrier and could be the reason why my patient had recurrent conjunctivitis, keratitis and uveitis with fibrous exudate in the anterior chamber. Inflammatory factors cause the death of goblet cells and keratinization. All those processes change the ocular surface. Inflammatory reaction itself causes subconjunctival fibrosis which is one of the reasons of failure of filtering surgeries. This side effect was observed in case of my patient where the trabeculectomy and microshunt Ex-Press implantation appeared ineffective. There even was need to remove microshunt from the left eye.

Many studies proved that preservatives including benzalkonium chloride accumulate in the epithelium of the cornea and conjunctiva. They are slowly metabolized and can be released to the tear film and the eye tissues. So even discontinuation of using drops with preservatives does not eliminate their toxicity on the anterior surface. Preservatives also reduce the healing process of injured cornea.

## ★ CONCLUSION ★

Chronic inflammation of the ocular surface and coexisted chronic immunological dysregulation have many unfavourable consequences like severe dry eye syndrome, recurrent erosions and even kerato-uveitis and keratopathy. Important influence on that condition had long-term use of topical drops with preservatives and several ocular surgeries. Infections of the anterior segment often appeared in case of my patient. One of the reason for that was lack of protective barrier of the tear film and damaged corneal endothelium cells integrity. Ineffectiveness of glaucoma surgeries (trabeculectomy, implantation of micro-shunt Ex-Press) could be connected with chronic use of ocular drops with preservatives which cause subconjunctival fibrosis. Affected ocular surface and poor visual acuity caused problems with glaucoma follow up – it wasn't possible to perform visual field test. GDX and HRT weren't reliable. IOP measuring with Goldmann tonometer was also not reliable because of the keratopathy.

Presented case report focus our interest to think about patients treated chronically with ocular drops with preservatives. This particular case shows that more topical drops not always means better. It should be considered to perform a surgery, before the medical therapy induces chronic immunological dysregulation of the ocular surface and will implicate on ineffectiveness of glaucoma filtering surgery.

## ★ REFERENCES ★

1. C.Baudouin, Quinze-Vingt "Ten years of ocular drops without preservatives" National Hospital Center for Ophthalmology, Paris, France
2. Bhavsar, S.G. Bhavsar, S.M.Jain "A review on recent advances in the dry eye: pathogenesis and management" A.S., Oman Journal of Ophthalmology, 2011, May- August; 4(2): 50-56
3. M.Meloni, B.de Servi, D.Marasco, S. Del Prete "Molecular mechanism of ocular surface damage: application to an in vitro dry eye model on human corneal epithelium", Molecular Vision, 2011; 17: 113-126

.....  
Anna KARASIŃSKA

Department Of Ophthalmology Medical University  
In Wrocław Borowska Street 213 – **POLAND**  
.....



.....  
**THERAPEUTIC AND DIAGNOSTIC  
DIFFICULTIES IN ANGLE-CLOSURE  
GLAUCOMA, ACCOMPANYING  
THE CONGENITAL OCULAR  
MALFORMATIONS**  
.....

★ **INTRODUCTION** ★

Angle-closure glaucoma includes a diverse group of disorders that combines anatomy disorder of anterior segment, characterized by closed angle, by the presence of the peripheral anterior synechiae (PAS) or iris adhesion to the trabecular meshwork. In the end, there is an increase of the intraocular pressure (IOP), due to improper circulation of the aqueous humor through the angle of anterior chamber and the development of glaucomatous optic neuropathy. Angle closure-glaucoma can be divided into the primary and secondary glaucoma. This classification depends on the existence of anomalies within the anterior segment. In the secondary angle-closure glaucoma the pathological reason implies closed angle (iris neovascularization, lens swelling, trauma, uveitis), and in the case of a primary angle closure glaucoma there is no pathology, only an anatomical predisposition <sup>(1)</sup>.

## ★ CASE PRESENTATION ★

24-year old female, in good condition, came to the Department of Ophthalmology during emergency service due to acute pain in the left eye. She had a history of treatment with 2% pilocarpine drops to the both eyes, oral acetazolamide without potassium supplementation. In the existing medical records juvenile glaucoma, optic disc coloboma of both eyes and persistent hyaloids artery of both eyes were diagnosed. She also complained of loss of vision in the right eye from some time.

Visual acuity (VA) in the right eye: no light perception, in the left eye counting fingers in front of the eye. The examination in the slit lamp was very hard due to bilateral nystagmus. IOP in the right eye was 24mmHg and in the left eye 54mmHg. The examination of the right eye revealed: pupil in posterior synechiae, cornea translucent, iris not irritated, and flat anterior chamber (Fig1a). The fundus examination was impossible. In the USG B of the right eye there was retinal detachment with vitreoretinal tractions (Fig 1b). The patient didn't know when she stopped see on the right eye.

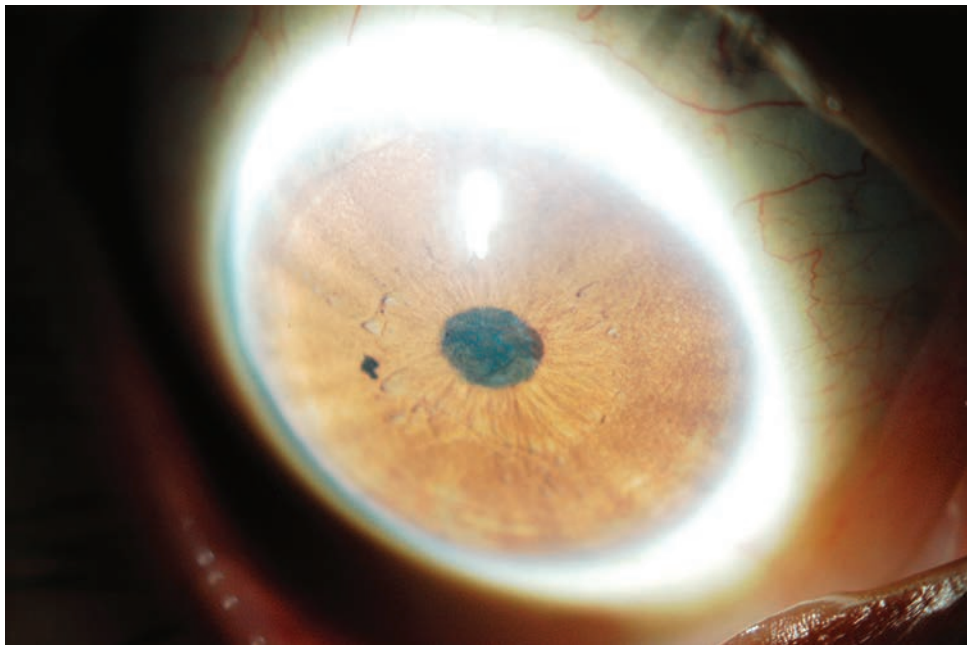


Figure1a .Slit-lamp photograph of the anterior segment at the admission patient to the clinic.

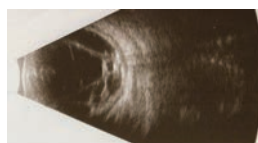


Figure 1b. USG B of the right eye at the admission patient to the clinic.



The examination of the left eye revealed: nanophthalmos, cataract, hyperaemia of the iris (Fig 2a) flat anterior chamber, cornea keratopathy, areas of the sclera atrophy, localized on the 6:00 and 9:00 hour (Fig2b). The pupil was rigid with the low reaction to the light. In the fundus examination there was optic disc coloboma with the total glaucomatous disc cupping (Fig 2c) and glial tissue, which looked like persistent hyaloid artery. We confirmed it by USGB (Fig 2d). Additionally we performed OCT Visatne of the left eye (Fig 2e) and gonioscopy (Fig 2f) to confirmed closed angle in the left eye.

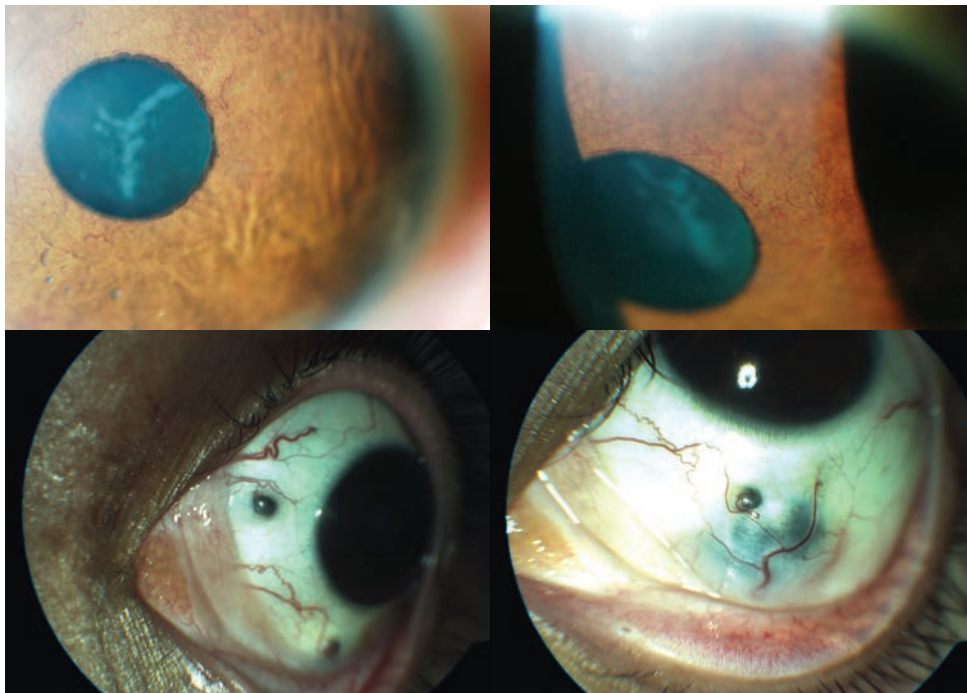


Figure 2a and Figure 2b. Slit-lamp photograph of the left eye at the admission patient to the clinic, showing engorgement of the iris vessels and areas of the sclera atrophy.

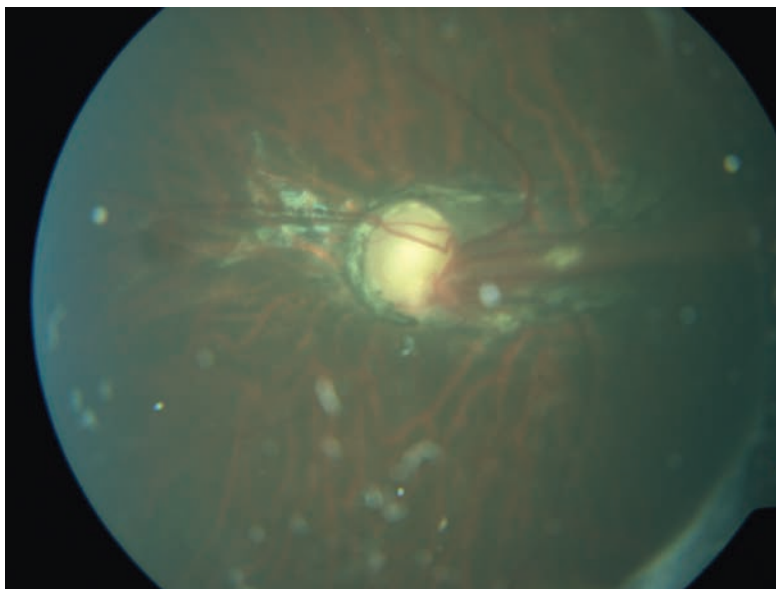


Figure 2c. Fundus color photograph of the optic disc coloboma at the admission patient to the clinic

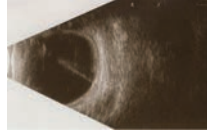


Figure 2d. USGB of the left eye, showing the persistent hyaloid artery.

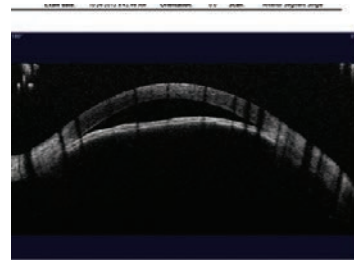



Figure 2e. Slit lamp photograph of gonioscopy. Figure 2f. OCT Vistane of the left eye. Both pictures present closed angle.

Due to appearance of the sclera testing for connective tissue diseases and infectious diseases were performed: ANA, ANCA, RF factor, ACE, RT23, serological test for syphilis and chest X-ray. The patient was given 0,5% Timolol drops twice a day, 1% Atropine drops three times a day to the left eye and 250ml Mannitol in injection. Pilocarpine was withheld. The patient wrote consent form to perform phacoemulsification cataract surgery of the left eye, to reconstruct the anterior chamber and to release pupillary block, under general anesthesia the next day. The axial length of the eye in our patient was 18.47 mm. Expected power of implant was 37.0 diopters. The procedure was performed without any complications. The injections with the antibiotic and steroid (Fortum+ Dexaven) in the final stage of the operation were done under conjunctiva.

Next day IOP in the left eye was 36mmHg. Because of the acute pain of the eye the patient was given Timolol drops and Alphagan drops twice a day, Tobradex drops six times a day to the left eye, injection Mannitol 250ml, oral acetazolamide three times a day with potassium.

Downloaded study on the admission to the clinic in the direction of connective tissue diseases and infectious diseases were negative, and the chest X-ray was normal. Only RT23 were positive (above 26 mm). Mantoux tuberculin test could suggest that our patient had a contact with tuberculosis. That is way, after consultation with the radiologist and doctor

of infectious diseases, chest computed tomography was done. The result turned out to be correct. The patient was referred to a doctor of the infectious diseases.

Due to increases of IOP in the left eye to 40mmHg in the next days, not responding to medical treatment, we decided to perform cyclophotocoagulation of ciliary body. In view of sclera atrophy we performed the procedure of cyclophotocoagulation in low temporal quadrant. Probe with power of 2W done 18 pulses at an interval of 1,0s. In the following day the IOP in the left eye was about 24mmHg. Two weeks after procedure the IOP in the left eye was 20mmHg. The patient count fingers from 1 meter. The eye was not irritated. There was no engorgement of the iris vessels. The anterior chamber was deeper (Fig 3). Patient still applied Oftaquix and Tobradex drops five times a day, 1% Atropine drops three times a day, Combigan drops twice a day and oral acetazolamide three times a day one tablet. The fundus was the same as the first day patient's admission to the clinic.

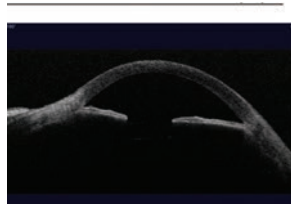


Figure 3. OCT Vistane of the left eye after phacoemulsification cataract surgery and cyclophotocoagulation of ciliary body.

Three months after cyclophotocoagulation of ciliary body the IOP in the left eye was 20mmHg.

## ★ DISCUSSION ★

Angle-closure glaucoma, resistant to treatment, may be associated with multiple ocular anomalies, in the course of various syndromes.

In our patient one of such as ocular anomaly was nanophthalmos. It is a bilateral, rare disorder, which is characterized by small hypermetropic eye, with axial length less than 20mm, with a shallow anterior chamber, narrow-angle glaucoma, in thick sclera and choroid and the correct volume of the lens<sup>(1)</sup>. The mechanism of angle closure glaucoma in nanophthalmos concerns "crowding angle glaucoma" secondary to the normal volume of the lens, but wrong to the size of the eye and anterior segment. This situation leads to the peripheral anterior synechiae (PAS) or iris adhesion to the trabecular meshwork, which restricts the flow of aqueous humour from the posterior chamber by the angle and produces pupillary block<sup>(1)(2)</sup>. Additionally, pupillary block could have been enlarged by pilocarpine, used by the patient for a long time. According to Kański one of the side effects of long-term application of miotics is paradoxical pupillary block. Pilocarpine moves forward lenticular-iridial diaphragm, which increases the anterior-posterior dimension and strongly narrows the pupil<sup>(3)</sup>. Another complication may be cataract<sup>(3)</sup>. Nanophthalmos may occur with Hallerman-Streiff Syndrome, retinitis pigmentosa and optic disc drusen<sup>(2)</sup>.

Next ocular malformation was coloboma of the optic disc. Optic disc coloboma is a defect of optic nerve, results from an abnormality of the closure of the foetal fissure in the inferonasal quadrant of the developing optic cup between 5 and 7 weeks of foetal life <sup>(4)</sup> <sup>(5)</sup>. This type of malformation is rare, which was confirmed by Taylor, where in 1.200 studied patients 0.25% optic disc coloboma was found. Disorder may be single or bilateral. Visual acuity does not depend on the appearance of the disc. Optic disc coloboma may be accompanied with iris, choroid, or lenses defects, as well as disorders of other organs (Trisomy 18i13, CHARGE Syndrome, Walker-Warburg Syndrome, Aicardi Syndrome, Goldenhara Syndrome)<sup>(5)</sup>. In this case such as diseases weren't found. Optic disc coloboma, which doesn't appear with disorders of the other organs are often sporadic or inherited in an autosomal dominant way with variable expression <sup>(5)</sup>. In patients with optic disc coloboma retinal detachment may occur, as well as the presence of nystagmus, as shown by Mirang Kim et al. examining children with congenital abnormalities of the optic nerve. In his work nystagmus occurred in 7 (43.8%) children on 16 subjects and retinal detachment occurred in 1 child <sup>(4)</sup>. Nakamura et al. described retinal detachment in only 6% of respondents (in 33 studied) <sup>(6)</sup>. These studies confirm that the retinal detachment in optic disc coloboma is rare. According to Brodsky eyes with isolated optic disc coloboma are more prone to serous detachment of the retina, while the optic coloboma occurs with choroid coloboma at rhegmatogenous retinal detachment<sup>(7)</sup>. Pilocarpine could also contribute to retinal detachment in our patients. Kański describes it as a one of the side effects of long term using of miotics <sup>(3)</sup>. Optic disc coloboma may be accompanied by persistent foetal vasculature, cataracts, Coquet canal anomalies, glial bands with dysplastic retina around the optic nerve head and glaucoma when anterior segment anomalies are presents<sup>(5)</sup>.

Next and the last ocular malformation, which was presented by our patient was persistent hyaloid artery. Usually it is a rare hereditary monocular disorder. It occurs in 3% of infants born at term, and in 90% of premature infants <sup>(8)</sup>. In severe cases, may occur nanophthalmos, angle-closure glaucoma and retinal detachment, as well as vitreous haemorrhage <sup>(9)</sup>.

Due to the advanced glaucomatous neuropathy, poor visual acuity, young age of the patient, long-term using of glaucoma drugs, we didn't decide to perform filtering procedure, because of high possibility of its atresia. We decided on cyclodestructive procedure. Schlot et al. have shown that in the case of inflammatory glaucoma, necrotizing episcleritis and sclera atrophy this treatment gives good results. In the present study IOP was significantly dropped in 17 eyes (77.3%) on 22 in the study<sup>(10)</sup>. Lin et al also presents good results of cyclodestructive procedure for refractory glaucoma <sup>(11)</sup>. As a complication of the procedure are described hypotension, intraocular haemorrhage, severe pain, decreased visual acuity and conjunctiva burns at the place of probe application<sup>(12)</sup>. We didn't observe any of them in our patient.

## ★ CONCLUSION ★

The mechanism of angle-closure glaucoma in our patient occurred as a result of different ocular malformations. On the one hand the patient had incorrect construction of the anterior segment, she applied for a few years miotics which paradoxically could lead to the closed angle and increased IOP. On the other hand, pathological structures presence in the posterior segment may also have an impact on the development of glaucoma. Considering the whole case of our patient we decided to perform the procedure of cyclophotocoagulation of ciliary body. The recent report in the literature emphasizes safety and predictability of the procedure. It is relatively cheap and may be performed in the refractory glaucoma <sup>(13)</sup>.

## ★ REFERENCES ★

1. Pamela Tarongou, Ching Lin Ho, FRCSEd, David S. Walton: Angle-closure Glaucoma: The Role of the Lens in the Pathogenesis, Prevention, and Treatment. *Survey of Ophthalmology*. Volume 54, Issue 2, March–April 2009, Pages 211–225.
2. Robert Ritch, Brian M Chang, Jeffrey M Liebmann: Angle closure in younger patients. *Ophthalmology*. Volume 110, Issue 10, October 2003, Pages 1880–1889
3. Jacek J. Kański, James A., McAllister, John F. Salmon: Glaucoma. A colour manual of diagnostic and treatment. Issue 1. Edited by M.H. Niżankowska. Urban and Partner. Wrocław. 1998:125
4. Mi Rang Kim, Sung Eun Park, and Sei Yeul Oh: Clinical Feature Analysis of Congenital Optic Nerve Abnormalities. *Jpn J Ophthalmol* 2006;50:250–255.
5. D Taylor: "Developmental abnormalities of the optic nerve and chiasm". *Eye* (2007) 21, 1271–1284
6. Kelly M. Nakamura, BS, Nancy N. Diehl, BS, and Brian G. Mohny, MD: Incidence, Ocular Findings and Systemic Associations of Ocular Coloboma: A Population-Based Study. *Arch Ophthalmol*. 2011 January; 129(1): 69–74
7. M.C. Brodsky: Congenital Optic Disc Anomalies. *Pediatric Neuro-Ophthalmology*. Chapter 2. Springer Science+Business Media, LLC 2010:71-74
8. Feyza Önder, C.Banu Coşar, Eser Gültan, Gülcan Kural: *Journal of American Association for Pediatric Ophthalmology and Strabismus*. Volume 4, Issue 3, June 2000, Pages 190–191
9. John W. Simon, Edward G. Buckley, Arlene V. Drack, Amy K. Hutchinson, David A. Plager, Edward L. Raab, Mark S. Ruttum, Aazy A. Aaby: Diseases of vitreous and retina. Basic and clinical science course. *Okulistyka pediatryczna i zez*. Volume 6, Issue 1, Urban and Partner Wrocław 2004. Chapter XXIV. Pages 325-326
10. Torsten Schlote, Matthias Derse, Manfred Zierhut: Transscleral diode laser cyclophotocoagulation for the treatment of refractory glaucoma secondary to inflammatory eye diseases. *Br J Ophthalmol* 2000;84:999–1003
11. Patty Lin, Gadi Wollstein, and Joel S. Schuman : Contact Transscleral Neodymium:Yttrium-Aluminum-Garnet Laser Cyclophotocoagulation: Long-term Outcome. *Ophthalmology*. 2004 November; 111(11): 2137–2143.
12. A Manna, P Foster, M Papadopoulos and W Nolan: Cyclo diode Laser in the treatment of acute angle closure. *Eye* (2012) 26, 742–745
13. Marta Misiuk-Hojto, Marcin Zieliński: Cyclophotocoagulation of ciliary body by diode laser as a treatment of glaucoma. *Okulistyka po dyplomie*. Medical Tribune Polska. Volume 2. Number 5(9), October 2012, Pages 22-24

.....  
Agnieszka Anna DYRDA

Parc de Salut Mar, Hospital de la Esperanza, Av. Santuari  
de Sant Josep de La Muntanya, 12, 08024, BARCELONA – SPAIN  
.....



.....  
**LATE HYPOTONY SECONDARY TO  
OVERFILTRATING DYSFUNCTIONAL  
BLEB : CLINICAL FEATURES AND  
RESULTS OF SURGICAL REPAIR**  
.....

**★ INTRODUCTION ★**

Late hypotony is an infrequent complication of filtration procedures and it is understood as structural and/or functional ocular change caused by hypotension ( $\leq 5\text{mmHg}$ )<sup>(1,2)</sup>. It can occur even many years after a successful glaucoma surgery. Trabeculectomy reduces the incidence of hypotony in comparison with full-thickness filtration or drainage implant procedures, but its results are not optimal<sup>(3-5)</sup>. The use of antimetabolites such as 5-fluorouracil (5-FU) and especially mitomycin C (MMC) promotes bleb formation, obtains lower IOP and improves success rate of glaucoma surgery<sup>(6-13)</sup>. However these adjunctive techniques may be associated with excessively low IOP and hypotony due to development of thin and dysfunctional avascular blebs<sup>(14-18)</sup>. We present a consecutive case-series study of clinical and surgical results of late hypotony after filtration procedures in patients with avascular blebs without leakage.

## ★ PATIENTS AND METHODS ★

The retrospective review of clinical charts of patients who underwent surgical bleb reconstruction secondary to late hypotony at our ophthalmology department between January 2008 and November 2012 is presented. Patients included in the study met the definition of late hypotony as hypotension after at least 3 months of a glaucoma filtration procedure associated to compatible structural and/or functional ocular changes. We excluded from the study patients who presented bleb leaks or oozing. Information regarding age, sex, type of glaucoma, initial filtration procedure and elapsed time to hypotony appearance, use of antimetabolites, clinical presentation of hypotony and its duration, bleb characteristic, surgical treatment and its result were analyzed.

### ► Surgical techniques (video)

As indicated in literature we decided to revise underlying scleral flap in all cases<sup>(19)</sup>. The choice of approach was based on pre- and intraoperative examination and was protocolized as follows:

1. Bleb excision with conjunctival advancement (with or without relaxing incisions) alone if no excessive flow from sclerostomy and correct scleral flap.
2. Bleb excision with conjunctival advancement (with or without relaxing incisions) and scleral patching if excessive flow from sclerostomy and deficiency of scleral flap. The scleral patch was tightly sutured anteriorly and laterally but left free in the posterior side to allow posterior aqueous outflow.

## ★ RESULTS ★

### ► Demographic characteristics (Table 1)

Only 4 cases of late hypotony due to over-filtrating blebs were diagnosed and operated in 4 years. 2 women and 2 men, all white, with mean age of  $73\pm 6,58$  years (range: 56-81) were included in the study. The glaucoma diagnosis was: primary open-angle glaucoma-POAG (n=2), exfoliation glaucoma-PXG (n=1) and pigmentary glaucoma (n=1).

The primary glaucoma procedures performed were: full-thickness sclerectomy+ extracapsular cataract extraction (n=1), facoemulsification+trabeculectomy (n=3) with the use of adjunctive MMC 0,2% for 2 min in two of them.

### ► Clinical features (Table 2)

Ophthalmology examination revealed hypotension of average IOP of  $1,5\pm 1\text{mmHg}$  (range: 0-2) and visual impairment in all cases with mean Best Corrected Visual Acuity (BCVA) of  $0,21\pm 0,06$  (0,15-0,3). The mean elapsed time from the antiglaucomatous surgery to appearance of hypotony was  $8,75\pm 5,91$  years (range:3-16).



The most frequent structural changes found at the time of diagnosis were hypotony maculopathy (n=3), followed by disc edema (n=1), choroidal detachment (n=1) and corneal edema (n=1). One of the patients with the shortest history of hypotony (3 weeks) presented all of mentioned findings: while the others one each.

At the time of presentation all the patients had dysfunctional blebs with avascular zone. The characteristics of avascular zone were: small (less than 1 hour) in 3 (75%) and large (more than 3 hours) in 1 case (adapted from Matsuo and al. 21). According to The Indiana Bleb Appearance Grading Scale all patients presented elevated and large blebs: H3 x E2,5 in average (fig.: Patient 1 and 2).

## Result of treatment

All patients were operated after failure of medical treatment. Surgical approach involved bleb excision with conjunctival advancement in all cases with re-suturing of scleral flap (n=1) or scleral patching (n=3). We observed spectacular resolution of structural changes in all cases already in the early postoperative period: corneal edema as well as choroidal detachment in 24 hours and macular folds in 2 and 5 days but the postoperative visual acuity (VA) improved only in 2 cases (50%) (fig.3). The two patients with VA improvement, gained 3 lines of VA achieving BCVA 0,4 and 0,5 respectively. One presented no structural changes at diagnosis and the other one had only 4-month of hypotony duration before the intervention. However, overall there was no significant difference in the mean time of hypotony and VA improvement (1,25 year vs. 1,04 year) (fig.:Patient 1 and 2).

## Post-surgical control of IOP (Table 3)

The mean follow up after reconstruction surgery was  $28,75 \pm 34,31$  weeks (range 1-76 wks). In the early post-surgical period ( $\leq 1$  month) the mean IOP was  $19,25 \pm 3,77$  mmHg. Although we don't have a late follow up for all patients, the two patients with long follow up available required suturolysis or needling with MMC 0.2%) as well as chronic topical medication in one of them to maintain IOP within target (mean  $15,25 \pm 4,92$  mmHg). As there was no glaucomatous progression observed during the follow-up we assumed good IOP control.

In immediate postsurgical period ( $\leq 1$  day) there were two cases of ocular hypertension (50%) with general and ocular symptoms that were resolved with medical treatment (20% mannitol and acetazolamide) and viscoelastic evacuation from anterior chamber.

## ★ DISCUSSION ★

To our knowledge the incidence or prevalence rate for postsurgical late hypotony secondary to overfiltration are not completely established. This retrospective study reports only 4 cases of late hypotony due to overfiltrating dysfunctional blebs in 4 years. Although the sample size is small due to the rarity of the pathology, the homogeneity of the group makes this descriptive analysis possible and interesting.

A variety of risk factors related to hypotony after filtration surgery have been described. One of them is age<sup>(22-24)</sup> because of ciliary body insufficiency in aged patients<sup>(1)</sup>, which overlaps the changes in appearance and function of filtering blebs over time<sup>(25)</sup>. The mean age of our group was 73±6,58 years which is not very old. Sex and type of glaucoma are not considered as a risk factor of hypotony.

The relation between type of filtering surgery and hypotony is well known, although the incidence is not well established due to differences in published studies<sup>(1)</sup>. The highest risk is linked to full-thickness surgery. The incidence after this procedure is really high (up to 41%) and when compared to partial-thickness almost 2:1<sup>(4)</sup>. In this small group there was one patient (25%) with full-thickness procedure.

Participation of antifibrosis agents especially MMC in mechanism of hypotony and in the associated maculopathy is confirmed in multiple animal and human experimental studies probably in a dose-exposure and time-dependent fashion<sup>(27-29)</sup>. The postulated mechanisms are: a direct effect on ciliary body and macula, suppression of aqueous humor flow and modelling effect on bleb architecture by inhibiting inflammatory and healing processes. Thin, cystic, avascular blebs are common after trabeculectomy with antifibrosis therapy, as it is likely to induce a hypocellular or acellular bleb with less fibrovascular proliferation<sup>(30)</sup>. Half of the patients of our group had had adjunctive therapy with MMC. Even though minimum time (2 minutes) and concentration (0,2%) were used, these two patients presented the largest avascular zone (mean 3,5 vs. 2) and notably shorter period (4years vs. 13,5years) between primary filtering procedure and development of symptomatic hypotony.

The most frequent structural change in our group was hypotony maculopathy that appeared in 3 of the 4 patients studied. However only one patient with macular folds had the typical risk factors<sup>(33)</sup>: male sex, youngest age and myopia (axial length of 25.15) and use of MMC. None of the other two patients had any of these related factors.

As described, some findings like corneal edema, flat anterior chamber and choroidal detachment are typical for acute presentation, others as disk and retinal (including maculopathy) hypotony due to the late onset of the hypotension. Nevertheless, coexistence of all those different signs in one of our patients was probably related to a background of chronic hypotony exacerbated by an acute IOP drop and subsequent VA reduction causing patient's consultation.

We observed spectacular resolution of all structural changes in different postoperative times : acute signs such as corneal edema and choroidal detachment were solved in 24 hours, whereas in the chronic ones like hypotony maculopathy needed up to 5 days. Macular folds disappearance was independent from time course (3 weeks vs. 2 years).

VA recovery was observed in only 2 patients. One of them had functional loss without evident structural changes. VA decrease is then caused by loss of proper curvature and refraction<sup>(1)</sup>. VA impairment may be the only symptom of ocular hypotony and restoration of normal IOP may result in recuperation of vision as seen in our patient. We also observed VA recovery (2 lines of Snellen) in one of patient with maculopathy of 4 months duration. The other two cases of maculopathy did not experience VA improvement. It is reported that recuperation of VA in hypotony maculopathy is possible even after many years (up to 7 years)<sup>(34)</sup>. Some of the patients had a very short follow (few weeks) so we cannot definitively reject the possibility of VA improvement. In the other hand, it may well be that irreversible damage has occurred so function cannot be re-established. Continued edema of the outer plexiform and inner nuclear layers of the retina may stimulate intraretinal gliosis, loss of ganglion cells, and photoreceptors, resulting in irreversible loss of visual function<sup>(1)</sup>. It is also seen at cellular level as altered physiology of aqueous flow and composition in hypotony compromise the metabolism<sup>(35)</sup>.

Surgical decision always should be individualized. Each case of hypotony related to overfiltration requires scleral flap revision to assess the scleral flow. This is a more complicated procedure than repair of bleb leaks and there is only little information about short- and long-term surgical repair<sup>(22,36)</sup>. The surgeon should always be prepared for possible scleral patch or conjunctival graft. Moreover, these patients are glaucomatous patients that were operated in first term to lower their IOP. Closing their filtering surgery can then lead them to ocular hypertension and worsen their glaucomatous damage. In our series, the surgical approach was protocolized facilitating decision taking and making results more comparable. This technique preserves posterior flow by leaving the posterior edge of scleral patch unsutured or by using only one suture in its posterior edge if flow is excessive. Long-term control of IOP was successful although we needed extra procedures to maintain it within target. We did not observed glaucoma progression but the follow up of the patients was really short and it is known that the good results of short-term follow up tends to fail in long-term follow up of surgical repair of dysfunctional blebs<sup>(19,22,26,36)</sup>.

## ★ CONCLUSION ★

In conclusion, it is important to take into account that successful glaucoma filtration procedures, especially with adjunctive antimetabolites, can have potentially visual-threatening complications like late hypotony even years after surgery. This problem is difficult to manage and often needs individually-approached surgical reconstruction involving conjunctival excision as well as adequate scleral patching to still achieve target IOP. Long-term follow-up of our operated patients is crucial to detect dysfunctional thin and avascular blebs that are more likely to develop this serious complication.

## ★ REFERENCES ★

1. Schubert HD. Postsurgical Hypotony: Relationship to Fistulization, Inflammation, Chorioretinal Lesions, and the Vitreous. *Surv Ophthalmol* 1996; 41:97-125
2. Siegfried CJ, Rosenberg LF, Krupin T, Jampol LM. Hypotony after glaucoma filtration surgery: mechanisms and incidence. *J Glaucoma* 1995; 4:63-9
3. Speath GL. A prospective, controlled study to compare the Scheie procedure with Watson's trabeculectomy. *Ophthalmic Surg* 1980; 11:688-94.
4. Blondeau P, Phelps CD. Trabeculectomy versus thermosclerectomy: a randomized prospective clinical trial. *Arch Ophthalmol* 1981; 99:810-6
5. Lewis RA, Phelps CD. Trabeculectomy versus thermosclerectomy. *Arch Ophthalmol* 1984; 102:533-6.
6. The Fluorouracil Filtering Surgery Study Group. Fluorouracil Filtering Surgery study one -year follow-up. The Fluorouracil Filtering Surgery Study Group. *Am J Ophthalmol* 1989; 108:625-35.
7. The Fluorouracil Filtering Surgery Study Group. Three-year follow-up of the Fluorouracil Filtering Surgery Study. *Am J Ophthalmol* 1993; 115:82-92.
8. The Fluorouracil Filtering Surgery Study Group. Five-year follow-up of the Fluorouracil Filtering Surgery Study. *Am J Ophthalmol* 1996; 121:349-66.
9. Kitazawa Y, Kawase K, Matsushita H, Minobe M. Trabeculectomy with mitomycin. A comparative study with fluorouracil. *Arch Ophthalmol* 1991; 109:1693-8.
10. Liebmann JM, Ritch R, Marmor M, Nunez J, Wolner B. Initial 5-fluorouracil trabeculectomy in uncomplicated glaucoma. *Ophthalmology* 1991; 98:1036-1041.
11. Araie M, Shoji N, Shirato S, Nakano Y. Postoperative subconjunctival 5 fluorouracil injections and success probability of trabeculectomy in Japanese: results of 5-year followup. *Jpn J Ophthalmol* 1992; 36:158-68.
12. Cheung JC, Wright MM, Murali S, Pederson JE. Intermediate- term outcome of variable dose mitomycin C filtering surgery. *Ophthalmology* 1997; 104:143-9.
13. Shields MB, Scroggs MW, Sloop CM, Simmons RB. Clinical and histopathologic observations concerning hypotony after trabeculectomy with adjunctive mitomycin C. *Am J Ophthalmol* 1993; 116:673-83.
14. Mietz H, Brunner R, Addicks K, Kriegelstein G. Histopathology of an avascular filtering bleb after trabeculectomy with mitomycin-C. *J Glaucoma* 1993; 2:266-70.
15. Nuyts RM, Felten PC, Pels E, Langerhorst CT, Geijssens HC, Grossniklaus HE, Greve EL. Histopathologic effects of mitomycin C after trabeculectomy in human glaucomatous eyes with persistent hypotony. *Am J Ophthalmol* 1994; 118:225-37
16. Beluea DA, Dan JA, Stamper RL, Lieberman MF, Spencer WH. Late onset of sequential multifocal bleb leaks after glaucoma filtration surgery with 5 fluorouracil and mitomycin C. *Am J Ophthalmol* 1997; 124:40-5.
17. Sihota R, Dada T, Gupta SD, Sharma S, Arora R, Agarwal HC. Conjunctival dysfunction and mitomycin C-induced hypotony. *J Glaucoma* 2000; 9:392-7.
18. Ashkenazi I, Melamed S, Avni I, Bartov E, Blumenthal M. Risk factors associated with late infection of filtering blebs and endophthalmitis. *Ophthalmic Surg* 1991; 22:570-4.
19. Feldman RM, Altaher G. Management of late-onset bleb Leaks *Curr Opin Ophthalmol* 2004; 15:151-4.
20. Budenz DL, Barton K, Tseng SC. Amniotic membrane transplantation for repair of leaking glaucoma filtering blebs. *Am J Ophthalmol* 2000; 130:580-8.
21. Matsuo H, Tamidokoro A, Suzuki Y, Shirato S, Araie M. *Am J Ophthalmol* 2002; 133: 456-462.
22. Wadhvani RA, Bellows AR, Hutchinson BT, Sutgical repair of leaking filtering blebs. *Ophthalmol* 2000; 107:1681- 7.
23. Geijn EJ, Lemij HG, de Vries J, et al. Surgical revision of filtration blebs: a follow-up study. *J Glaucoma* 2002; 11:300-5.
24. Schnyder CC, Shaarawy T, Ravinet E et al. Free conjunctival autologous graft for bleb repair and bleb repair and bleb reduction after trabeculectomy and non penetrating filtering surgery. *J Glaucoma* 2002; 11:10-16.
25. Schimek R, Spencer R: Cryopexy treatment of proliferative diabetic retinopathy. *Arch Ophthalmol* 1979; 97:1276- 80.
26. Radhakrishnan S, Quigley HA, Jampel HD, Friedman DS, Ahmad SI, Congdon NG, McKinnon S. Outcomes of surgical bleb revision for complications of trabeculectomy. *Ophthalmol* 2009; 116: 1713-8.
27. Gandolfi S, Vecchi M, Braccio L: Decrease of intraocular pressure after subconjunctival injection of mitomycin in human glaucoma. *Arch Ophthalmol* 113:582-585, 1995
28. Kee C, Pelzek, C, Kaufman P. Mitomycin C suppression of aqueous humor flow in cynomolgus monkeys (abstract). *Invest Ophthalmol Vis Sci* 35(Suppl):1889, 1994
29. LeChinger S, Becker B, Wax M. The effects of subconjunctival administration of mitomycin C on intraocular pressure (IOP) in rabbits (abstract). *Invest Ophthalmol Vis Sci* 33(Suppl):736, 1992
30. Azuara-Blanco A, Katz J. Dysfunctional filtering blebs. *Surv Ophthalmol* 1998; 43:93-126.
31. Mietz H, Arnold G, Kirchof B, et al. Histopathology of episcleral fibrosis after trabeculectomy with and without mitomycin C. *Graefes Arch Clin Exp Ophthalmol* 1996; 234:364-368.

32. Mietz H, Brunner R, Addicks K, Kriegelstein GK: Histopathology of an avascular filtering bleb after trabeculectomy with mitomycin C. *J Glaucoma* 1993; 2:266-270.
33. Fannin LA, Shiffman JC, Budenz DL. Risk Factors for hypotony maculopathy. *Ophthalmol* 2003; 110:1185-91.
34. Delgado MF, Daniels S, Pascal S, Dickens CJ. Hypotony maculopathy: improvement of visual acuity after 7 years. *Am J Ophthalmol* 2001; 132:931-3
35. Bito LZ: Physiologic aspects of glaucoma and its management in: Zimmerman T, Kooner, Sharir M (eds) *Textbook of Ocular Pharmacology*. Philadelphia, Lippincottt Raven (In press)
36. Al-Shahwan S, Al-Torbak AA, Al-Jadaan I, Omran M, Edward DP. Long-term follow up of surgical repair of late bleb leaks after glaucoma filtering surgery. *J Glaucoma* 2006; 15:432-6.

No	Sex	Race	Age	Type of glaucoma	Initial filtration surgery	MMC/5FU	Elapsed time
1	F	W	74	PG	FTS+ECCE	-	16yrs
2	F	W	81	POAG	FacoTrabe	-	11yrs
3	M	W	72	PXG	FacoTrabe	0,2%x2min	5yrs
4	M	W	65	POAG	FacoTrabe	0,2%x2min	3yrs

F-femine; M-masculine; PG-pigmentary glaucoma; POAG-primary open-angle glaucoma; GEX-exfoliation glaucoma; FTS+ECCE -full-thickness sclerectomy+extracapsular cataract extraction; FacoTrabe-facoemulsification+trabeculectomy

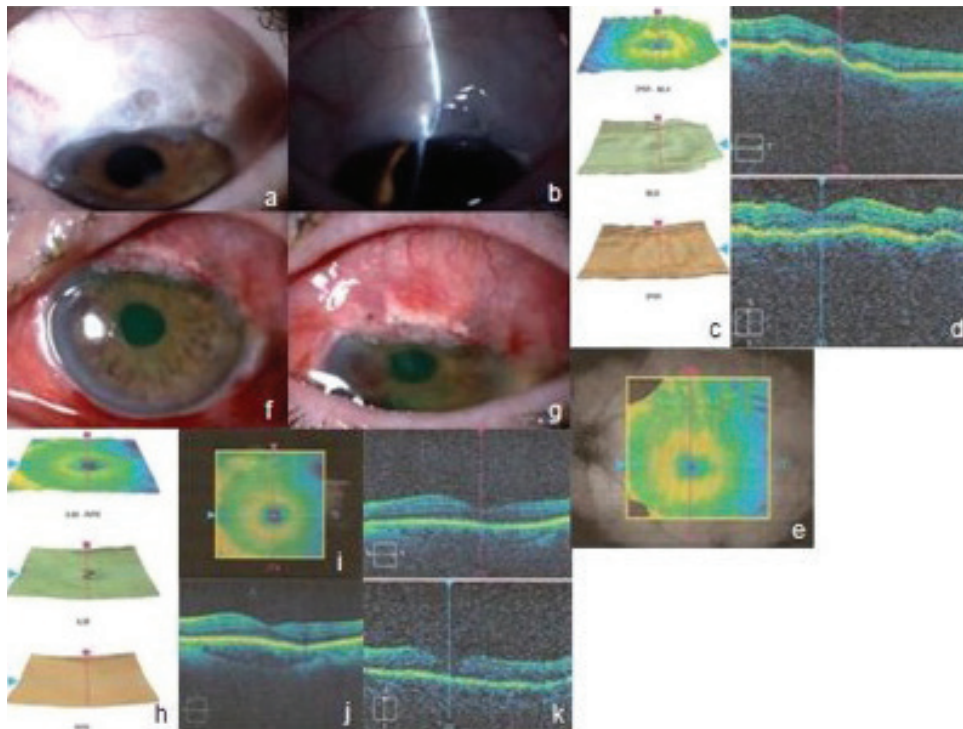
Bleb features	Clinical presentation	Hypotony duration	Over filtration	Height	Extent	Avascular zone	IOP	BCVA	Corneal edema	Hypotony maculopathy	Choroid detachment	Disc edema
2 yrs	+	3	2	2	2	0.3	-	+		-	-	
3 weeks	+	3	3	2	0	0.2	+	+		+	+	
1 yr	+	3	2	2	2	0.15	-	-		-	-	
1,5 yrs	+	3	3	4	2	0.2	-	+		-	-	

The Indiana Bleb Appearance Grading Scale: Height: H0:flat, H1: H2:moderate, H3>high; Extent: E0:low,≤1hr, E1:1-2hrs, E2:2-3hrs, E3≥4hrs; Matsuo: Avascular zone: 0: Absent, 1: localized, 2:small, 3:medium, 4:large; IOP-intraocular hypertension; BCVA-best corrected visual acuity

Surgical Approach	Structural resolution	BCVA	IOP early postop.	IOP late postop.	Additional procedure	Topical medication	Follow up
1	+	0.1	20	20	-	-	2 weeks
1	+	0.2	15	11	-	-	6 weeks
2	-	0.4	24	19	suturolysis	-	32 weeks
1	+	0.5	18	11	suturolysis	Timolol 0,5% 2/d	7b weeks

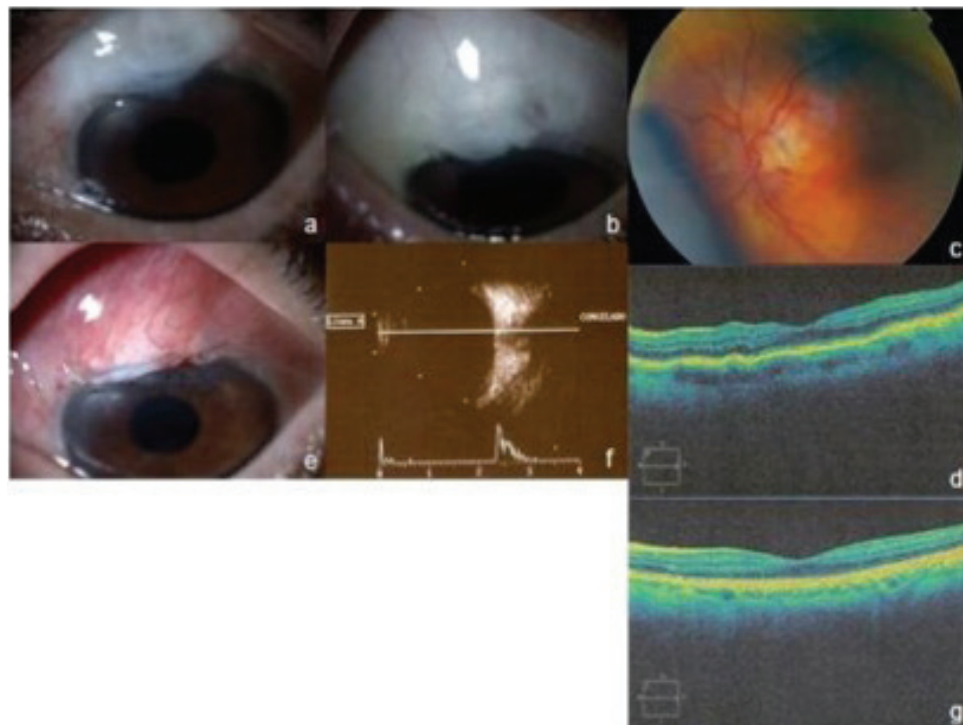
1-Bleb excision+scleral patch+conjuntival advancement; 2-Bleb excision+flap resuture+conjuntival advancement;

LATE HYPOTONY SECONDARY TO OVERFILTRATING DYSFUNCTIONAL BLEB :  
 CLINICAL FEATURES AND RESULTS OF SURGICAL REPAIR



Patient 1 : Late hypotony due to dysfunctional overfiltrating bleb (a, b) debut with BCVA 0.3, IOP 2mmHG and hypotony maculopathy (c-e).

The 2nd day after bleb excision with scleral patching and conjunctival advancement without relaxing incisions (f, g) with macular folds resolution (h, j). 2wks after surgery presented BCVA 0.1 and IOP 20mmHG



Patient 2 : Late hypotony due to dysfunctional overfiltrating bleb (a, b) debut with BCVA 0.2, IOP 0mmHG and structural changes as: corneal edema, choroidal detachment, disk edema<sup>®</sup> and hypotony maculopathy (d). The 1st day after bleb excision with scleral patching and conjunctival advancement without relaxing incisions (e) there was a complete resolution of choroidal detachment (f) and macular folds disappeared on the 3rd day (g). 6 wks after surgery presented BCVA 0.2 and IOP 15mmHG.



.....  
**NEOVASCULAR GLAUCOMA  
SECONDARY TO BRANCH  
RETINAL VEIN OCCLUSION**  
.....

★ **INTRODUCTION** ★

Neovascular glaucoma (NVG) is a relatively common and serious condition that occurs as a result of neovascularization in the anterior segment of the eye. It is a secondary glaucoma caused by the growth of fibrovascular membrane at the cameral angle, which appears after the angiogenic stimulus generated by ocular ischemic pathologies and only 3% of cases of non-ischemic pathology, inflammatory diseases generally<sup>1</sup>, such as multiple sclerosis<sup>2</sup>. Retinal ischemia leads to the production of vasoproliferative growth factors in an attempt to revascularize these hypoxic areas and they diffuse into the anterior segment and are responsible for neovascularization of the iris (NVI) and anterior chamber angle.<sup>2</sup>

Among vascular disorders, the most frequent cause of NVG is the central retinal vein occlusion, which is believed to be responsible for 36% of cases<sup>3</sup> and less frequently an occlusion of a branch retinal vein, which accounts for 2'4% of the cases according with the SCORE study<sup>4</sup>.

## ★ CASE REPORT ★

Male patient, fifty-six years old, followed due dry eye syndrome secondary to chronic graft versus host disease.

His personal history included : bronchial asthma treated with fluticasone/salmeterol inhaler, acute myeloid leukemia treated with bone marrow transplantation in the previous year and chronic graft versus host disease secondary. He was being treated with prednisone, acyclovir, fluconazole, sulfamethoxazole / trimethoprim, ranitidine and oral cyclosporine. He had no personal or family history of glaucoma and began treatment in our clinic with topical timolol 0.5% in the left eye by presenting high levels of intraocular pressure (IOP).

In the initial examination, visual acuity (VA) without correction was 0'4 improving with stenopeic to 0'6 in both eyes (OU), he had rubeosis iridis affecting pupillary sphincter 360° in the left eye (OS), the IOP was 24 mm Hg and pachymetry was 505 microns in the OS. An open angle Shaffer grade IV with neovessels 360° was observed in the gonioscopy of OS. The fundoscopic examination under mydriasis showed venous obstruction of the superior temporal vascular arcade, which was confirmed by intravenous fluorescein angiography (IVFA).

A diagnosis of NVG secondary to branch retinal vein occlusion (BRVO) was established and treatment with brimonidine was initiated.

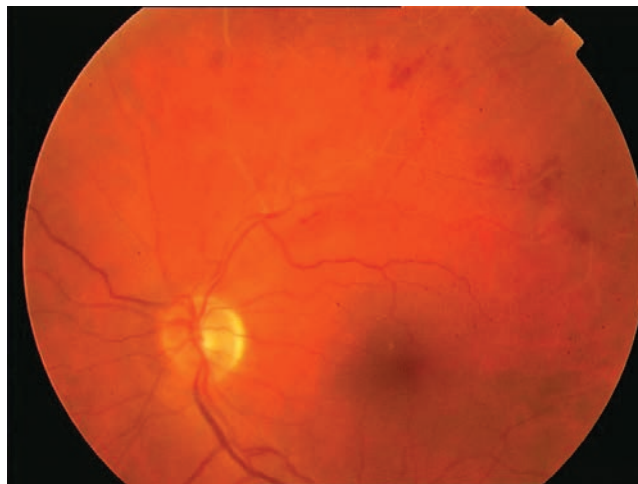


Figure 1. Fundus retinography of the left eye. Obstruction in the superotemporal vascular venous arcade is observed.



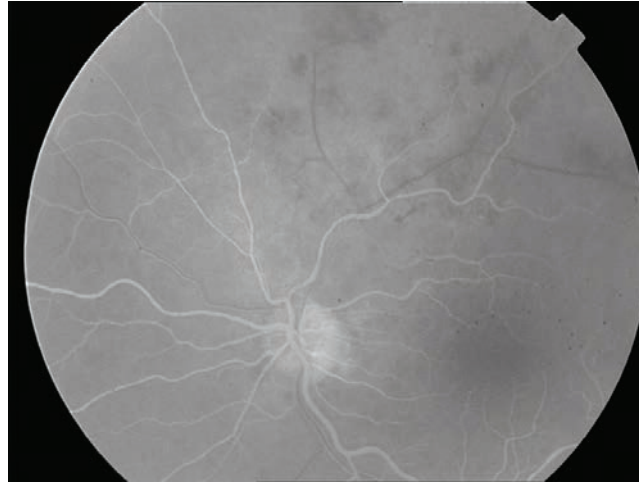


Figure 2. Fluorescein angiography of the left eye. Early arteriovenous phase with choroidal hypofluorescence in superior-temporal vascular arcade

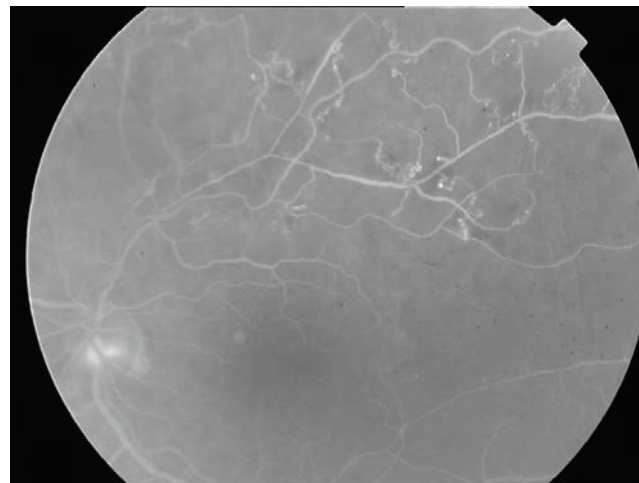


Figure 3. Fluorescein angiography of the left eye. Late stage with hyperfluorescence and exudation of retinal neovascularization.

Retinal photocoagulation with argon laser was performed in the superior temporal hemiretina, and fifteen days later the rubeosis iridis had disappeared and IOP had decreased to 14 mm Hg, so hypotensive topical treatment was interrupted.

Two months after laser treatment, recurrence of the NVI was observed, a large retinal hemorrhage in superior temporal periphery appeared, and the IOP had risen to 27 mm Hg in OS.

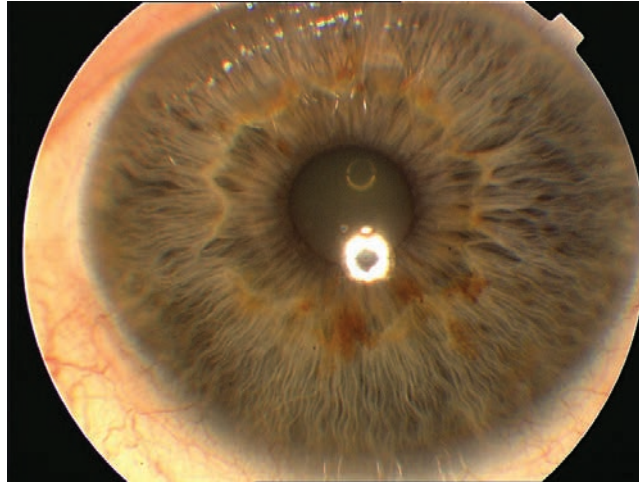


Figure 4. Anterior segment photograph of the left eye. Iris neovessels are observed in pupillary sphincter (white arrows).

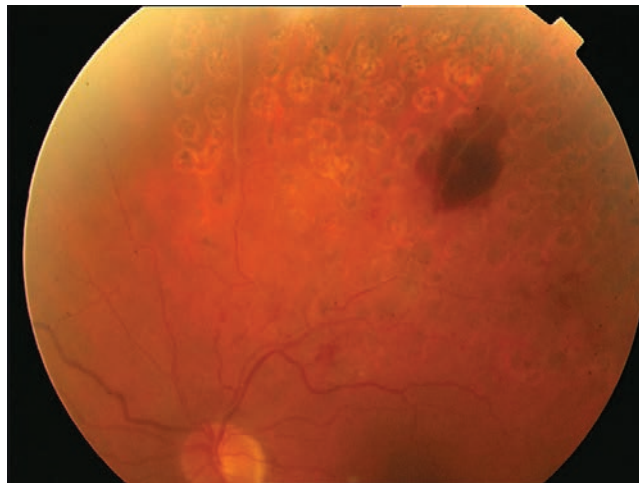


Figure 5. Retinography of the left eye. Retinal photocoagulation scars are seen in superior temporal area with intraretinal hemorrhage.

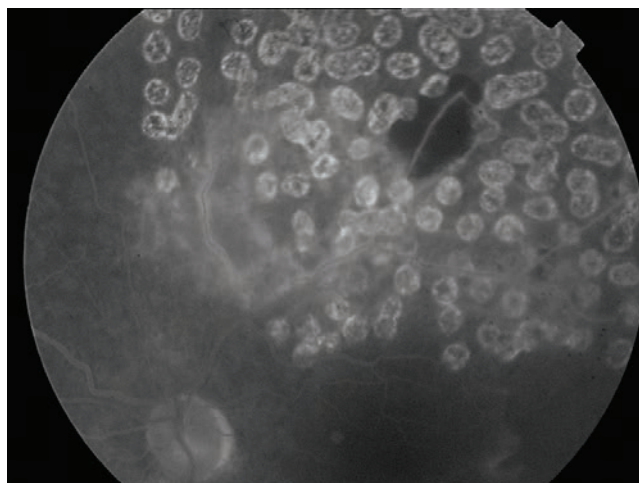


Figure 6. Fluorescein angiography of the left eye. Late stage: sectoral photocoagulation scars and leakage in the superotemporal vascular arcade.

Due to the new signs of activity, treatment with topical brimonidine was restarted, and additional laser was applied in the superior hemiretina. Also, a single dose of intravitreal pegaptanib was administered, with complete regression of the neovascularization in the anterior segment and without signs of retinal ischemia.

Nowadays, after three years of follow-up, the patient presents a corrected VA of 0.9 in OS, an IOP of 17 mm Hg without topical hypotensive treatment, and iris nor angle neovascularization had recurred.

## ★ DISCUSSION ★

The NVG may appear in the context of an ischemic central retinal vein occlusion (CRVO), a multiple BRVO (affecting large areas of the retina), or other ischemic retinal pathology associated with BRVO. It has been suggested that the neovascular glaucoma may result from the binding of the retinal ischemia with cerebrovascular insufficiency, which may contribute to the global ocular ischemia, and therefore also to the participation of the vascular structures of the anterior segment<sup>5</sup>.

Most patients with retinal vein occlusion also present other systemic disorders (eg, hypertension, hyperlipidemia, blood hyperviscosity<sup>6</sup> and / or diabetes mellitus<sup>7</sup>). There have been reports of severe hypercholesterolemia in patients with chronic graft versus<sup>7</sup> host disease (GVHD) following allogeneic hematopoietic stem cells transplantation. There was no association with a particular age, sex, type of hematologic malignant neoplasia, or using of an immunosuppressive drug specifically<sup>8</sup>. Hyperlipidemia is due to high concentrations of low density lipoprotein and in some cases may require treatment with plasmapheresis. Control of liver involvement in GVHD might improve or completely resolve hyperlipidemia.

The BRVO generally has a favorable prognosis although it depends on the site of occlusion, the caliber of the occluded vein and degree of venous obstruction<sup>9</sup>. The probability of success with argon laser treatment are higher than in the CRVO<sup>10</sup>.

VEGF is synthesized by the ischemic retina, and its destruction decreases the oxygen demand and the production of this factor. The argon laser photocoagulation of the ischemic retina presents few complications if performed in the appropriate time with an optimum wavelength. Other retinal ablative treatments can be used, such as cryotherapy, transscleral diode laser or pars plana vitrectomy with endophotocoagulation in cases of poor fundus visualization.

The anti-VEGF therapy has been used as off-label treatment in NVG to stop neovascular proliferation and to induce the regression of iris and angle neovascularization. It can also improve IOP control preventing angle closure by anterior synechiae.

## ★ CONCLUSION ★

In patients with retinal vein occlusion, it is very important to perform a systemic study, since most of them will have general disorders associated. In our case, hypercholesterolemia associated with chronic GVHD could be an etiopathogenic factor of first order.

The most common causes of vision loss in BRVO are chronic macular edema and retina or optic nerve neovascularization, leading to recurrent vitreous hemorrhages<sup>11</sup>, but development of NVG is highly improbable because it requires a large angiogenic stimulus. The main factor which influences the development of ocular neovascularization seems to be the severity and extent of retinal ischemia and the time elapsed since the beginning of the process.

Argon laser photocoagulation of the ischemic retina is considered the elective treatment to eliminate the angiogenic stimulus, which was effective in our case.

The anti-VEGF drugs, such as intravitreal pegaptanib, also used in this case, induce the regression of the neovascularization eliminating the angiogenic stimulus, and also help to control IOP.

## ★ REFERENCES ★

1. Ruiz-Casas D, Cabarga-Nozal C, Muñoz-Negrete FJ. *Glaucoma neovascular*. *Studium Ophthalmologicum* - Vol. XXVIII - N° 4 - 2010: 161-172.
2. Turner SJ, Dharmasena A, Deane J. *Bilateral rubeosis iridis and rubeotic glaucoma due to peripheral occlusive vasculitis associated with multiple sclerosis*. *Ocul Immunol Inflamm*. 2011 Oct;19(5):373-5. Epub 2011 Sep 6.
3. Kanski JJ (2009). *Oftalmología clínica 6ª edición*. Barcelona: Elsevier España.
4. Chan CK, Ip MS, Vanveldhuisen PC, Oden NL, Scott IU, Tolentino MJ, Blodi BA; SCORE Study Investigator Group. *SCORE Study report #11: incidences of neovascular events in eyes with retinal vein occlusion*. *Ophthalmology*. 2011 Jul;118(7):1364-72. Epub 2011 Mar 26.
5. Lodato G, Brancato G. *Neovascular glaucoma caused by branch vein occlusion and deficiency of carotid-encephalic circulation: pathogenetic correlation*. *J Fr Ophtalmol*. 1984;7(10):615-21.
6. Zhang HR, Xia YJ. *Risk factors and visual prognosis of 407 patients with retinal vein occlusion*. *Zhonghua Yan Ke Za Zhi*. 1991 Sep;27(5):271-4.
7. Rehak M, Wiedemann P. *Retinal vein thrombosis: pathogenesis and management*. *J Thromb Haemost*. 2010 Sep; 8(9):1886-94. doi: 10.1111/j.1538-7836.2010.03909.x.
8. Joukhadar R, Chiu K. *Severe hypercholesterolemia in patients with graft-vs- host disease affecting the liver after stem cell transplantation*. *Endocr Pract*. 2012 Jan-Feb;18(1):90-7.
9. Reháč J. *Retinal vein occlusion II. Clinical picture and photocoagulation therapy*. *Cesk Oftalmol*. 1992 Mar;48(2):127-31.
10. Sun XQ. *Analysis of 52 cases of retinal vein occlusion treated with laser photocoagulation*. *Zhonghua Yan Ke Za Zhi*. 1991 Sep;27(5):275-8.
11. Haçreh SS, Rojas P, Podhajský P, Montague P, Woolson RF. *Ocular neovascularization with retinal vascular occlusion-III. Incidence of ocular neovascularization with retinal vein occlusion*. *Ophthalmology*. 1983 May;90(5):488-506

Alicia MUÑOZ-GALLEGO

"12 de Octubre" Hospital, Avenida de Córdoba  
s/n 28041 MADRID – SPAIN



## MALIGNANT GLAUCOMA AFTER DIAGNOSTIC MYDRIASIS IN A PATIENT WITH PSEUDOEXFOLIATION SYNDROME AND CENTRAL RETINAL VEIN OCCLUSION

### ★ INTRODUCTION ★

Pseudoexfoliation (PEX) syndrome is a systemic disease associated with variants in the lysyl oxidase-like 1 gene, that leads to an abnormal production and (or) turnover of extracellular matrix material <sup>[1, 2]</sup>. Nowadays, only the intraocular changes can be diagnosed with non-invasive methods <sup>[2]</sup>. PEX is recognized by the presence of white fibrinogranular deposits on anterior segment structures: anterior lens capsule, papillary margin, zonules, ciliary body, trabecular meshwork, and the endothelial surface of the cornea <sup>[2]</sup>.

The association between glaucoma and PEX has been mainly reported as the open-angle type (PAOG), and primary angle-closure glaucoma (PACG) has been considered much less common <sup>[2, 3]</sup>. Ritch found a 25% prevalence of PEX in patients with PACG. He postulated that exfoliation syndrome predisposes the development of angle closure. Gross et al., concluded that the overall prevalence of PACG in PEX is 2.2%, while the prevalence in an age-matched Caucasian population is 0.1-0.2%. Layden and Shaffer, reported a 23% incidence of occludable angles in PEX cases compared with a 5% incidence in the normal population <sup>[2]</sup>.

The mechanism than produces angle-closure glaucoma in patients with PEX is unknown, but different mechanisms have been postulated <sup>[2]</sup> :

- Posterior synechia.
- A thick or a rigid iris.
- Zonular weakness.
- Enlargement of the lens due to cataract formation.

Damji et al. suggested that cataract formation and (or) zonular weakness may contribute to the development of an occludable angle in eyes with PEX. They also observed that, in patients with PEX, a shallow central anterior chamber depth (ACD) was associated with occludable angles [2].

The Rotterdam Study showed that the prevalence of narrow anterior chamber angles is 2% in nonselected white subjects of 55 years of age or older. It concluded that only about 1 in 3,000 subjects is likely to develop an acute angle-closure glaucoma (AACG) after the use of tropicamide 0.5% and phenylephrine 5% eye drops [4]. Women were twice as likely as men to have a narrow anterior chamber angle. It has also been described that the risk of narrow anterior chamber angle increases with age [4].

Eyes with open anterior chamber angles on gonioscopy can still develop AACG after mydriasis. Gonioscopy seems to have limited value in predicting which eyes will develop AACG as a consequence of pupillary dilatation [4].

Another cause of acute glaucoma may be malignant glaucoma, which is diagnosed when there is shallowing of the central (axial) anterior chamber, increased intraocular pressure (IOP) and normal posterior segment anatomy [5]. This condition is also known as ciliary block glaucoma, aqueous misdirection syndrome and direct lens-block glaucoma [5].

Malignant glaucoma occurs in 2-4% of eyes undergoing surgery for PACG and may occur at any time following surgery, from the first postoperative day to many years later [6]. The literature contains isolated case reports of malignant glaucoma in nonsurgical situations (laser treatment, use of miotics, trabeculectomy bleb needling, infection, retinopathy of prematurity, retinal detachment, retinal vein occlusion and trauma) or spontaneously [5, 7]. The precipitating mechanism of malignant glaucoma in these cases is unclear [5].

The first step for the treatment of malignant glaucoma is medical therapy, including cycloplegia, topical drops (beta-blockers, alpha agonists and steroids) and systemic therapy (acetazolamide and osmotic agents). If there is no response, then if the patient is pseudophakic or aphakic, Nd-Laser YAG capsulotomy should be done and, if the patient is phakic surgery should be performed [5].

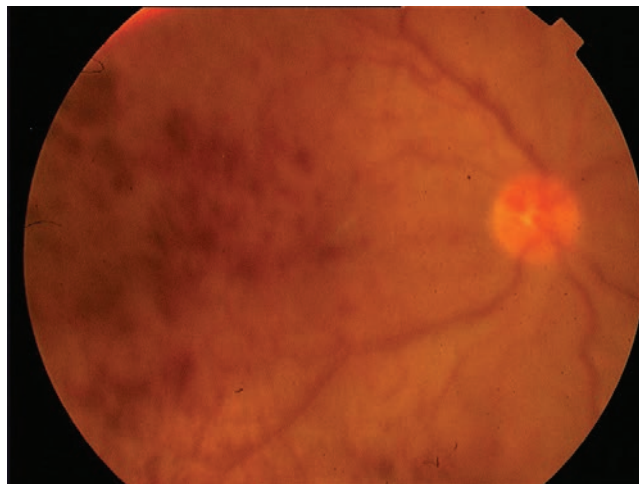
## ★ CASE REPORT ★

We present an 83-year-old Caucasian woman who was referred to our service with a complaint of gradual vision loss in her right eye.

On examination, her visual acuity was worse than 20/200 in the right eye and 20/50 in the left one. Anterior segment examination showed in both eyes: iris sphincter atrophy, cataract and pseudoexfoliative deposits on the pupillary border of the iris. Both eyes had normal ACD at slit lamp examination. IOP was 21 mm Hg in the right eye and 22 mm Hg in the left one.

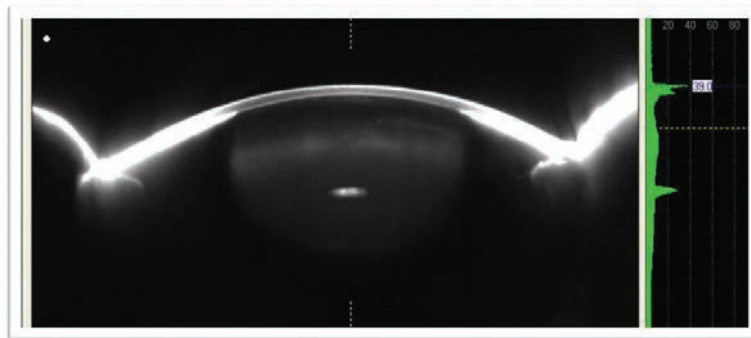
Tropicamide 0.5% and phenylephrine 5% eye drops were used in both eyes for diagnostic mydriasis.

Fundus examination demonstrated a central retinal vein occlusion in her right eye. The funduscopy of the left eye was normal.



At slit-lamp examination, both eyes presented pseudoexfoliative deposits on the anterior lens capsule and nuclear and posterior polar cataract.

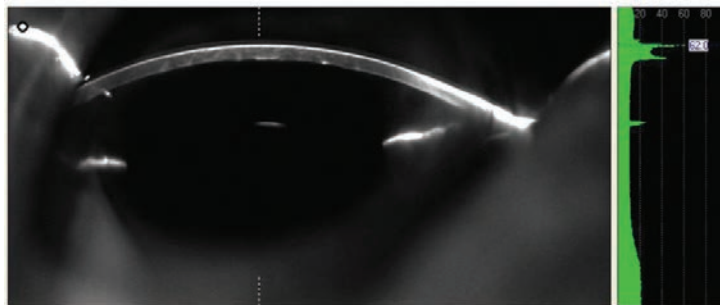
The day after the first examination, the patient came to our service with a complaint of severe pain in her right eye, nausea and vomiting since the night before. The anterior segment examination showed an overall shallowing of the central anterior chamber with elevated IOP. Scheimpflug imaging was made with Pentacam and evidenced a forward displacement of the lens-iris diaphragm, an ACD of 1 mm and a volume of the anterior chamber of 39 mm<sup>3</sup>. Funduscopy was similar to the previous day.



Treatment with topical drops (beta-blockers, alpha agonists, steroids and mydriatics) and systemic drugs, including oral acetazolamide and intravenous mannitol, could not control the disease. The patient was diagnosed of ciliary block glaucoma in her right eye.

Laser therapy could not be performed because the patient was phakic. That is the reason why 25G vitrectomy and reposition of anterior chamber with balanced sterile saline solution was performed the next day without complications. The day after the surgery, the patient was asymptomatic but the slit lamp examination demonstrated again an overall shallowing of the anterior chamber with elevated IOP. Therefore, we decided to perform cataract surgery. When phacoemulsification was finished, detachment of the zonula and a posterior lens capsule rupture was observed, so we decided not to implant an intraocular lens. Anterior vitrectomy and a peripheral iridotomy were performed without complications.

After these treatments, Scheimpflug imaging showed aphakia, an ACD of 2.71 mm and a volume of the anterior chamber of 343 mm<sup>3</sup>.



At her last follow-up, 10 months after the episode, IOP was controlled without any treatment and there have not been more episodes of shallowing of the anterior chamber.



## ★ DISCUSSION ★

Mapstone concluded that tropicamide and phenylephrine seemed to have lowest risk of causing AACG. He suggested that high-risk eyes should never be dilated with cyclopentolate [8]. Our patient was dilated with phenylephrine and tropicamide.

The use of mydriatics, which is our case, is not considered as a risk factor for the development of malignant glaucoma. However, it has been described the relationship between the use of miotics or the tapering of the dose of mydriatics and malignant glaucoma [5, 9].

Many pathogenic mechanisms for the development of malignant glaucoma have been described. Chandler proposed that laxity of the lens zonules coupled with pressure from the vitreous leads to forward lens movement producing a vicious circle in which the higher the pressure in the posterior segment, the more firmly the lens is held forward [5]. Other authors suggested that any process that hydrates the vitreous, such as transudation of fluid after central retinal vein occlusion, can result in forward movement of the lens-iris diaphragm, causing angle-closure glaucoma with peripheral and axial shallowing of the anterior chamber [9]. We think that the mechanism of malignant glaucoma in our patient was zonular instability secondary to PEX that, coupled with nuclear cataract produced forward displacement of the lens-iris diaphragm. The presence of a previous central retinal vein occlusion could contribute to the development of ciliary block glaucoma.

There was not response to medical therapy and laser therapy could not be done because the patient was phakic. That is the reason why we decided to operate the patient. As it is described above, the patient was phakic and the ACD was 1mm, hence phacoemulsification was highly difficult to perform. Because of that, we decided to make a 25G pars plana vitrectomy with reposition of the anterior chamber with balance sterile saline solution with poor results. This surgical procedure is usually successful in aphakic and pseudophakic eyes, but a 50% rate of recurrent or persistent malignant glaucoma and postoperative cataract formation has been reported in phakic eyes, which leads to lensectomy [10]. Our patient suffered a recurrence of the disease after vitrectomy, so cataract surgery was needed, but it was complicated and we decided to leave the eye in aphakia. Secondary intraocular lens implantation was rejected because of the poor visual prognosis, the age of the patient and the possibility of malignant glaucoma recurrence in pseudophakic eyes.

## ★ CONCLUSION ★

We present a rare case of acute malignant glaucoma precipitated by mydriasis in a patient with pseudoexfoliation. PEX could be a risk factor for the development of malignant glaucoma because zonular instability may facilitate forward displacement of the lens-iris diaphragm.

We suggest that vigilance for the development of occludable angles should be done in patients with PEX. If an occludable angle is diagnosed by gonioscopy, laser iridotomy should be done. Although it is extremely rare, eyes with normal or deep anterior chamber and open angle, can also develop acute IOP elevation due to forward displacement of the lens-iris diaphragm and ciliary block, which is the case described above.

The main cause of acute glaucoma after diagnostic mydriasis is angle-closure glaucoma, but all risk factors have poor predictive value. Because of that, we might warn patients about the symptoms of AACG after mydriasis. However, if any risk factor is described in the ophthalmological examination, we should avoid the use of cyclopentolate drops. Nevertheless, the fear of precipitating AACG should not affect the decision to dilate to perform precise funduscopy.

## ★ REFERENCES ★

1. Damji KF, Chialant D, Shah K, Kulkarni SV, Ross EA, Al-Ani A, et al. Biometric characteristics of eyes with exfoliation syndrome and occludable as well as open angles and eyes with primary open-angle glaucoma. *Can J Ophthalmol.* 2009;44:70-5.
2. Naumann GO, Schlötzer-Schredart U, Kuchle M. Pseudoexfoliation syndrome for the comprehensive ophthalmologist. Intraocular and systemic manifestations. *Ophthalmology.* 1998;105:951-68.
3. Gross FJ, Tingley D, Epstein DL. Increased prevalence of occludable angles and angle-closure glaucoma in patients with pseudoexfoliation. *Am J Ophthalmol.* 1994;117:333-6.
4. Wolfs RC, Grobbee DE, Hofman A, de Jong PT. Risk of acute angle-closure glaucoma after diagnostic mydriasis in nonselected subjects: The Rotterdam Study. *Invest Ophthalmol Vis Sci.* 1997;38:2683-87.
5. Shahid H, Salmon F. Malignant glaucoma: a review of the modern literature. *J Ophthalmol.* 2012;2012:852659.
6. Ruben S, Tsai J, Hitchings R. Malignant glaucoma and its management. *Br J Ophthalmol.* 1997;81:163-7.
7. Weber PA, Cohen JS, Baker ND. Central retinal vein occlusion and malignant glaucoma. *Arch Ophthalmol.* 1987;105:635-6.
8. Mapstone R. Safe mydriasis. *Br J Ophthalmol.* 1970;54:690-2.
9. Zaltas MM, Schuman JS. Malignant glaucoma: theory and therapy, from past to present. *Semin Ophthalmol.* 1994;9:243-7.
10. Byrnes GA, Leen MM, Wong TP, Benson WE. Vitrectomy for ciliary block (malignant) glaucoma. *Ophthalmology.* 1995;102:1308-11.



.....

**THE INFLUENCE OF MEIBOMIAN GLAND  
DYSFUNCTION AND OCULAR SURFACE  
DISEASE ON INTRAOCULAR PRESSURE  
CONTROL IN A 83-YEAR PATIENT WITH  
PRIMARY OPEN ANGLE GLAUCOMA: A CASE  
REPORT**

.....

**★ INTRODUCTION ★**

Primary open angle glaucoma is generally bilateral chronic disease of adult onset characterized by elevated intraocular pressure, anatomically open anterior angle pressure, glaucomatous optic nerve damage and characteristic visual field loss. Primary open angle glaucoma is the most prevalent type of glaucoma of European ethnic origin. Both sexes are affected equally. Routine ophthalmological examination should include evaluation of visual acuity, slit-lamp examination, tonometry (prior to pachymetry for CCT), optic disc examination, gonioscopy and optic disc or peripapillary RNFL. The primary aim of treatment is to prevent functional impairment of vision during the patient's lifetime by slowing the ganglion cell loss. Currently the only proven method is the lowering of IOP. The treatment includes medical treatment, laser trabeculoplasty or surgery. The rate of progression in patients with glaucoma varies significantly.

Meibomian gland dysfunction is a chronic, diffuse abnormality of the meibomian glands, commonly characterized by terminal duct obstruction and/or qualitative/quantitative changes in the glandular secretion. It may result in alteration of the tear film, symptoms of eye irritation, clinically apparent inflammation, and ocular surface disease. The symptoms of meibomian gland dysfunction are the result of an impaired quantity or quality of meibum supplied to the ocular surface. A number of factors have been identified which coexist with meibomian gland dysfunction and, whilst causal links have not been proven, plausible mechanisms exist for connecting them with the pathophysiology of meibomian gland dysfunction, is, anterior blepharitis, contact lens use, Demodex mite infestation, and dry eye disease. In addition, hormonal conditions such as menopause and androgen deficiency might contribute to the illness, as could rosacea, psoriasis, atopy, and hypertension. Clinical manifestations of meibomian gland dysfunction can range from the barely perceptible to serious and sight-threatening changes in the ocular epithelium. The predominant symptoms are related to dry eye, of which meibomian gland dysfunction is a major cause.

Eyelid hygiene is considered the mainstay of clinical treatment for meibomian gland dysfunction. Reliable and controlled heating will melt meibum and facilitate its release by massage and cleansing. In our case report we try evaluate the influence of blepharitis and ocular surface disease and its adequate treatment on intraocular pressure control in a 83- year patient with primary open angle glaucoma.

### ► Literature review :

1. Jack J. Kanski, Clinical Ophthalmology : A Systemic Approach – May 2011 Edition
2. Terminology and Guidelines for Glaucoma, Third Edition, European Glaucoma Society
3. Basic and Clinical Science Course (BCSC) : Glaucoma Section 10

## ★ CASE REPORT ★

We describe a 77-year female caucasian patient with advanced open angle glaucoma diagnosed over twenty years ago. The patient had been treated topically with a prostaglandin analogue (latanoprost), a beta blocker (timolol) and a carbonic anhydrase inhibitor (dorzolamide) for the past three years. The patient underwent regularly bilateral routine ocular examination including measurement of IOP, Heidelberg retina tomography (HRT II), GDX (Vcc), Humphrey visual field testing, CCT (within normal limits). Disc parameters were; cup to disc ratio - 0,8, mean RNFL thickness: 0,25, disc area : 2,0, cup area: 0,91 (pic1, pic2, pic3, pic4, pic5). The mean IOP about 15mmHg during this period. In daily tonometric curve the daily IOP fluctuations were estimated at 4mmHg. Patient manifested severe meibomian gland dysfunction and ocular surface disease. Additionally the patient had significant cardiovascular risk factors, so before proposing a filtering surgery, the decision had been taken to treat eyelids and ocular surface disorders, in purpose to improve the mean IOP level. We used the modality, in which the patient was treated with 1,5% azithromycin twice a day for three days then at bedtime for the rest of the month and completed with the use of Blephaclean wipes twice a day followed by a 3-month maintenance use (once a day) and topically 0,15% hyaluronic acid 3-4 times a day. Tear film and ocular surface examination included tear osmolarity measurement (Tear Lab Osmolarity System OcuSense). Tear osmolarity test and the confoscan examination (Nidek CS4) have been performed before treatment (pic6), 1 month, and 3 months (pic7) after the beginning of treatment. Antiglaucoma drugs of the patient were continued during the follow-up period. After three months the average IOP was 13,3mmHg, and after 6 months 13,1mmHg. Both tear osmolarity and confoscan confirmed the general improvement of tear film and corneal epithelium quality.

## ★ DISCUSSION ★

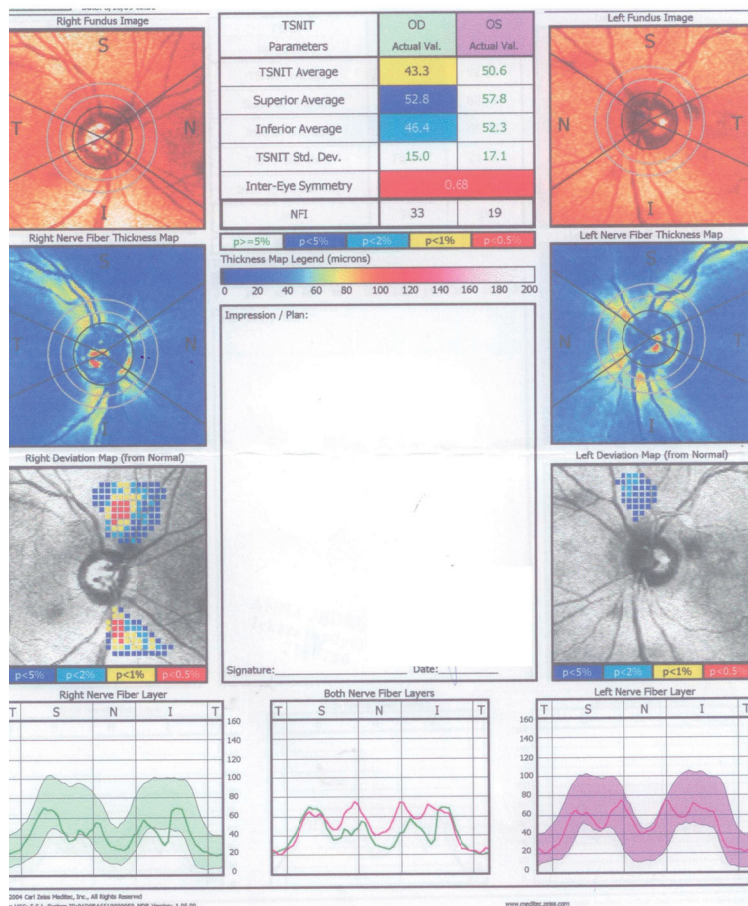
Some recent studies suggest that an adequate management of ocular surface disease and blepharitis may lead to a better IOP control in patients with primary open angle glaucoma. Such approach results not only in a significant improvement in the ocular surface with a reduction of hyperemia, meibomian gland dysfunction or superficial keratopathy, but also in reduction of the IOP. Additionally it is proven that any filtering surgery may be compromised in patients with ocular surface disorder due to profound changes of conjunctiva and ocular surface at the histological and molecular level. A postulate that a proper treatment of ocular surface disease and meibomian gland dysfunction can lead to an improvement of the IOP control and a better management of the primary angle glaucoma, might be legitimate.

## ★ CONCLUSION ★

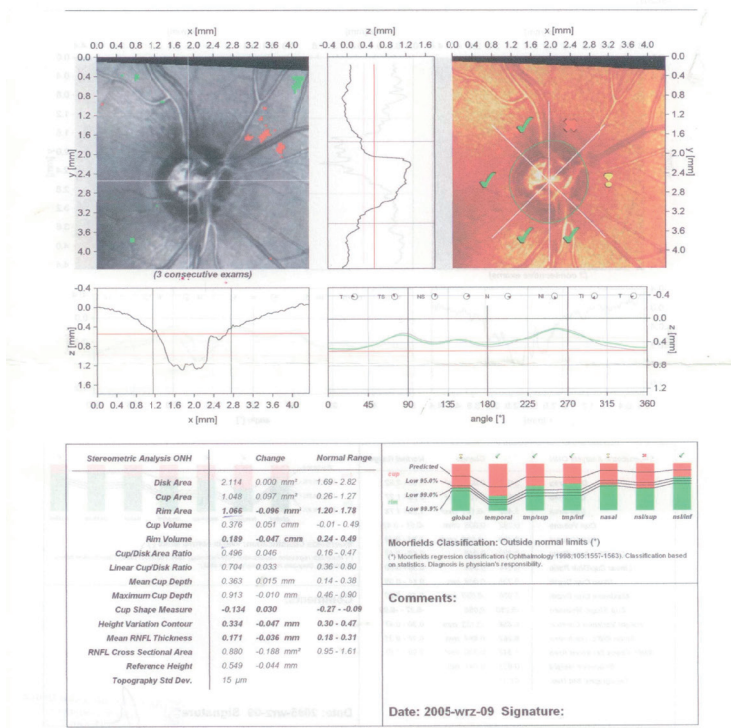
Efficient treatment of ocular surface disorders like blepharitis, meibomian gland dysfunction or superficial keratopathy may lead to an improvement in the IOP control (using Goldman aplanation tonometry) in patients with primary open angle glaucoma. Ocular surface disorders lead to reduced quality of life, reduced therapeutic compliance and increased risk of surgical failure. These results seem to be promising especially in group of patients, in which the success of filtering surgery may be compromised due to inflammatory histological changes in sclera or conjunctiva in case of chronic local therapy and ocular surface disorders.

## ★ REFERENCES ★

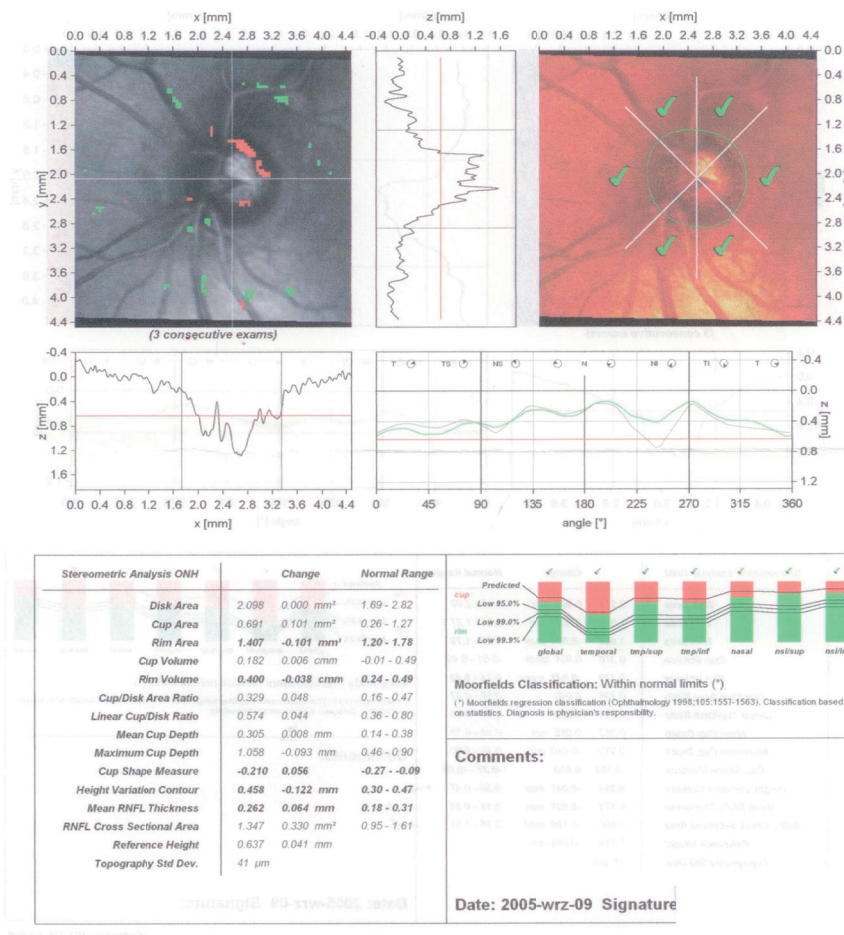
1. Mastropasqua L, Agnifili L; 'Conjunctival modifications induced by medical and surgical therapies in patients with glaucoma', *Curr Opin Pharmacol.* 2012 Nov 2. pii: S1471-4892(12)00198-1.
2. Batra R, Tailor R; 'Ocular Surface Disease Exacerbated Glaucoma: Optimizing the Ocular Surface Improves Intraocular Pressure Control.', *J Glaucoma.* 2012 Jul 23
3. Ouyang PB, Duan XC; 'Ocular surface injury resulted from topical anti-glaucoma medications: prevention and cure', *Zhonghua Yan Ke Za Zhi.* 2012 Jun;48(6):557-61.
4. Labbé A, Terry O; 'Tear film osmolarity in patients treated for glaucoma or ocular hypertension.', *Cornea.* 2012 Sep;31(9):994-9.



Picture 1



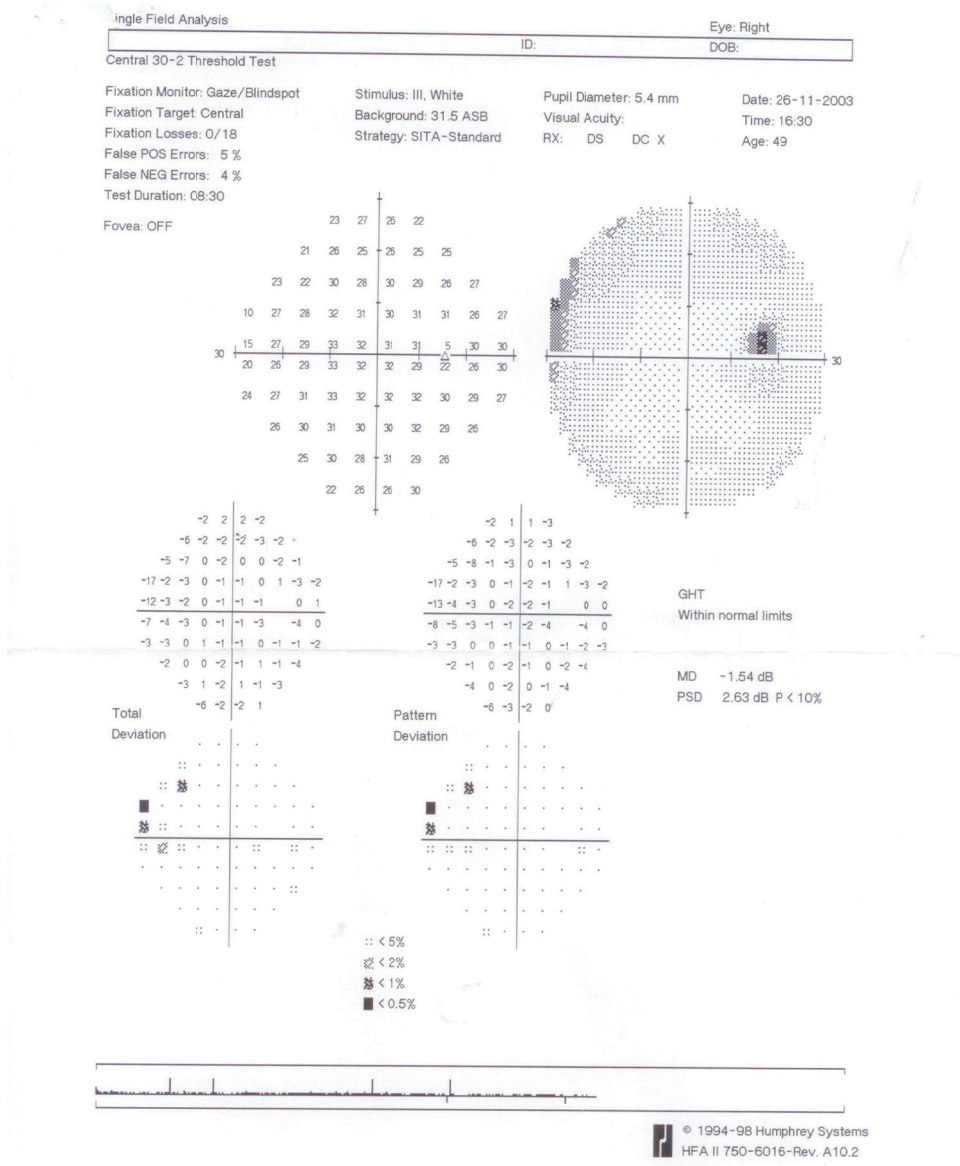
Picture 2



Picture 3

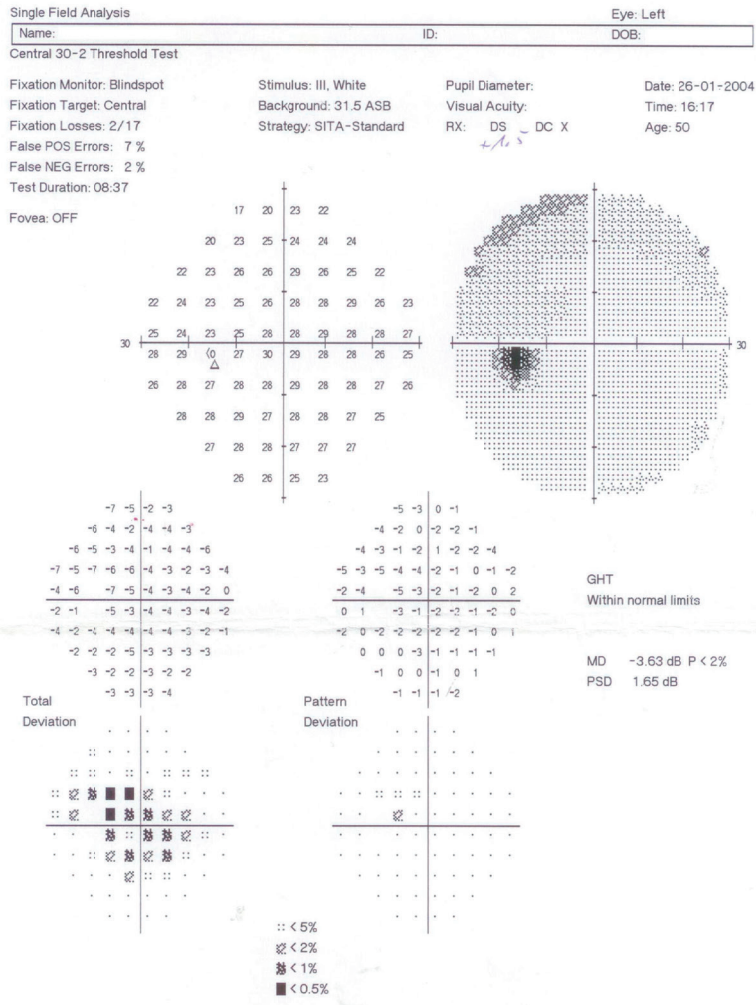
**THE INFLUENCE OF MEIBOMIAN GLAND DYSFUNCTION AND OCULAR SURFACE DISEASE ON INTRAOCULAR PRESSURE CONTROL IN A 83-YEAR PATIENT WITH PRIMARY OPEN ANGLE GLAUCOMA: A CASE REPORT**

.....



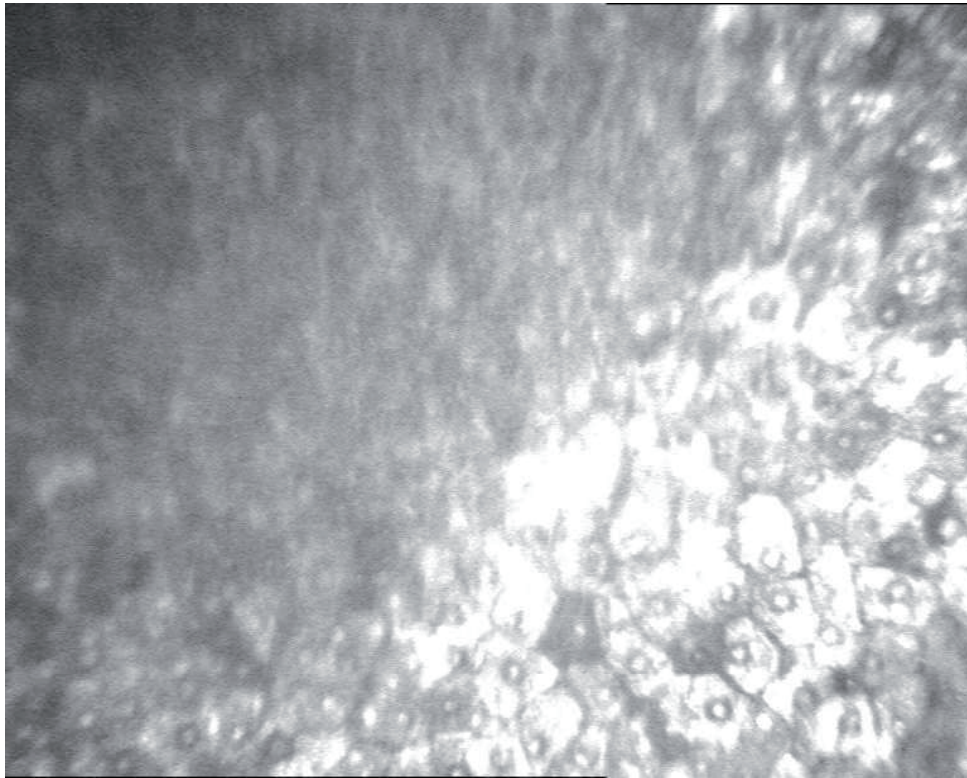
Picture 4



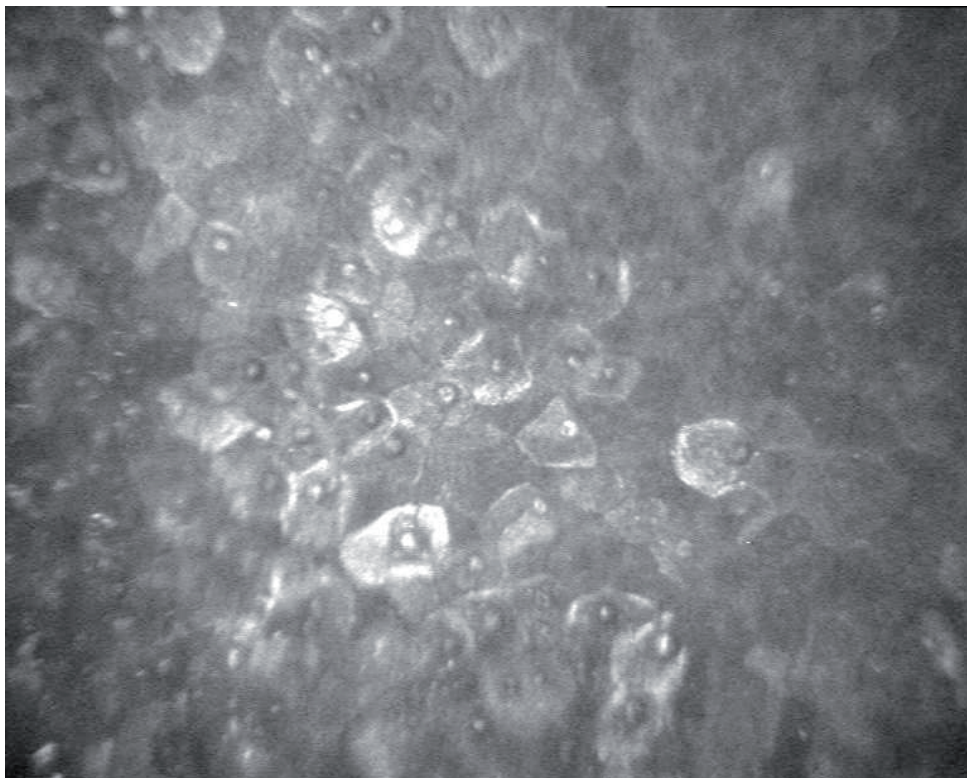


© 1994-2000 Humphrey Systems  
HFA II 720-5111-Rev C3/Rev C3

Picture 5



Picture 6



Picture 7

Mercedes RIVERA ZORI  
Hospital Universitario de Fuenlabrada – SPAIN



VITAMIN B12 DEFICIENCY OPTIC  
NEUROPATHY IN A PATIENT WITH  
PRIMARY OPEN ANGLE GLAUCOMA

★ INTRODUCTION ★

Nutritional optic neuropathies are uncommon and can be associated with gradual visual loss and optic atrophy. It can be difficult to diagnose them when they appear in patients with previous glaucomatous optic damage.

## ★ CASE PRESENTATION ★

Our patient is a 50 year-old man with high myopia and advanced chronic open-angle glaucoma in both eyes.

The initial examination was:

His vision (BCVA) in the right eye (OD) was 0.1 and in the left eye (OS) 0.9, initial intraocular pressure (IOP), before the start of treatment was 20/21 mmHg, with a standard biomicroscopy, gonioscopy grade III not pigmented open angle, and myopic fundus. Optic disc: in OD e/d 0.9 and in OS e/d 0.7. Visual field: OD not applicable, OS Humphry 10-2 est V.





Figure 1. OS initial visual field.

His medical history include Hepatitis virus C (HCV) genotype 1 diagnosed in 1997, treated with Interferon alfa-2b and Ribavirin in 2001. The treatment was suspended after 6 months after not obtaining virologic response with very poor tolerance.

Treatment with latanoprost 0.005% /24 hours and dorzolamide 2%/ 12 hours in both eye decreased IOP levels to 10/11 mm Hg. Visual field remained stable all over the follow up.



VITAMIN B12 DEFICIENCY OPTIC NEUROPATHY IN A PATIENT WITH PRIMARY OPEN ANGLE GLAUCOMA




Figure 2 OS visual field. Not possible in OD visual fields by Low vision. In 2011 visual acuity started to get worse.

The examination revealed :

BCVA : OD counting fingers OS 0.6

BMC : unaltered

IOP : 10/11 mmHg (latanoprost 0.005% /24 hours and dorzolamide 2% / 12 hours in both eyes)

Fundus : E/D 1/0.9, Macula unaltered. Visual field:




Figure 3 OS visual field.

We suspected this worsening was not due to glaucoma progression (bilateral BVA loss, VF not suggesting glaucoma progression, stable low IOP) so we decided to reevaluate the patient.

In a directed anamnesis the patient reports a deterioration of visual acuity coinciding to deterioration of liver function with cirrhosis and portal hypertension.

Despite the decision to start treatment with triple therapy (Biceprevir, Pegintron, Ribavirin) deterioration of liver function progressed. Increased transaminases and a deficiency of vitamin B12 were detected. The levels of folic acid, hematocrit and red cell indices remained normal.

Optic neuropathy due to a Vitamin B12 deficiency was suspected so we started treatment with vitamin B12 500 micrograms/8 hours, we tried oral treatments because atrophy there is no data.

One month after patient's examination was :

BCVA: OD 0.1 OS 0.7

BMC. Unaltered

IOP: 13/11mmHg (latanoprost 0.005%/24 hours and dorzolamide 2%/12 hours in both eyes).

Fundus: E/D 1/0.9, Macula unaltered. Visual Field:

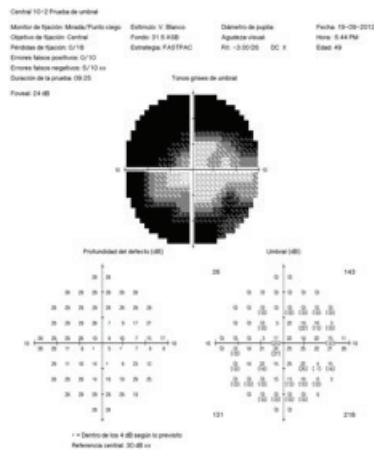


Figure 4. OD visual field. We were able to perform visual field in the right eye for visual acuity improved with treatment.

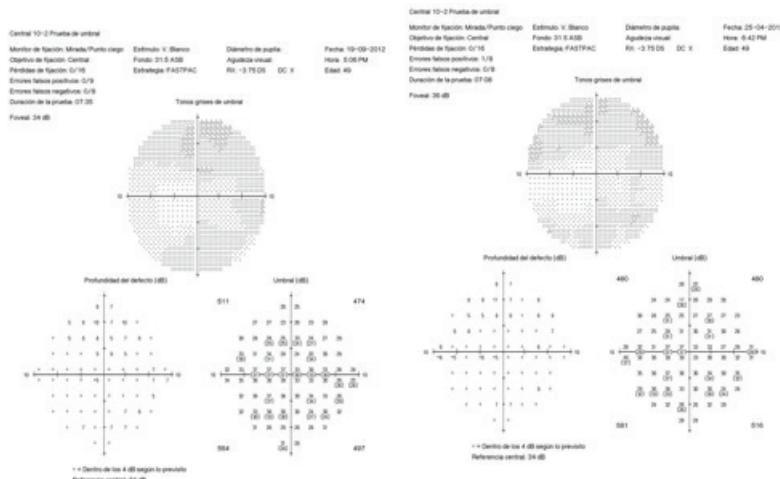


Figure 5.OS visual field. We observed an improvement in the visual field of the left eye treatment.

## ★ DISCUSSION ★

The role of nutritional factors on optic neuropathy is fully known since first description of the disease years ago.<sup>(1-3)</sup> Generally B12 deficiency is found associated to a megaloblastic anemia, but optic neuropathy and neurological manifestation may occur in patients with a normal hematocrit. In fact the frequency of vitamin B12 deficiency without anemia is surprisingly high, especially in the elderly. Folate supplements in food can mask hematologic effects of vitamin B12 deficiency<sup>(4)</sup>

When optic neuropathy occurs visual loss is usually bilateral and painless. The course is subacute or chronic, dyschromatopsia appears early, and afferent papillary defect is very uncommon.<sup>(5)</sup> Visual field defects are usually central so Humphrey 10-2 visual field test must be performed to examine central 10°.

In the optical coherence tomography we find a thinning if the retinal nerve fiber layer typically symmetrical and starting in temporal quadrants as in hereditary forms of optic neuropathies.<sup>(6-7)</sup>

The differential diagnose should be made with toxic optic neuropathy and with Leber's hereditary optic neuropathy (LHON). Compression of the optic chiasm can also result in progressive and painless visual loss. Extensive anamnesis and MRI should be performed in order to discard these conditions.

Physiopathology of the optic nerve damage appears to be an interruption of corrective mechanisms of oxidative stress in ganglion cells due to the lack of Vit B12<sup>(7-8)</sup>

Response to treatment with hydroxocobalamin is good in case optic atrophy it's not been totally established.<sup>(9)</sup>



## ★ CONCLUSION ★

In conclusion, the diagnosis of vitamin B12 deficiency neuropathy in this kind of patients is complex; the presence of open-angle glaucoma can camouflage other events in the visual field. Other frequent conditions such as high myopia invalidate optical coherence tomography. Exhaustive anamnesis is important to suspect the vitamin deficiency and we must remind that it can be found analytically without anemia. The rapid recognition of vitamin deficiency is very important to put substitutive therapy before reaching an irreversible optic atrophy.

## ★ REFERENCE ★

1. Stambolian D, Behrens M. Optic neuropathy associated with vitamin B12 deficiency. *Am J Ophthalmol.* 1977 Apr;83(4):465-8.
2. Areekul S, Roongpisuthipong C, Churdchu K, Thanomsak W. Optic neuropathy in a patient with vitamin B12 deficiency: a case report. *J Med Assoc Thai.* 1992 Dec;75(12):715-8.
3. Letona JM. Optic neuropathy in vitamin B12 deficiency. *Lancet.* 1998 Jul 11;352(9122):147.
4. de Silva P, Jayamanne G, Bolton R. Folic acid deficiency optic neuropathy: a case report. *J Med Case Rep.* 2008 Sep 10;2:299.
5. Chisholm IA. The dyschromatopsia of pernicious anaemia. *Mod Probl Ophthalmol.* 1972;11:130-5.
6. Pott JW, Wong KH. Leber's hereditary optic neuropathy and vitamin B12 deficiency. *Graefes Arch Clin Exp Ophthalmol.* 2006 Oct;244(10):1357-9. Epub 2006 Mar 8.
7. Orssaud C, Roche O, Duffier JL. Nutritional optic neuropathies. *J Neurol Sci* 2007;262:158-164
8. Sadun AA. Metabolic optic neuropathies. *Semin Ophthalmol.* 2002 Mar;17(1):29-32. Review.
9. Chu C, Scanlon P. Vitamin B12 deficiency optic neuropathy detected by asymptomatic screening. *BMJ Case Rep.* 2011 Apr 26;2011. doi:pii: bcr0220113823.10.1136/bcr.02.2011.3823.

António MENDES DE CARVALHO  
Centro Hospitalar de Coimbra, CHC, Quinta dos Vales,  
S. Martinho do Bispo, 3041-853 COIMBRA – **PORTUGAL**



# WHAT CAN THE GLAUCOMA DO!

## ★ INTRODUCTION ★

Characteristic : neuro-degenerative and progressive disease characterized by death of ganglion cells, optic nerve damage and visual field loss.

★ **CASE REPORT** ★

- ▶ ID : 38 years, black
- ▶ Risk factors : black race
- ▶ Clinic : progressive visual loss for 10 years OS and 3 years OD.
- ▶ Personal and family history : irrelevant
- ▶ Ophthalmological examination : BCVA OD : 8/10; OS : 3/10 IOP OD: 26 mmhg; OS: 38 mmhg Biomicroscopy OD/ OS : irrelevant Gonioscopy: grade III of Schaffer Pachymetry OD : 518  $\mu$ m; OS: 519  $\mu$ m Retinography OD: c/d: 0.8; OS: c/d: 0.9
- ▶ Exams : visual field OD; OS (not measurable); OCT optic nerve; Retinography
- ▶ Treatment : bimatoprost + timolol -1id OD/OS fixed Association at night. Visual field OD : island of central vision Excavation of the OD: 0.8, rule change ISNT, vessel change.Total excavation in OS, rule change ISNT, vessel change
- ▶ 1 month after medication : IOP OD: 10 mmhg; OS : 11 mmhg
- ▶ Objective : to decrease disease progression in OD
- ▶ Visual prognostic : reserved

## ★ DISCUSSION ★

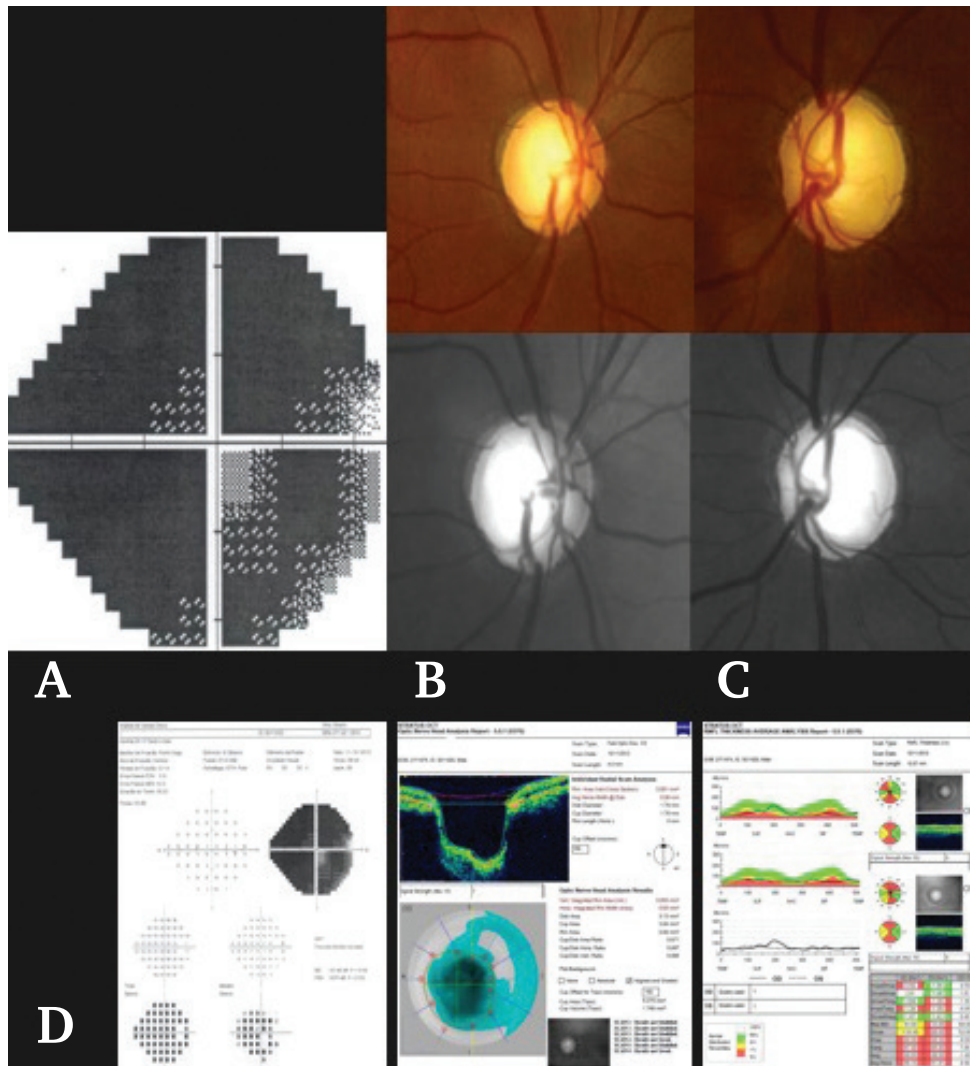
Progressive visual loss for several years. important early diagnosis to prevent vision loss.

## ★ CONCLUSION ★

Advanced primary open-angle glaucoma.  
Loss vision of OS and rapidly OD, secondary to increased intraocular pressure in a young man.

## ★ BIBLIOGRAPHY ★

Jack J.Kanski, 6ª edition -2009; American Academy of Ophthalmology - 2008; Will's Eyes Ophthalmic Manual Institute



- A) Visual field OD: high reliability. Loss: 0/13; false POS. errors: 0%, GHT: outside normal limits
- B) Excavation of the OD: 0.8, rule change ISNT, vessel change
- C) Total excavation in OS, rule change ISNT, vessel change
- D) Visual field OD: high reliability. Loss: 0/13; false POS. errors: 0%, GHT: outside normal limits

Neuro-ring retinal thickening  
and the RNFL OD and OS

STRATUS OCT OS  
Optic Nerve Head Analysis  
Evaluation of the diameter of the ON  
Loss of neuro-retinal ring

.....  
Andrea OLEÑIK

Fundación Jiménez Díaz.

Avenida Reyes Católicos 2, 28040, MADRID – SPAIN  
.....



.....

# NORMAL TENSION GLAUCOMA

.....

## ★ INTRODUCTION ★

Normal tension glaucoma is a form of open angle glaucoma is characterized by glaucomatous optic neuropathy in patients with intraocular pressure measurements consistently lower than 21 mmHg. Although once thought that the low-tension glaucoma is a rare disease, the Beaver Dam Eye Study reported that about a third of patients with glaucoma can be classified as such.<sup>1,2</sup>

The etiology is unclear although a recent study has demonstrated the close relationship with the nerve fiber layer and corneal hysteresis in glaucoma pathophysiology normotensional<sup>3</sup>. Other contributing factors may include vasospastic events, hypoperfusion, nocturnal hypotension, hypercoagulability and increased blood viscosity as well as genetic factors, has also been associated with headaches, Raynaud's phenomenon, diffuse cerebral ischemia and various autoimmune disorders.

## ★ CASE REPORT ★

73-year old woman studied by gradual visual loss bilaterally since 91 where the exploration had corrected visual acuity in the right eye of 0.4 and 0.3 in the left eye Snellen scale, intraocular pressure was 18/17 mm Hg, respectively, the daily graph of intraocular pressure is normal in both eyes, the poles above normal gonioscopy grade IV 360th in the fundus was observed in the right eye optic disc excavation 06 with impaired IS NOT rule digging in the left eye 06 with alteration of the rule is not (Figure 1), the visual field of both eyes arcuate scotoma and increased blind spot in the right eye, is clinical suspicion of a low-tension glaucoma at Carteolol Colirio pattern that clohidrato 2% in both eyes every 12 hours. At clinical examination is depression of 10 years of evolution, carotid doppler, normal brain MRI and other tests normal general.

In the successive revisions both visual acuity right eye and left eye 01 005 as the field of view of both showed clear worsening up to look barrel shotgun. In additional tests we find normal color test right eye and impaired deutan axis in the left eye, in the ENP increased latency in the left eye and the right eye within normal, so the diagnosis remains low-tension glaucoma and cataract surgery is decided and trabeculectomy in both eyes due to the rapidly changing market despite low eye strain.

After surgery, visual acuity is 01 in the right eye and left eye 005 with intraocular pressure of 11 mm of mercury 14μ pachymetry showed 528 and 531 microns, the visual field and showed no pattern variations of shotgun barrel maintained.

Revisions were made periodically and eye strain showed a reduction of 40% compared to baseline and remained over time (Figure 2 )

After 10 years, the patient reported some improvement in visual acuity in finding and exploring visual acuity with correction of 05 in the right eye and 04 in the left eye, intraocular tension of 11/10 mm of mercury, and inexplicably improved visual fields (Figure 3) and then have theoptical coherence tomography where there is a normal structure in both optic nerves (Figure 4). The pattern shows a slight erg conduction delay in both optic nerves. Suspected simulation but in all the years of revisions the patient daily life has remained within normal changes without commenting.



## ★ CONCLUSION ★

To determine if a patient has glaucoma normotensional should make a complete medical history. Specifically, the physician should ask if the patient has any systemic condition associated with NTG, evaluate the types of medications the patient and if there is a family history of glaucoma or NTG, ocular trauma or surgery, or if the patient has symptoms suggest that elevated IOP angle.

To exclude other conditions, your doctor should perform a thorough eye exam, you must include the BCVA, color vision, pupillary examination, tonometry, pachymetry, gonioscopy, standard automated perimetry and a detailed evaluation of the optic nerve and the layer nerve fibers. A map is important for blood pressure assessment of nocturnal hypotension and probable sleep study for apnea evaluation <sup>4</sup>. Investigations as the Doppler of the carotid arteries, laboratory testing of infectious or inflammatory diseases that cause optic neuropathy including PCR. Neuroimaging is necessary, especially if perimetry suggests that the damage is more posterior in the visual pathway, and if the optic nerve is more pale, or the patient is under 65 years old and shows rapid progression of nerve damage optical or damage marked asymmetry between the two optic nerves.

The photograph of the optic nerve head is important as it allows documenting the optic nerve for future comparisons.

In our case the optic nerve tomography has shown a normal image when the perimetry funduscopy were altered and thereby supporting a diagnostic change event without the presence of the CT is not possible.

## ★ DISCUSSION ★

The low-tension glaucoma remains a "mixed bag" where differential diagnoses as simulators where structural test helps us to differentiate.

CT techniques of retina and optic nerve experimentally have emerged in the 80s and reach a universe of clinical applications in the 90's has helped us to complete functional testing for a correct diagnosis and assessment of damage. <sup>5</sup>

It is important to a reduction of 20% from baseline intraocular pressure to prevent progression in glaucoma normotensional. <sup>6,7</sup>

## ★ REFERENCE ★

1. Klein, BE et al, Normotensional Glaucom *Oftalmología* 1992;. 99 (10) :1499-1504.
2. Potop V, Dumitrache M, Ciocalteu A. Normal tension glaucoma. *Oftalmologia*. 2010;54(2) :11-4.
3. Morita T, et al Corneal biomechanical properties in normal-tension glaucoma. *Acta Ophthalmol*. 2012 Feb;90(1):e48-53. doi: 10.1111/j.1755-3768.2011.02242.x. Epub 2011 Sep 13.
4. Gutiérrez-Díaz E, Pérez-Rico C, Díaz de Atauri MJ, Mencía-Gutiérrez E, Blanco R. Evaluation of the visual function in obstructive sleep apnea syndrome patients and normal-tension glaucoma by means of the multifocal visual evoked potentials. *Arch Clin Exp Ophthalmol*. 2012 Nov 6.
- 5 Kanamori A, Nakamura M, Escano MF, Seiya R, Maeda H, Negi A. Evaluation of the glaucomatous damage on retinal nerve fiber layer thickness measured by optical coherence tomography. *Am J Ophthalmol*. 2003; 135(4) :513-20.
6. Theodore Krupina, et al A Randomized Trial of Brimonidine Versus Timolol in Preserving Visual Function: Results From the Low-pressure Glaucoma Treatment Study *American Journal of Ophthalmology* Volume 151, Issue 4, April 2011, Pages 671-681
7. Aoyama A, Target intraocular pressure for stability of visual field loss progression in normal-tension glaucoma. *Jpn J Ophthalmol*. 2010 Mar;54(2):117-23. Epub 2010 Apr 18.

★ FIGURES ★

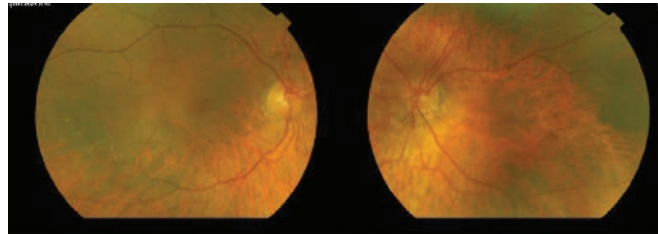


Figure 1

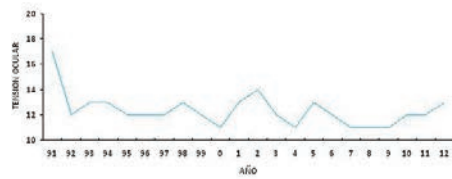


Figure 2

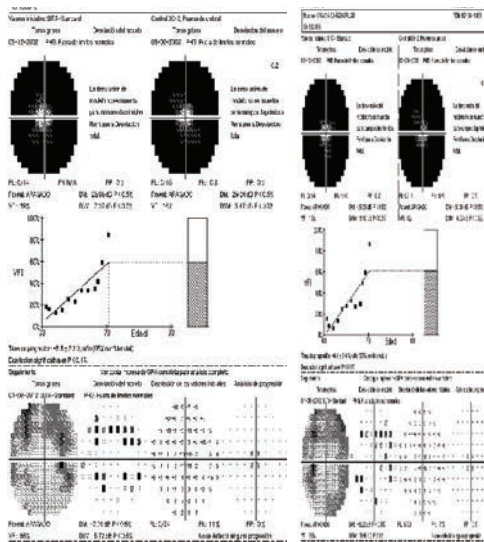


Figure3a

Figure3b

# NORMAL TENSION GLAUCOMA

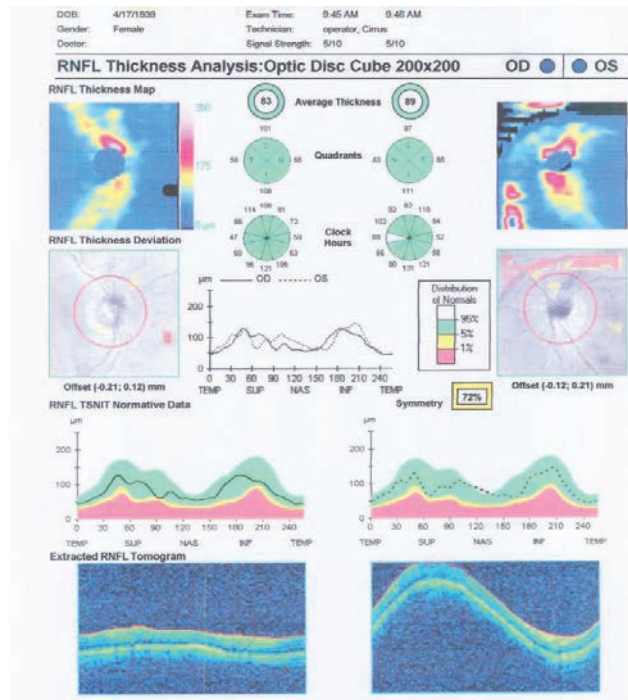


Figure 4



WWW.THEA-TROPHY.COM



THEA EUROPEAN CONTEST OF CLINICAL  
CASES IN PATHOLOGIES OF THE EYE



12, rue Louis Blériot Z.I. du Brézet 63017 Clermont-Ferrand CEDEX 2 FRANCE  
Tél. +33 4 73 98 14 36 • Fax. +33 4 73 98 14 38  
www.laboratoires-thea.com